

Bahar KILIÇARSLAN¹
Gülay ÖZBİLİM¹
Gökay ELPEK²
Şeyda KARAVELİ¹
Mine ÜNER²

A Patient With Three Simultaneously Occurring Malignancies

Departments of ¹Pathology, ²Obstetric and
Gynaecology, Faculty of Medicine,
Akdeniz University, Antalya-Turkey

Received: November 12, 1997

Key Words: Multiple Primary, Ovarian
Neoplasms, Synchronous

Synchronous primary malignancies of the female genital tract constitute 1.7% of all genital malignancies (1). The most common synchronous primary malignancies of the female genital tract are those of the ovary and endometrium (51.7%) (1). It is not usually possible to determine whether these tumours represent metastases from the endometrium or ovary or separate primary neoplasms. Rarely are the two neoplasms histologically disparate. The choice of treatment and the prognosis depend on whether these tumours represent primary tumours or metastases (2). The DNA ploidy level of the primary tumour is often maintained in the metastases and the probability that independent tumours will have the same DNA content is low.

This report describes a patient with three

simultaneous malignancies. These tumours were examined by flow cytometric DNA ploidy analysis to detect the presence of similar DNA stemlines which would make a metastatic process more likely (3).

A seventy-one-year-old postmenopausal woman was admitted to Akdeniz University, Faculty of Medicine, Department of Gynecology and Obstetrics with pelvic pain.

Upon gynecological examination, she was found to have left ovarian semisolid mass of approximately 10 cm. Ultrasonographic examination revealed a calculus in the gall bladder. No other abnormalities were detected. Two days after admission, a total abdominal hysterectomy, bilateral salpingoopherectomy, partial omentectomy and cholecystectomy were performed. Examination of the

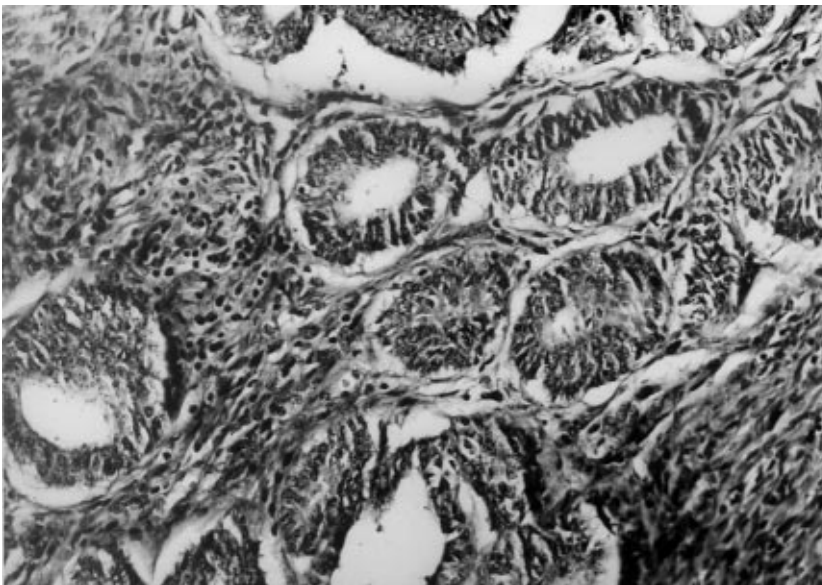


Figure 1. Endometrial carcinoma in the endometrial polyp. (H&E X20)

surgical specimen from the total abdominal hysterectomy revealed a broad-based polypoid mass measuring 2x1x1 cm in the uterine cavity. In the wall of the uterus, extensive adenomyosis was observed through the microscope. The endometrial glands in the endometrial polyp were composed of back-to-back glands, lined with large cells with abundant eosinophilic cytoplasm and nuclear atypia (Figure 1). Most of the tumour consisted of dense tubular formations and dilated glands. The stroma of the endometrial adenocarcinoma generally had a desmoplastic quality. These findings were determined as well-differentiated endometrial adenocarcinoma (endometrioid type). The ovary measured 4x3x1.5 cm. The tumour in the ovary was 4x3x0.8 cm. It had solid and cystic areas. The contents of the cysts were sero-hemorrhagic. Microscopic examination showed that the tumour had a glandular growth pattern with irregular budding and luminal reduplication. The glandular buds had smooth, rounded contours which were lined with a tall columnar pseudostratified or multilayered epithelium (Figure 2). There was cellular debris in these gland-like spaces. The solid areas showed complex glandular and microglandular patterns. Epithelial multilayering,

pleomorphism, mitotic activity and nuclear atypia were prominent. Necrosis and hemorrhage were obvious. This tumour was located in deep ovarian stroma. The tumour did not extend beyond the ovarian cortex. The ovarian tumour was diagnosed as a poorly differentiated primary ovarian carcinoma. The appearance of the ovarian neoplasm was similar to that of the endometrial malignancy. This lesion probably represented an ovarian primary endometrioid carcinoma, and for this reason from the uterus to the ovary could not be expected. The endometrial carcinoma in the endometrial polyp was restricted. No microscopic evidence of a tumour was observed in the other ovary, the tubes or omentum. In the gall bladder, a polypoid mass measuring 0.3 x 0.5 x 0.5 cm was observed on the surface of the mucosa. There is a cluster of atypical glands. Well-formed glands with wide lumina were lined with atypical cuboidal cells (Figure 3). Superficial muscular invasion was also observed. These findings supported the diagnosis of well-differentiated gall bladder adenocarcinoma.

Flow cytometry was performed on paraffin-embedded material. The DNA content was measured with an ICS-22 flow cytometer. The results of the ploidy analysis of the three tumours are summarized in Table 1 and illustrated in Figures 4 and 5.

After the operation, the patient's family initially refused to allow chemotherapy but, three months later, with their consent, a PAC chemotherapy (cis-platin, adriablastin, cyclophosphamide) program was begun. Three days after the first PAC chemotherapy session, severe neutropenia was detected. The neutropenic

Table 1. The results of flow cytometric ploidy analysis.

	aneuploid %	diploid %	DNA index
Endometrial carcinoma	56.8	43.2	1.3
Endometrioid carcinoma	15.4	84.6	1.6
Gall bladder carcinoma	14.8	85.2	1.5

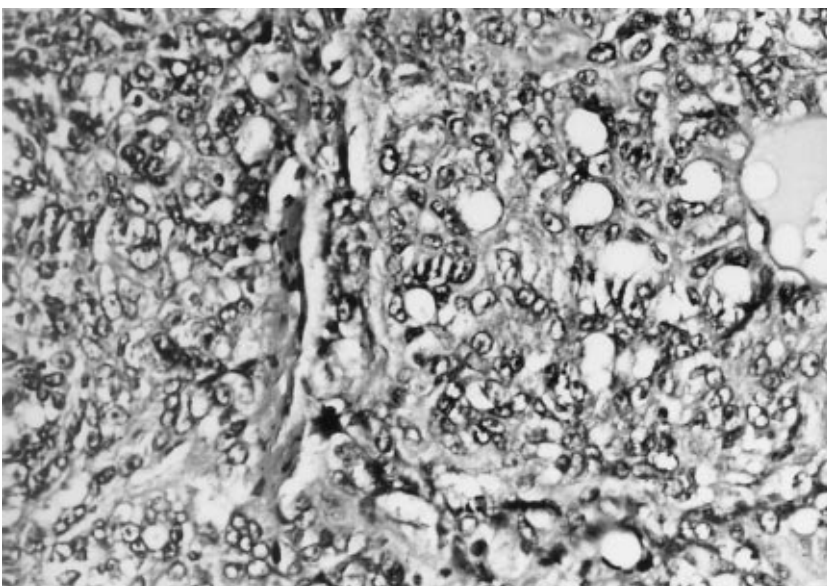


Figure 2. Endometrioid carcinoma. (H&E X40)

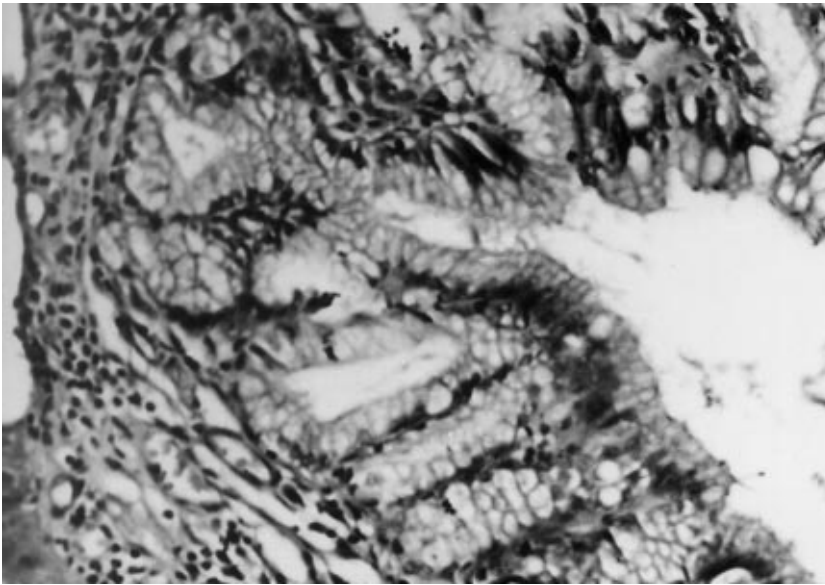


Figure 3. Gall bladder carcinoma in the polyp. (H&E X20)

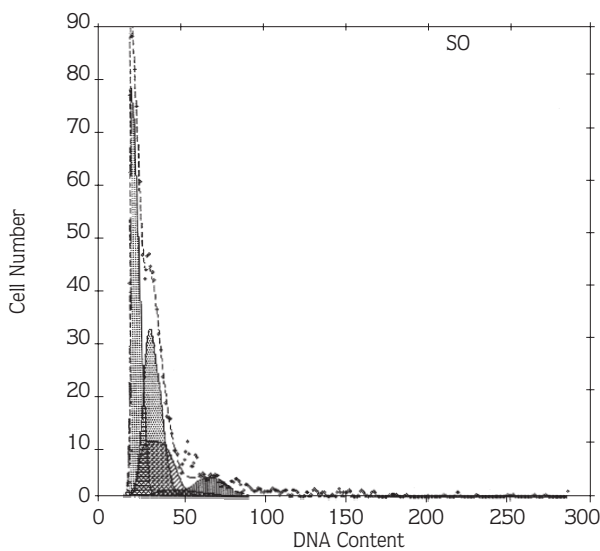


Figure 4. Corresponding histograms of DNA, endometrial carcinoma.

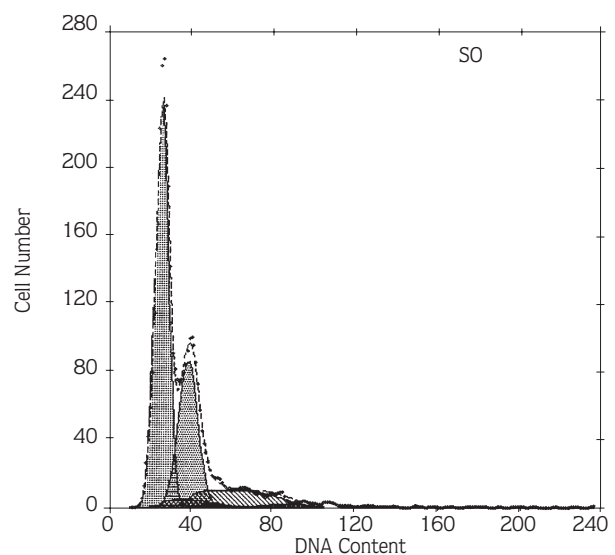


Figure 5. Corresponding histograms of DNA, gall bladder carcinoma.

condition was corrected with GM-CSF and, three weeks after she was discharged, she died of cardiopulmonary arrest.

Simultaneous occurrence of endometrial carcinoma and endometrioid carcinoma of the ovary with coexisting gall bladder carcinoma is rare.

Endometrioid carcinoma comprises 10%-25% of all primary ovarian carcinoma (4). The association of the endometrioid carcinoma of the ovary and endometrial adenocarcinoma is well recognized (5). The incidence of endometrial carcinoma in patients with endometrioid

ovarian carcinoma is 15.8% (6). Simultaneous appearance of these lesions raises the question of whether they can be treated only with total abdominal hysterectomy and bilateral salpingo-oophorectomy (TAH-BSO) (2). If the endometrial component of the simultaneous tumours is small and superficial, it is likely to be presented as synchronous neoplasms. However, deep invasive endometrial tumours raise the likelihood of ovarian metastasis from the endometrial carcinoma. Other criteria proposed include the size of the ovarian tumour, number of neoplastic foci, bilaterality, vascular invasion and tubal involvement (7).

In this case, the patient had two malignant tumours of the genital tract and gall bladder carcinoma. The DNA contents were measured by DNA flow cytometry establish whether the neoplasms represented a synchronous occurrence or metastatic spread. The flow cytometric DNA contents of the patient's tumours revealed that the samples contained both diploid and aneuploid populations.

According to previous reports, similar DNA values suggest separate origins for two tumours (8). The presence of different DNA contents is evidence for there being separate synchronous neoplasms for the tumors.

Symond et al. observed the following theoretically possible permutation of ploidy level in tumours at two separate sites: 1) identity as evidenced by similar DNA indices, 2) nonidentity as evidenced by differing DNA indices, 3) an indeterminate status when both indices are in diploidy modes (7).

The endometrial tumour displayed one aneuploid population with a DNA index (DI) of 1.3, whereas the endometrioid tumour had one aneuploid population (DI:

1.6) which differed from that of the endometrial lesion. The gall bladder carcinoma had a different DI from both of them.

In this case, a metastatic process can not be excluded completely because of the histologic similarity of the malignancies. Because of the total absence of tubal involvement, myometrial spread of the endometrial carcinoma and vascular or lymphatic invasion, a metastatic origin of one of the two tumours seems unlikely. The difference in the DI of the two lesions is an additional argument for independent origins.

The authors believe that DNA flow cytometry can be helpful in tracing the origin of distant metastases and discriminating between intragenital metastatic disease and multiple primary tumours. As the incidence of endometrial carcinoma is 15.8%, the application of DNA ploidy analysis may be of clinical value. We report this case because of the rare occurrence of simultaneous gall bladder carcinoma with two coexisting malignant tumours of the genital tract.

References

1. Ayhan A, Yağın OT, Tuncer ZS, Gurgan T, Küçükali T. Synchronous primary malignancies of the genital tract. *Eu. J. Obstet. Gynecol. Reprod. Biol.* 45(1): 63-6, 1992.
2. Eifel P, Hendrickson M, Ross J, Ballon S, Martinez A, Kempson R. Simultaneous presentation of carcinoma involving the ovary and the uterine corpus. *Cancer* 50: 624-6, 1982.
3. Smit VTHBM, Cornelisse CJ, Jong D, Dijkshoorn NJ, Peters AAW, Fleuren GJ. Analysis of tumor heterogeneity in a patient with synchronously occurring female genital tract malignancies by DNA flow cytometry, DNA fingerprinting and immunohistochemistry. *Cancer* 62: 1146-52, 1988.
4. Kline RC, Wharton JT, Atkinson EN, Burke TW, Gershenson DM, Edward CL. Endometrioid carcinoma of the ovary. Retrospective review of 145 cases. *Gynecol. Oncol.* 39: 337-6, 1990.
5. Beattie GJ, Livingstone JR, Comblett MA, Smyth JF, McLaren KM. Mucinous endometrial carcinoma in a patient with previous ovarian endometrioid adenocarcinoma presenting some 18 years after initial bilateral ovariectomy: a case report. *Scott. Med. J.* 36(6): 181-2, 1991.
6. Liu MV, Chen CJ, Kan YY, Chao KC, Yuan CC, Ng HT. Simultaneous endometrioid carcinoma of the uterine corpus and ovary. *Chung Hua I Hsuen Tsa Chih (Taipei)* 44(1): 38-44, 1989.
7. Sydmonds DA, Johnson DP, Whelless CR. Feulgen cytometry in simultaneous endometrial and ovarian carcinoma. *Cancer* 61: 2511-16, 1988.
8. Schwartz D, Banner BF, Roseman DL, Coon JS. Origin of multiple 'primary' colon carcinomas. A retrospective flow cytometric study. *Cancer* 58: 2082-88, 1986.