

Öztürk ÖZDEMİR<sup>1</sup>  
E. Ferda PERÇİN<sup>1</sup>  
İlhan SEZGİN<sup>1</sup>

## Chromosome 2 fragility- 48, XXYY syndrome

<sup>1</sup>Department of Medical Biology and Genetics,  
Faculty of Medicine, Cumhuriyet University  
58140, Sivas-Turkey

Received: May 22, 1998

**Key Words:** case report, chromosome  
fragility, severe mental retardation, 48, XXYY  
karyotype

We report a case of double male syndrome, a type of Klinefelter syndrome with 48, XXYY chromosome. The case had been referred to our department because of severe mental retardation and behavioural and psychiatric problems. In the karyotype analysis, the chromosome constitution of that 16-year-old case was revealed as 48, XXYY, fra 2q (32.2–32.3). More than 70 patients with 48, XXYY chromosome constitution have been reported. The 48, XXYY syndrome was firstly called Klinefelter syndrome (1), then it was delineated by Borgaonkar et al. (1). Chromosomal fragility and other breakages are not generally considered part of the clinical spectrum. In order to confirm these characteristics, we report a boy with 48, XXYY chromosomal complement and chromosome 2 fragility.

A.T.E., a male aged 16, was investigated in our laboratory in November 1997 because of severe mental retardation and behavioural and psychiatric problems. Although there was no indication of parental consanguinity or genetic disease, the familial history revealed a lot of abortions and deaths in child hood (Fig. 1). His height (176 cm), weight (60 kg) and head circumferences (57 cm) were at the 75th, 50th, and 75th centiles for this age, respectively. A pear-shaped nose, dysplastic ear crus, high palate, bilateral simian line, clinodactyly of both fifth fingers and rocker-bottom feet were observed on physical examination. He also presented marked hypoplasia of the testicles and penis, and hypotrichosis and female type distribution of body hair were noted. No additional major abnormalities were

detected in a complete system examination except chronic obstructive bronchopulmonary disease. In addition on the routine laboratory tests, we analysed the following parameters; Testosterone plasma levels: 1.35 pg/ml (N: 3–12), FSH: 54.3 IU/L (N: 1–8) and LH: 20.9 IU/L (N: 0.6–12). Radiographs showed posterior archus defects on L5–S1 vertebrae. Scrotal ultrasonography revealed that the testicles were atrophic and scales; right: 25x8 mm, left: 23x7 mm. Chromosome analysis was performed on cultured lymphocytes from peripheral blood with conventional GTG (Fig. 2–2) and CBG banding techniques. All metaphase plates examined showed a 48, XXYY chromosomal constitution. After CBG banding double Y chromosomes were observed in a normal structure (Fig. 2–1 and 5). On the other hand, 18% of metaphases showed fragile chromosome 2 (Fig 2–3 and 4) and chromatide type breakage was detected in 9% of metaphases. After the detailed analysis of the fragile chromosome with GTG banding it was determined to be chromosome 2 and the karyotype was determined as: 48, XXYY, fra 2 q (32.2–32.3). The father of the proband could not be examined (Fig. 1) whereas no chromosomal abnormality or dysmorphic feature were detected in the mother. This chromosome abnormality is a variety of Klinefelter syndrome and some authors have called it double male syndrome. Taken together with previously reported cases, the pedigree analysis (Fig. 1) and these data support a single more acceptable hypothetical mechanism of sequential non-disjunction during either paternal or maternal gametogenesis as the cause of sex

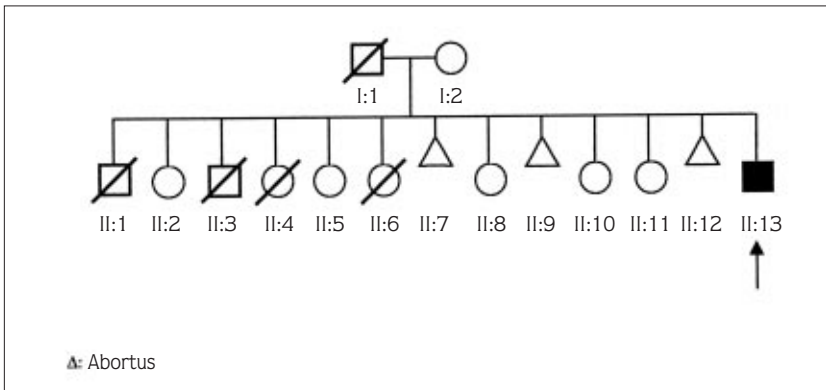


Figure 1. The pedigree analysis of our case. Arrow indicates proband.

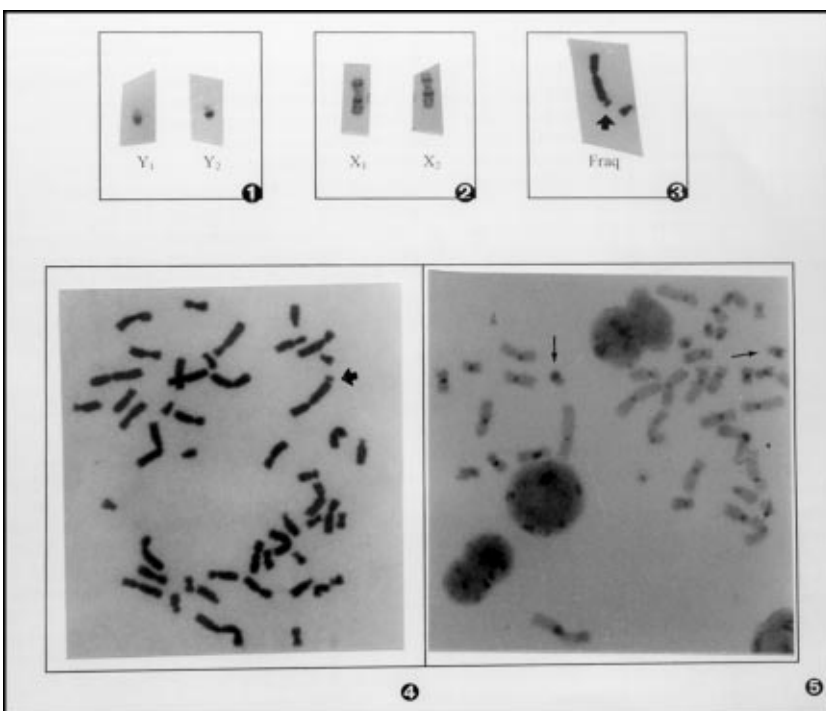


Figure 2. The 48, XXYY, fra 2q (32.2–32.3) karyotype in this case. 1 and 5: CBG banding technique shows double Y chromosomes 2: GTG banding technique shows double X chromosomes. 3 and 4: Methaphase plate in 48, XXYY structure and fragile chromosome.

chromosome occurs rarely (2) and there is no further information about them in the literature. At present, a total of 72 patients with 48, XXYY chromosomes have been reported. The 48, XXYY syndrome is characterised by markedly more frequent and severe behavioural and psychiatric problems than the 47, XXY syndrome (3). Arg75 Trp point mutation in a male with Klinefelter syndrome with 48, XXYY karyotype was reported by Silander et al. (4). Congenital heart disease with severe tetralogy of fallot in the 48, XXYY syndrome was reported by Meschede et al. (5). Nybero et al. determined a case with 48, XXYY syndrome by maternal alpha

fetoprotein screening and the pregnancy was terminated (6). By using PCR, the paternal origin of the extra X and Y chromosomes in polysomic patients of one 49, XXXXX, three 49, XXXXY, two 48, XXXY and one 48, XXYY syndrome were analysed (7). It was found that the four X chromosomes in 49, X polysomies were maternal and the extra X chromosomes in 48, X polysomies were paternal in origin. It was discussed that a single mechanism of sequential non-disjunction during either maternal or paternal gametogenesis is the cause of higher order sex chromosome polysomies. A case was reported of a patient gametogenesis is the cause of higher order

sex chromosome polysomies. A case was reported of a patient affected by mental retardation, dysarthria, bilateral testicular hypoplasia and extensive ulcers of the lower limbs. Karyotype analysis showed an inversion in chromosome 9 with 48, XXYY chromosomal complement in this patient (48, XXYY, inv (9) (q<sup>11</sup>q<sup>11</sup>), (8). On the other hand, the chromosome 2 fragility in the 48, XXYY syndrome is the first report in the literature. Severe mental retardation, which has already been described in the literature was also found in our patient. We also found severe behavioural and psychiatric problems and bilateral simian line, clinodactyly, hypoplasia of the testicles and penis on physical examination. A careful and detailed family health history is the basic prerequisite for any form of genetic counselling.

Mother and the other family members were suffering because of his mental, behavioural and psychiatric problems. In this case the detailed family health history (pedigree) was diagrammed (Fig. 1) and the proband and all other family members were informed and genetic counselling was given about the condition. Detailed analysis of the pedigree shows us there is a heavy chromosome abnormality or an accumulation of genetic imbalance in this family. Family members did not give us any likely cause to explain the deaths in this family. It was recommended that these group cases must be investigated for other possible chromosome abnormalities or rearrangements. In conclusion, chromosome analysis as well as sex–chromatin analysis is thus necessary in the investigation of male infertility.

## References

1. Borgaonkar DS, Mules E, Char F. Do 48, XXYY males have a characteristic phenotype? *Clin Genet* 1: 272–293, 1970.
2. Linden MG, Bender BG, Robinson A. Sex chromosome tetrasomy and pentasomy. *Pediatrics* 96(4): 672–682, 1995.
3. Fryns JP, Kleczkowska A, Kubien E, Van-den-Berohe H. XYY syndrome and other Y chromosome polysomies. Mental status and psychological functioning. *Genet Couns* 6(3): 197–206, 1995.
4. Silander K, Meretoja P, Pihko H, Juvonen V, Issakainen J, Aula P, Savontaus ML. Screening for connexin 32 mutations in Charcot–Marie–Tooth disease families with possible X–linked inheritance. *Hum Genet* 100(3–4): 391–397, 1997.
5. Meschede D, Nekarda T, Keçecioglu D, Hermann L, Vogt J, Miny P and Horst J. Congenital heart disease in the 48, XXYY syndrome. *Clin Genet* 48: 100–102, 1995.
6. Nybero RH, Karhu R, Karikoski R, Simola KD. The 48, XXYY syndrome: a case detected by maternal serum alpha–fetoprotein screening. *Prenat Diaon* 14(7): 644–645, 1994.
7. Leal CA, Belmont JW, Nachtman R, Cantu JM, Medina C. Parental origin of the extra chromosomes in polysomy X. *Hum Genet* (4): 423–426, 1994.
8. Grammatica P, Bottoni U, De–Sanctis S, Suilli N, Tonanzi T, Onorio AC, Porto GD. A male patient with 48, XXYY syndrome: importance of distinction from Klinefelter's syndrome. *Clin Genet* 38: 74–78, 1990.