

Comparison of Lyophilized Duramater and Autogenous Omental Wrappings of Grafting Sites in Experimentally Induced Facial Nerve Injury*

Part I Clinical and Gross Evaluations

Ömer BEŞALTI, Amet ÖZAK, F. Eser ÖZGENÇİL, Sibel BİLGİHAN, Faruk AKIN
Department of Surgery, Faculty of Veterinary Medicine, Ankara University, 06110 - Ankara - TURKEY

Received: 02.02.2001

Abstract: The clinical and gross evaluation of wrapping the facial nerve by a lyophilized duramater (LD) or an autogenous omental graft (AOG) for nerve regeneration, after experimentally induced facial paralysis which was created by neurectomies and repaired by autogenous sural nerve grafts in dogs, were undertaken. Twelve mongrel dogs of different ages, and sex were used in the study. An experimentally induced 1cm gap in the facial nerve was repaired by free cable nerves with an epiperineural suture. The dogs were allotted into 3 equal groups. In the control group, the repaired site was not wrapped by any material. However, the repaired site was wrapped by LD in the second group and AOG in the third group. All dogs were clinically observed for 6 months. Gross evaluation of the repaired site was performed at the end of the observation period. According to clinical and gross examinations, the AOG group was superior to the others, while the LD group was in a better condition than the control group. As a result, traumatic injuries of the facial nerve can be repaired by free cable grafts, and wrapping of the grafting site with a suitable material should be considered.

Key Words: Duramater, facial paralysis, graft, nerve regeneration, omentum, dog

Deneysel Fasial Sinir Yaralanmalarında Greft Uygulanan Bölgenin Liyofilize Duramater ve Otojen Omentum ile Sarılmasının Karşılaştırılması:

Birinci Bölüm: Klinik ve Makroskopik Değerlendirme

Özet: Bu çalışmada, fasial sinirin nörektomisi ile oluşturulan deneysel fasial paralizinin otojen sural sinir greftleri ile onarılmasından sonra fasial sinirin liyofilize duramater (LD) ve otojen omentum grefti (AOG) ile sarılmasının, sinir rejenerasyonuna olan etkisinin klinik ve makroskopik yönden değerlendirildi. Çalışma materyalini değişik yaş ve cinsiyette 12 adet melez köpek oluşturdu. Fasial sinirde deneysel olarak oluşturulan 1cm'lik gap, sural sinirden alınan serbest kablo greftleri ile epiperinöral dikilerek onarıldı. Köpekler 3 eşit gruba ayrıldı. Kontrol grubunda onarım hattı herhangi bir materyalle sarılmadı. İkinci ve üçüncü grupta onarım hattı sırasıyla LD ve AOG ile sarıldı. Tüm köpekler 6 ay süreyle klinik gözlem altında tutuldu. Gözlem süresinin sonunda onarım hattının makroskopik değerlendirilmesi yapıldı. Elde edilen klinik ve makroskopik incelemelere göre AOG ile sarılan grubun diğer iki gruba oranla daha üstün olduğu, LD ile sarılan grubun ise kontrol grubuna göre daha iyi durumda olduğu belirlendi. Sonuç olarak, fasial sinirin travmatik yaralanmalarının serbest kablo greftleri ile onarılabileceği ve greft hattının uygun bir materyalle sarılmasının yararlı olacağı kanaatine varıldı.

Anahtar Sözcükler: Duramater, fasial paralizisi, greft, sinir rejenerasyonu, omentum, köpek

Introduction

Peripheral nerve injuries are not rare in small animals. Nevertheless treatment, especially microsurgical repair, of them are not well documented (1,2). Facial nerve injury can be observed following trauma, resection of tumors, and the operative management of otitis media-interna (3). In humans, facial nerve injury is repaired by using direct

coaptation, a nerve autograft or suturing the facial nerve to another cranial nerve, whether through hypoglossal-facial, accessory-facial or phrenic-facial coaptation (4-7). Facial nerve grafting are preferred by many authors. However, many disadvantages have been described, including donor site morbidity, limited supplies of donor nerve and not entirely satisfactory results (4,5,8,9).

* This study was supported by TÜBİTAK as VHAG 1325 and A.Ü Research Foundation as 96.10.00.16.

Using an atraumatic surgical technique with microsurgical experience, in order to avoid further manipulation of the nerve tissue, can prevent the effects of intraneural and perineural fibrosis on nerve regeneration. Otherwise, extra and intraneural fibrosis may develop and cause the compression of neural tissues (9,10). Muscle, fat, fascia, plasma clot, autogenous vessel and fetal membrane taken from bovine fetus, plastic sheath, and biodegradable hydrolyzable materials are used for preventing the repaired site from fibrosis which may developed around the nerve (10-12). Exact coaptation of the fascicles or the nerve fibers during repair with nerve grafts is very difficult. Growing axons from the proximal part of the injured nerve have to pass through two barriers in the grafting site because of the presence of two suture lines (9). Thus, it can be proposed that the grafted site carries more risk of inhibiting regeneration than direct coaptation.

The omentum, which has many lymphatic vessels and fat tissue, is suitable to use in cases of ischemia in the brain and spinal cord and to prevent epidural fibrosis because of its adaptation to the application site, antimicrobial properties and its vascularization capability (13,14). LD is used successfully for abdominal hernias and in the repair of the thoracic wall and duramater defects as well as the reconstruction of the bladder and gall bladder (6,15).

To the author's knowledge, there are no studies on wrapping the grafted site of injured nerve with both materials. The purpose of the wrapping was to avoid the development of fibrosis between the nerve stumps and cable grafts. It also sought to make a conduit for regenerated axons that will not use grafts. An experimentally induced 1 cm nerve gap on the facial nerve was repaired with autogen nerve grafts, and an investigation of the effect of the AOG and LD wrapping on nerve regeneration was performed.

Materials and Methods

Twelve adult mongrel dogs of different sexes and ages (between 2 and 5 years old) were included in the study. The dogs were anesthetized, positioned in right lateral recumbency, and a para-auricular approach to the facial nerve was made. Dissections were performed to expose the facial nerve trunk just arising from stylomastoideus, between the proximal part of the parotid gland and the sternomastoid muscle. The nerve

trunk was freed from the stylomastoid foramen towards the furcation that splits into the cervical, dorsal buccal, ventral buccal and auriculopalpebral branches. Thus the freeing procedure allowed for the discrimination of tissue around the nerve trunk. A 1 cm gap was created via neurectomy of the facial nerve's main trunk. An autogenous sural nerve graft 1cm in length was harvested from the left side of the crural region and preserved in saline. Three cable grafts were coapted to the proximal and distal stump of the neurectomized facial nerve. All repairing procedures were performed with 10/0 propylene suture material using a 10X magnification operating microscope (TAKAGI-OM-5). Dogs were allotted to 3 groups. The control group's (n = 4): repaired nerve trunk was not wrapped with any material. LD group (n = 4): repaired nerve trunk was wrapped with the LD that was tube-shaped with a continuous suture, and stitched to proximal and distal parts of the neurectomized facial nerve epineurium. In the AOG group (n = 4): the AOG was taken by left side laparotomy and wrapped around the repaired site and stitched as done in the LD group.

Postoperative clinical findings were evaluated as asymmetric appearance, palpebral reflex, reaction to handling and pinching through facial expression, observation during feeding and drinking and appearance of the lower eyelid. Tears were evaluated quantitatively by the Schirmer tear test. The appearance of the repaired site was examined qualitatively using a 10X magnification in the operating microscope.

Results

Clinical Findings: The operation wounds healed without problems and sutures were taken off between the 10th and 12th days. The lip drooped and food, water or saliva were spilled out from the repaired side during the first week following the operations on all the dogs. While the dogs were trying to use their healthy sides, lagophthalmos, epiphora and absence of palpebral reflex were observed. During the first month clinical findings were the same in all groups.

On the 15th and 30th days, there was a greater quantity of tears on the affected side than the healthy side according to the Schirmer tear test, and in the third month the quantity was equal to the healthy side, especially in improved dogs. Clinical examinations of improved dogs revealed that the amount of tears was

within normal limits, and the eyelids seemed normal in the sixth month.

The palpebral reflex of the lower eyelids was absent and the upper eyelids were depressed in the first month. While touching the eyelids, in addition to palpebral reflex, the retraction of the eyeball to the caudal of the orbita and third eyelid protrusions were observed. In the fluorescein staining, corneal defects were not seen in any dogs. Narrowing of the palpebral fissure and atrophy of the eyelids were detected in two control dogs and one dog from both of the AOG and LD groups in the 3rd and 6th months.

In the control group, epiphora, lagophthalmos, atrophy of facial muscles, deviation of the muzzle and feeding problems did not improve until the 6th month in two dogs (Figures 1-3). An improvement in clinical findings was seen in the rest of the dogs. In the LD group, the symptoms related to the face and eyelids were increased and healing was not determined at the end of the 6th month in one dog. Gradual improvement was seen in 3 dogs (Figures 4-6) of the AOG group, but in one dog the improvement was not satisfactory.

Gross Evaluation: In the control group, the grafting site was slightly thicker than the distal and proximal part of the repaired site in a dog, and there was a nodule-like formation approximately 0.5 – 1 cm in diameter in the other three dogs (Figure 7). The grafted site was adhered firmly to the peripheral tissue in all dogs of the control

group. In the LD group, a thickening of the distal part of the grafted site was seen in one dog but the other three dogs had a regular structure for the repaired site (Figure 8). In the AOG group, adhesions of the grafted site to the peripheral tissue were less than others except in one case (Figure 9).

Discussion

There are a number of studies about microsurgical techniques for repairing peripheral nerve injuries, enhancement of regeneration as well as protection from complications, that may be encountered during and/or after operative management. These studies are generally on suture techniques, with some on growth factors and the repair of extensive nerve injuries (16-18). Although the peripheral nerves of limbs have been extensively studied both clinically and experimentally, there are a few studies about cranial nerve injury either in veterinary or human medicine. The sensibility of cranial nerves to trauma and the thinness of the epineurium when compared to peripheral spinal nerves, are important points that must be taken into account during nerve repair (2,5,10). The effects of wrapping the nerve by LD and AOG on nerve regeneration were evaluated in the study. The protection of the repaired nerve from fibrous tissue that develops around the repaired site and the prevention of the exiting of growing axons from the suture line and making a guide for them were aimed in



Figures 1- 3. The appearance of the unhealed control case at the 1st, 2nd and 6th month respectively. Notice the asymmetry of the face with the paralyzed left side drooping and being drawn to the right side by the unopposed facial tone on the normal side and in persistent clinical findings over time.



Figures 4-6. The appearance of the improved case of the AOG group at the 1st, 2nd and 6th month respectively. Notice healing.




Figure 7. Nodular structure of the grafted site in the control group.

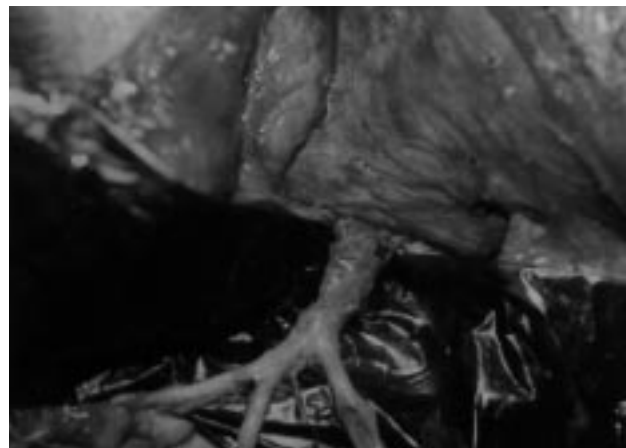


Figure 8. The well-shaped appearance of the grafted site in the LD group.

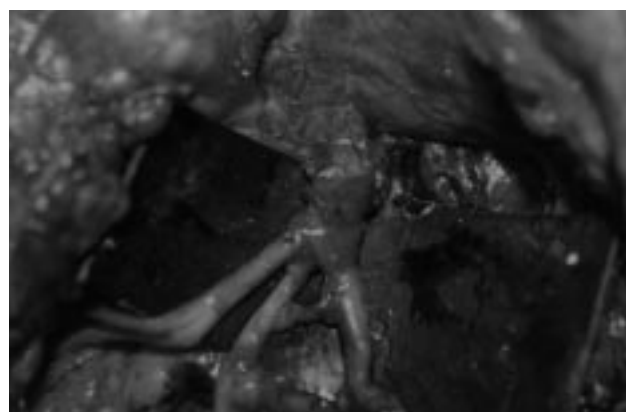


Figure 9. The irregular appearance of the grafted site in the AOG group.

the study by the use of 2 different materials. Due to the fact that microsurgical repair techniques of cranial nerves have been rarely studied, the facial nerve was selected as the subject of this study.

The development of fibrous tissue around the repaired nerve can block regeneration. This is confirmed by inflammatory reaction of epineural fibroblasts against collagen production and proliferation. Changes in the internal anatomic structure and improper inclining of regenerated axons occur due to the severity of the reaction. Muscle, fat, doffed plasma, fascia, autogenous vessel latex sheath, veins obtained from cattle fetuses, fetal membrane and biodegradable materials have been used to protect the repaired nerve from fibrosis developing around the repaired site of the nerve (10-12,18). In grafting, regenerated axons have to pass through two barriers because of the presence of distal and proximal suture lines on the grafting site. It was thought that regenerated axons exiting from the suture line would incline improperly and the invasion of fibrous tissue into the repaired area would have been greater than in direct nerve repair. There are no studies about the wrapping of an operation site by LD and AOG. When LD was kept in a saline solution, it could be manipulated into a tube-shape for wrapping the nerve properly. On the other hand, AOG could not be fitted into a tube-shape as well as LD because of folding.

Different suturing techniques have been described for peripheral nerve repair, such as epineural, perineural, interfascicular epiperineural, application of epineural splint, repair with fibrin glue, and laser. The superiority of one over the others is still controversial (19-21). Thinness of the epi- and perineurium of the cranial nerve make its repair more difficult than that of the spinal peripheral nerve (5). In the present study, three cable grafts coapted by epi-perineural suturing were performed without noticeable complications.

Although the sural nerve is frequently preferred, there are other donor sites discussed in the literatures (4,22,23). The major complications of harvesting the sural nerve are the desensitization of the operated area and wound dehiscence (2). In the present study, no problems in any of the dogs mentioned above were found. Trunk, cable and fascicular grafts were used as nerve grafts. It was difficult to find nerve grafts of appropriate diameters to repair nerve gaps. Equally, the nourishment of grafts was also an important problem in trunk grafting. The necessity of complex microsurgical

approaches and the possibility of neural trauma are the main disadvantages of harvesting fascicules (4,19). Three sural cable grafts were found to be suitable for repairing the gap in the facial nerve because of the equivalent diameter of the nerve trunk.

The disappearance of the palpebral reflex and the enlargement of palpebral fissure are seen in cats and dogs with unilateral facial paralysis. Although tears cannot disperse across the corneal surface adequately because of eyelid dysfunction, this situation is mitigated by the partial functioning of the upper and third eyelids and the retraction of the eyeball (3,24-26). Tear secretion does not decrease when parasympathetic branch of the facial nerve is not affected. It was thought that when the eyelid muscles which are innervated by facial nerve branches were dysfunctional due to facial paralysis, tears were dispersed throughout the corneal surface by the function of the n. oculomotorius, which innervates some of the levator muscles of the upper eyelid. The deterioration of tear drainage through the lacrimal puncta due to paralysis of the eyelids might be responsible for epiphora.

The muzzle deviates towards the healthy side because of muscle contraction. Deviation towards the paralyzed side is seen because of muscle atrophy at a late stage of paralysis (3,27). The asymmetric appearance of the face with muzzle deviation towards the healthy side of the dogs was seen at the early stage of severe paralysis in all groups. At a later period of facial paralysis, when atrophy had progressed, deviations to the paralytic side were determinable in the first group and there was also a considerable narrowing of the nostril on the paralyzed side, even though dyspnea was not present. The better condition of the AOG and LD groups was explained as a consequence of the formation of a barrier to fibrous tissue and also a tube that guided regenerating axons.

Neuroma and adhesions are not rare problems in the direct repair of nerves (5). However, these kinds of findings are not reported in nerve grafting. In our opinion, because of the two suture lines that act as a double barrier to regenerated axons, neuroma and adhesions might be more common in direct repair. This was considered to be the main purpose of the present study and the research performed sought a solution to these complications in nerve repair. In the control group, the repaired site of the nerve was adhered to peripheral tissues. In two dogs, the size of the neuroma was approximately 1 cm in diameter. In the LD group, the adhesion of the repaired nerve to peripheral tissues was

negligible and neuroma was seen in the distal part of the grafted side in one dog. In the AOG group, findings were more promising than in the others. It was detected that there was accommodation between clinical and macroscopical findings, despite neuroma formation, and fibrosis around the repaired nerve was less in the AOG group. In one dog from the AOG group, neuroma formation was seen definitively because of resuturing after the original suture material came off.

Approximately 1 cm long facial nerve gaps can be repaired with cable grafts, but wrapping with appropriate material should be considered. It was also observed that tubulization and inclined regenerated axons in the right direction were concluded. According to the results of the study, wrapping by AOG and LD yielded better results.

References

1. Raffae MR. *Peripheral Nerves*. Small Animal Surgery, Philadelphia, (Newton, H.C.E., Schwartz, C.D ed.) Lippincott Company; pp.492-499.1990.
2. Rodkey, W.G. *Peripheral Nerve Surgery*, Textbook of Small Animal Surgery Vol 1, 2nd Philadelphia. (Slatter, D.) WB Saunders Company; pp.1135-1141, 1993.
3. Kern, T.J and Erb, H.N. Facial Neuropathy in Dogs and Cats: 95 Cases (1975-1985). *JAVMA*, 1987. 191 (12): 1604-1609.
4. Laeken, N.V., Maktelow, R.T. Facial Paralysis: Principles of Treatment. Textbook of Maxillofacial and Reconstructive Surgery Vol 1, 581-595. 1992.
5. Lal, N.P., Joseph, T., Chandi, S.M. and Pant, B. Facial Neurography with Autologous Sural Nerve Graft Using the CO₂ Laser in a Primate Model. *Neurosurgery*, 1993. 32 (6): 1011 – 1014.
6. Özcan, O., Shenaq, S., Mirabi, B. and Spira, M. Nerve Regeneration in a Bony Bed: Vascularised Versus Nonvascularised Nerve Grafts. *Plastic and Reconstructive Surgery*, 1993. 91 (7): 1322-1330.
7. Thanos, P.K and Terzis, J.K. A Histomorphometric Analysis of the Cross -Facial Nerve Graft in the Treatment of Facial Paralysis. *Journal of Reconstructive Microsurgery*, 1996; 19 (6): 375 - 382.
8. Kitahara A. K, Nishimura Y, Shimizu Y, Endo K. Facial nerve repair accomplished by the interposition of a collagen nerve guide. *J. Neurosurgery*, 2000; 93. 113-120.
9. Terzis J.K. and Smith K.L. Repair and Grafting of the Peripheral Nerve. *Plastic Surgery, General Principles*, Vol. 1, W.B. Saunders Company; 631-697. 1990.
10. Van Beek, A.L. and Biffe P. Principles of Microsurgery. Textbook of Plastic Maxillofacial and Reconstructive Surgery, 1041-1054, 1992.
11. Chiu, D. T. W., Janecka, I., Krizek, T. J., Wolf, M. and Lovelace, R. E.: Autogenous Vein Graft as a Conduit for Nerve Regeneration. *Surgery*, 1982; 97 (2) : 226 - 233.
12. Hoerlein, B.F. *Canine Neurology Diagnosis and Treatment* W.B. Saunders Company, Philadelphia, 88 – 92. 1965.
13. Zubowicz, V.N., Jurkiewicz, M.J. Use of Omentum and Jejunum in Head and Neck Reconstruction. Textbook of Plastic Maxillofacial and Reconstructive Surgery. 1033-1039; 1992.
14. MacMillan, M. and Stauffer, E.S.: The Effect of Omental Pedicle Graft Transfer on Spinal Microcirculation and Laminectomy Membrane Formation. *Spine*. 1991; 12 (2): 176-180.
15. Philippe J. Quilici, J.O.: The Use of Dura Mater in the Surgical Repair Large Defect of the Abdominal Wall. *Surg. Gynecol & Obstetr.* 1985 ;161: 47-48.
16. Jacobsen, A. and Schrader, S.C.: Peripheral Nerve Injury Associated with Fracture or Fracture - Dislocation of the Pelvis in Dogs and Cats: 34 Cases (1978 -1982). *JAVMA*, 1987; 190 (5): 569 - 572.
17. Kanje, M., Lundborg, G. and Edstrom, A: A New Method for Studies of the Effects of Locally Applied Drugs on Peripheral Nerve Regeneration in Vivo, *Brain Research*. 1988; 439: 116-121.
18. Lipton, R., McCaffrey, T.V. and Ellis, J.: The Beneficial effect of Triamcinolone Acetonide on Nerve Repair with Autogenous Grafts. *Otolaryngology -Head and Neck Surgery*. 1986; 94 (3): 310-315.
19. Jabaley, M.F.: *Peripheral Nerve Repair*. Plastic Surgery, Philadelphia W.B. Saunders Company, 4757 – 4775. 1990.
20. Levinthal, R., Brown, W.J. and Rand, R.W.: Comparison of Fascicular, Interfascicular, and Epineural Suture Techniques in the Repair of Simple Nerve Lacerations. *J. Neurosurgery*, 1977; 47: 744 - 750.
21. Millesi, H.: *Microsurgical Repair of Peripheral Nerves*. Plastic Surgery Boston, 4th Ed. Little Brown, pp. 1053-1074. 1991.
22. Oliver, J.E. and Lorenz, M.D.: *Handbook of Veterinary Neurology* 2nd ed, Philadelphia, W.B. Saunders Company. 1993.
23. Waters, P.M. and Schwartz, J.T.: Posterior Interosseous Nerve: An Anatomic Study of Potential Nerve Grafts. *The Journal of Hand Surgery*, 1993; 18A, (4): 743 -745.
24. Chrisman, C.L.: *Problems in Small Animal Neurology*.; Philadelphia, Lea & Febiger, 206-208. 1982.
25. De Lahunta, A: *Veterinary Neuroanatomy and Clinical Neurology*. 2nd ed Philadelphia. W.B. Saunders Company, 1993.
26. Slatter, D.: *Fundamentals of Veterinary Ophthalmology* 2nd ed Philadelphia. W.B. Saunders Company, 151, 1990.
27. Wright J.A.: Ultrastructural Findings in Idiopathic Facial Paralysis in the Dog. *J. Comp. Path.* 1988; 98: 111-115.