

Lens Abnormalities in Slaughtered Holstein and Brown Swiss Beef Cattle in Konya*

Zeki OĞURTAN

Department of Surgery, Faculty of Veterinary Medicine, Selçuk University, Konya - TURKEY

Cengiz CEYLAN

Department of Surgery, Faculty of Veterinary Medicine, Selçuk University, Konya - TURKEY

İlhami ÇELİK

Department of Histology, Faculty of Veterinary Medicine, Selçuk University, Konya - TURKEY

Emrah SUR

Department of Histology, Faculty of Veterinary Medicine, Selçuk University, Konya - TURKEY

Received: 04.09.2001

Abstract: A total of 1000 beef cattle were examined after being slaughtered, of which 373 were Holstein and 627 were Brown Swiss. The high incidence of lens abnormalities was observed to be as follows: coloboma (20.4%), microphakia (6%) and cataract (3.9%) in Holsteins for a total incidence rate of 30.3%, and coloboma (5.6%), microphakia (2.6%) and cataract (4.2%) in Brown Swiss for a total incidence rate of 12.4 %. Holsteins were more frequently affected than Brown Swiss with coloboma and microphakia, but not with unilateral cataract formation. These animals were generally fed different ratios of beet pulp, hay, molasses and barley bought from a variety of sellers.

Key Words: Coloboma, microphakia, cataract, Holstein, Brown Swiss

Konya'da Kesilen Holstein ve Montofon Besi Sığırlarında Rastlanan Lens Anormallikleri

Özet: Toplam olarak 373 adedi Holştayn ve 627 adedi ise Montofon olmak üzere 1000 adet besi sığırı kesim sonrası muayene edildi. Holştayn besi sığırlarında toplam olarak %30.3 olarak bulunan lens anormallikleri insidansının %20.4'ü koloboma, %6'sı mikrofaki ve %3.9'u katarak olarak belirlenirken, Montofon besi sığırlarında toplam olarak %12.4 olarak bulunan lens anormallikleri insidansının %5.6'sı koloboma, %2.6'sı mikrofaki ve %4.2'si katarak olarak belirlendi. Holştayn besi sığırları unilateral katarak hariç Montofon besi sığırlarından daha fazla etkilendi. Bu hayvanların farklı satıcılardan alınan ve farklı oranlarda rasyona katılan şeker pancarı küspesi, saman, melas ve arpa ile beslendikleri belirlendi.

Anahtar Sözcükler: Koloboma, mikrofaki, katarak, Holştayn, Montofon

Introduction

Congenital anomalies occur in one or more systems characterised by structural and functional abnormalities of the related system. Congenital defects result from either genetic factors or environmental agents. Mutant genes or chromosomal disturbances cause hereditary defects (1). On the other hand, nutrition, toxic plants (1), mineral deficiencies of Cu (2) and Mn (3), ordinary use of drugs, and maternal diseases (1) act as environmental factors in the occurrence of congenital defects.

Central nervous system anomalies, e.g. spina bifida and meningocele (4), digestive system anomalies, e.g. atresia ani et recti and rectovaginal fistula (5,6), musculoskeletal system anomalies, e.g. arçure (6,7), bouleture (6,8), ectrodactyly and micromelia (9), and urogenital system anomalies e.g. aplasia penis and urethral dilatation (10), are the congenital defects most often encountered in Turkish livestock.

The congenital ocular anomalies that have been reported include cataract in camel, (11) hereditary

* This study was carried out at the University of Selçuk and in a local abattoir named Konet, Konya.

cataract and microphthalmia in miniature Schnauzer dogs (12-14), coloboma along with microphakia and spherophakia in horses (15) and ocular coloboma in Charolais cattle (16). These anomalies are not as frequently observed as other system anomalies. A literature survey revealed that amarois (17) and dermoid cyst (18,19) as ocular system anomalies frequently observed in Turkey.

In this study, we examined the lens abnormalities in beef cattle sacrificed in a slaughterhouse for the presence of coloboma, microphakia or cataract. To date, no information documenting the lens abnormalities found in beef cattle in Turkey has been recorded. The findings of this investigation increase our knowledge in this area.

Materials and Methods

This study was carried out in an abattoir in Konya, Turkey. The eyes of beef cattle were examined for the presence of lens abnormalities. A total of 1000 beef cattle were examined, of which 373 were Holsteins and 627 were Brown Swiss. The age of the animals was between 1 and 2 years. The criteria for identification of the cataract were based on the presence of hardness and opacification (loss of transparency) of the lens, along with its varying degrees of yellowish colour. Diagnosis of microphakia was made by comparing the size of the lens with a normal lens. The histological appearance of coloboma was demonstrated through routine preparation and staining with toluidine blue.

Results

Three abnormalities, coloboma, microphakia and cataract, were observed in these animals. The results are summarised in Table. Normal lens, microphakia and cataract are shown in Figure 1 and coloboma is shown in Figure 2.

A higher incidence of coloboma (20.4%) was observed in Holsteins compared to that of 5.6% in Brown Swiss. While the incidence of bilateral coloboma (10.7%) was higher than unilateral coloboma (9.7%) in Holsteins, it was lower (2% vs. 3.6%) in Brown Swiss. When Holsteins and Brown Swiss were compared, the incidence was 10.7% versus 2% in bilateral and 9.7% versus 3.6% in unilateral colobomas, respectively. Unilateral coloboma in the right lens was observed more frequently than in the left lens in both breeds. Involvement of the right and left lenses concerning unilateral coloboma was 6.1% and 3.6%, respectively in the Holstein breed. It was 2.2% and 1.4% in the right and left lenses, respectively, in Brown Swiss.

The incidence of microphakia was higher in Holsteins (6%) than that of 2.6% in Brown Swiss. Brown Swiss cattle were equally (1.3%) affected by microphakia with regard to bilateral and unilateral involvement. On the other hand, Holstein cattle were affected bilaterally (2.4%) and unilaterally (3.6%). The incidence of bilateral microphakia was higher in Holsteins (2.4%) than that of 1.3% in Brown Swiss. Unilateral involvement of microphakia was also higher in Holsteins (3.6%) than

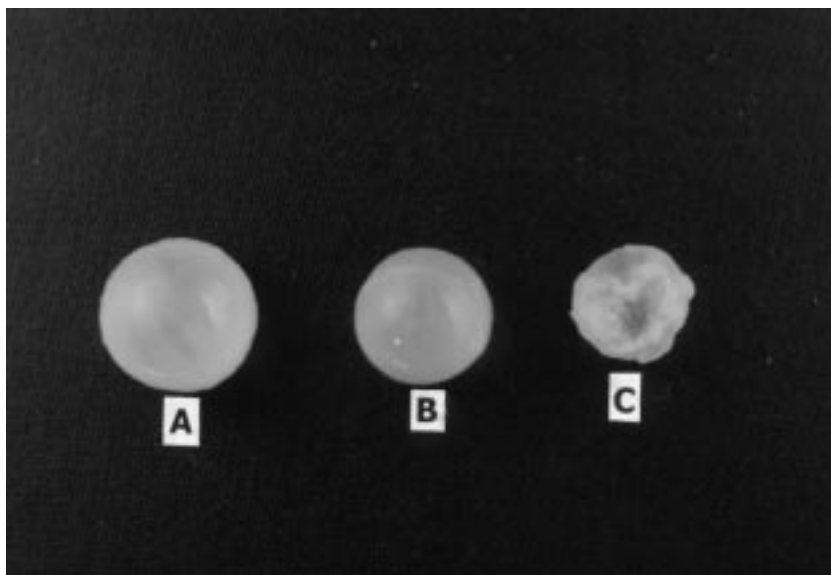


Figure 1. Photographic appearance of lenses A) normal, B) microphakia and C) cataract.

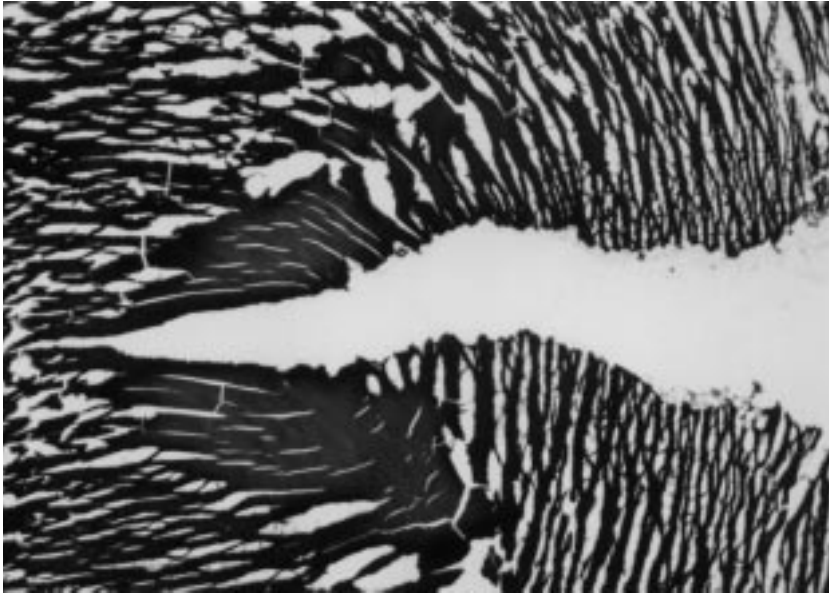


Figure 2. Longitudinal section of lens coloboma from the equator to the centre. Fissure, on the anterior pole, extends through the centre with loose arrangements of lens prisma, toluidine blue X 25.

Table 1. Lens abnormalities in Holstein and Brown Swiss beef cattle.

	Breed									
	Holstein					Brown Swiss				
	Numbers									
Coloboma	BL	R	UL	L	Total %	BL	R	UL	L	Total %
	35	20		12		13	14		9	
* Subtotal %		6.1		3.6	20.4		2.2		1.4	5.6
* Total%	10.7		9.7			2		3.6		
Microphakia	8	7		5		8	2		6	
*Subtotal %		2.1		1.5	6		0.3		1	2.6
*Total%	2.4		3.6			1.3		1.3		
Cataract	7	5		1		9	6		11	
* Subtotal %		1.5		0.3			1		1.8	4.2
* Total%	2.1		1.8		3.9	1.4		2.8		
* General Total%					30.3					12.4

*: Incidence, BL: Bilateral, UL: Unilateral

that of 1.3% in Brown Swiss. While microphakia was more frequently observed in the right lens (2.1%) compared to that of 1.5% in the left lens in Holsteins, it was observed more frequently in the left lens (1%) than in the right lens (0.3%) in Brown Swiss.

The incidence of cataract was 3.9% in Holstein cattle and 4.2% in Brown Swiss. Although the incidence of bilateral versus unilateral cataract was 2.1% and 1.8% in the Holstein breed, it was 1.4 and 2.8% in Brown Swiss, respectively. A higher incidence of bilateral cataract was

observed in the Holstein breed (2.1%) compared to that of 1.4% in Brown Swiss. Right lens involvement was higher than that of the left lens (1.5% versus 0.3%) in Holstein cattle. On the other hand, the left lens (1.8%) was more frequently affected than the right lens (1%) in Brown Swiss.

Discussion

Offspring with congenital anomalies die either in foetal life leading to abortion, or early after birth. Those which survive, depending on the severity of the defects, experience difficulties regarding the efficient use of food stuff and allowing themselves to be managed easily. Therefore, these animals cause economic losses.

A high incidence of congenital anomalies were observed by Oğurtan et al. to be 11.8% in calves, 36.4% in lambs and 39.2% in goat kids (20). Özyayın et al. (6) reported a 26.8% incidence of congenital anomalies in calves.

In our study, the high incidence of lens abnormalities was observed to be coloboma (20.4%), microphakia (6%) and cataract (3.9%) in Holsteins with a total incidence of 30.3%, and 5.6% of coloboma, 2.6% of microphakia and 4.2% of cataract in Brown Swiss with a total incidence of 12.4%. The holstein breed was more frequently affected than Brown Swiss cattle with coloboma and microphakia but not with unilateral cataract formation. These animals were generally fed different ratios of beet pulp, hay, molasses and barley bought from a variety of sellers.

Ocular coloboma was inherited as an autosomal dominant gene in Charolais cattle (16). No genetic or environmental cause was identified for coloboma in

horses (15). Microphthalmia and cataract were reported in Akita (20) and miniature Schnauzer dogs (13,14) and were inherited as an autosomal recessive trait in the latter (13).

A cataract is either congenitally inherited or noninherited and also develops after birth and later in aged animals as a senile cataract (21). Since the beef cattle in our study were slaughtered when they were 1 or 2 years old, the development of a cataract could not be classified as congenital or developmental. On the other hand, coloboma and microphakia are considered to develop only congenitally (21), indicating that in our survey coloboma and microphakia also developed congenitally. No dairy cattle were evaluated in our study. Therefore, it would be interesting to determine whether these types of abnormalities also occur in females.

It was reported that lens proteins such as alpha, beta and gamma crystallins have a structural and physiologic role in maintaining the transparency of the lens (14). The absence or alteration of these proteins could cause genetic defects leading to a cataract. Although these types of alterations may have affected defect formation related to feeding in beef cattle, the exact cause could not be determined in our study.

A cataract causes visual impairment and blindness and adversely affects behaviour, performance and breeding value (13). Microphakia and coloboma also cause adverse effects when keeping in mind the related changes in lens status. These results indicate the importance of the anomalies from the standpoint of economic losses and animal welfare. The best way of eliminating these animals should be carried out through eradication programs identifying these animals and preventing them from being used in breeding.

References

1. Blowey, R.W., Weaver A.D.: Congenital disorders In: Diseases and disorders of cattle. Mosby-Wolfe, Wolfe Publishing Ltd., 7, 1997.
2. Woodbury, M.R., Feist, M.S., Clark, E.G., Haigh J.C.: Osteochondrosis and epiphyseal bone abnormalities associated with copper deficiency in bison calves. Can. Vet. J., 1999; 40: 878-880.
3. Hidiroglou, M., Ivan, M., Bryan, M.K., Ribble, C.S., Janzen, E.D., Proulx, J.G., Elliot J.I.: Assessment of the role of manganese in congenital joint laxity and dwarfism in calves. Ann. Rech. Vet., 1990; 21: 281-284.
4. Ertürk, E., Samsar, E.: Bir kuzuda doğmalık spina bifida ve meningocele. A.Ü. Vet. Fak. Derg., 1978; 28(2): 261-266.
5. Akın, F., Anteplioğlu, H., Güzel, N.: Kuzu ve buzağılarda gözlenen kongenital rectovaginal fistüller ve bunların sağaltım yolları. A. Ü. Vet. Fak. Derg., 1980; 26: 83-92.
6. Özyayın, İ., Kılıç, E., Okumuş, Z.: 1992-1993 yılları arasında Kafkas Üniversitesi Veteriner Fakültesi cerrahi kliniğine getirilen buzağılardaki doğmasal anomali olguları. Vet. Cerrahi Derg., 1995; 1: 22-25.

7. Akin, F., Samsar, E., Güzel, N., Şener, G.: Buzağı ve danalarda arçure-bouleture olayları ile bunların sağıtımları üzerinde denemeler. A. Ü. Vet. Fak. Derg., 1977; 23: 237-248.
8. Samsar, E., Akin, F., Ersümer, C.: Buzağılarda tendogen uletürlerin operatif sağıtımı. Vet. Hay./Tar. Orm., 1980; 4: 91-98.
9. Alkan, F., Tuzcu, M., Koç, Y., Oğurtan, Z.: Bir buzağıda ectrodactly ile birlikte şekillenmiş micromelia. Vet. Bil. Derg., 1997; 13: 129-131.
10. Akin, F., Samsar, E.: Kliniğimize getirilen evcil hayvanlarda gözlenen penis ve preputium anomalileri. A. Ü. Vet. Fak. Derg., 1978; 25: 280-292.
11. Moore, C.P., Shaner, J.B., Halenda, R.M., Rosenfeld, C.S., Suedmeyer, K.S.: Congenital ocular anomalies and ventricular septal defect in a dromedary camel (*Camelus Dromedarius*). J. Zoo Wildl. Med., 1999; 30: 423-430.
12. Shastry, B.S., Reddy, V.N.: Studies on congenital hereditary cataract and microphthalmia of the miniature schnauzer dog. Biochem. Biophys. Res. Commun., 1994; 203: 1663-1667.
13. Gelatt, K.N., Samuelson, D.A., Bauer, J.E., Das, N.D., Wolf, E.D., Barrie, K.P., Andresen, T.L.: Inheritance of congenital cataract and microphthalmia in the miniature schnauzer. Am. J. Vet. Res., 1983; 44: 1130-1132.
14. Zhang, R.L., Samuelson, D.A., Zhang, Z.G., Reddy, V.N., Shastry, B.S.: Analysis of eye lens-specific genes in congenital hereditary cataracts and microphthalmia of the miniature schnauzer dog. Invest. Ophthalmol. Vis. Sci., 1991; 32: 2662-2665.
15. Gerhards, H., Werry, H., Deegen, E. and Kostlin, R.G.: Two rare lens abnormalities in horses. Tierarztl. Prax., 1992; 20: 82-86.
16. Falco, M., Barnett, K.C.: The inheritance of ocular colobomata in Charolais cattle. Vet. Rec., 1978; 102: 102-104.
17. Antepioğlu, H., Samsar, E., Akin, F., Güzel, N., Tinar, N.: Siğirlerde görülen amaurosis olguları ve bunların sağıtımları üzerinde denemeler. A. Ü. Vet. Fak. Derg., 1977; 24: 223-232.
18. Akin, F., Samsar, E.: Corneanın kongenital anomalileri, Dermoid-Kyst Dermoid- Cornea Dermoidi. Göz Hastalıkları, Ankara, Medipres, 2001; 105-106.
19. Laratta, L.J., Riis, R.C., Kern, T.J., Koch, S.A.: Multiple congenital ocular defects in the Akita dog. Cornell Vet., 1985; 75: 381-392.
20. Oğurtan, Z., Alkan, F., Koç, Y.: Ruminantlarda kongenital anomaliler. Vet. Hek. Derg., 1997; 9: 24-28.
21. Peiffer, R.L., Bowman, G.: Lens. In: Textbook of Small Animal Surgery, WB Saunders Comp., 1985; 1537-1538.