

## Ligation of Prostate Vessels and Nerves to Induce Prostate Atrophy

Zafer OKUMUŞ

Department of Surgery, Faculty of Veterinary Medicine, Atatürk University, Erzurum - TURKEY

Gültekin ATALAN

Department of Surgery, Faculty of Veterinary Medicine, Kafkas University, Kars - TURKEY

Yavuz Selim SAĞLAM

Department of Pathology, Faculty of Veterinary Medicine, Atatürk University, Erzurum - TURKEY

Received: 05.11.2002

**Abstract:** The objectives of this experiment were to induce prostate atrophy by ligating prostate vessels and nerves and evaluate the histological changes in the prostates.

Animal material consisted of 10 normal (healthy) crossbred dogs. The branches of the prostate artery, prostate veins, prostate innervating nerves, and hypogastric and pelvic nerves were ligated and then cut for each of the dogs under general anesthesia. Three months after surgery, the dogs were euthanased by with an overdose of sodium pentobarbital. Prostate length, depth, width and weight were measured during surgery (induction) and after euthanasia. Two hemi-cross-sections of each prostate, the left and right mid portions, were taken for histological examination.

There were significant differences in prostate length and weight measured during surgery and after euthanasia. In the histopathological examination, there was a decrease in compound tubular alveolar glands for all dogs, whereas there was an increase in fibrous tissue formation throughout the prostates.

In conclusion, although there was a statistical decrease in the mean prostate length and weight measured during surgery and after euthanasia, this was considered to be negligible in clinical practice for reducing the size of an enlarged prostate.

**Key Words:** Prostate, atrophy, ligation, dog

### Prostat Atrofisi Oluşturmak Amacıyla Prostat Damar ve Sinirlerinin Ligasyonu

**Özet:** Bu çalışmanın amacı, prostat damar ve sinirlerini ligatüre ederek prostatın atrofi olup olmadığını araştırmak ve oluşan değişiklikleri histolojik bakıda incelemektir.

Hayvan materyali 10 normal sağlıklı melez köpekten oluştu. Prostat arter, venaları ve prostatı innerve eden sinirler olan hypogastrik ve pelvik sinirler genel anestezi altında ligatüre edilerek kesildi. Postoperatif 3 ay sonra her bir köpek fazla dozda sodium pentotal verilerek uyutuldu. Prostatın uzunluk (L), derinlik (D), genişlik (W) ve ağırlık birimleri operasyon sırası ve ötenazi sonrası ölçüldü. Histopatolojik muayeneler amacıyla prostatın sağ ve sol lobundan kesitler alınarak incelendi.

Operasyon sırası ve ötenazi sonrası ölçülen prostat boy ve ağırlığı arasında istatistiksel olarak önemli farklılıklar vardı. Histopatolojik olarak, prostat genelinde tüm olgular için fibröz doku artışı gözlenirken, tubulo alveolar glandda bir azalma mevcuttu.

Sonuç olarak, operasyon sırası ve ötenazi sonrası saptanan ortalama prostat uzunluk ve ağırlıkları arasında istatistiksel olarak belirgin bir azalma saptanmasına karşılık, bunun klinik pratikte büyümüş prostatları gözle görülecek derecede atrofiye dönüştürmek için yeterli olmayacağı kanaatine varıldı.

**Anahtar Sözcükler:** Prostat, atrofi, ligasyon, köpek

### Introduction

The prostate gland is the only accessory sex gland in the male dog and it is a bilobed organ with a median septum on the dorsal surface continuous with the fibrous

capsule (1). It is bounded cranially by the urinary bladder, ventrally by the floor of the pelvis and abdominal wall, and dorsally by the rectum, from which it is separated by 2 layers of folded peritoneum (2).

The blood supply of the gland is provided by branches of the prostatic artery that penetrate the prostatic capsule on the dorsolateral surface. Venous return is provided by the prostatic and urethral veins that connect to the internal iliac vein (2). This vessel can be seen readily when the adipose tissue overlying the prostate gland has been reflected and the gland has been rotated slightly (2).

The prostate gland is innervated by the hypogastric and pelvic nerves. The nerve supply to the prostate is closely parallel to the vasculature (1-3). The hypogastric nerve follows the artery of the ductus deferens to the prostate. The pelvic nerve follows the prostatic to the pelvic plexus before projecting fibers to the gland (4). Neurons from the hypogastric nerve, part of the sympathetic nervous system, stimulate the secretory epithelium, as well as the contractile smooth muscle (5). The pelvic nerve provides parasympathetic cholinergic innervation to the smooth muscle, with little influence on the secretory epithelium (5).

Prostate diseases including benign hyperplasia, bacterial prostatitis, cysts, abscesses and neoplasia are commonly diagnosed in older sexually intact male dogs (6). The prostate gland undergoes 3 distinct phases of activity during the life of a dog. In the young adult dog (1-5 years of age), there is a normal growth, in middle age (6-10 years of age), hyperplasia develops, and in old age, there is senile atrophy (7,8). Benign prostatic hyperplasia (BPH) is a common medical problem in old male dogs (9). The size of the prostate gland may increase up to 4 times its normal size in a hyperplastic prostate (9,10). The cause and pathogenesis of the disease are not fully elucidated, but hormonal factors are evidently involved (8,11).

Clinical signs for BPH usually involve constipation and tenesmus or mild hemorrhage urethral discharge (12). Treatment of dogs with BPH is aimed to reduce the size of the gland and eliminate clinical signs related to hyperplasia. These goals are accomplished by castration, which causes the prostate to decrease in size over 2 to 3 months (9). In some instances, however, the owner finds this to be an unacceptable solution. This has led researchers to come up with alternative approaches for the treatment of BPH, such as administration of estrogens (13), alpha-1 adrenoceptor antagonists (14), 5-alpha reductase agents (15,16), or synthetic steroids (17) and ligation of the prostate blood supply (18).

Estrogen administration reduces the size of the prostate temporarily but can lead to bone marrow suppression and squamous metaplasia of the prostate, causing ductal obstruction with retention cyst formation. Thus, its use is limited to valuable breeding dogs (12,13). Alpha-1 adrenoceptor antagonists (14) have been found to be useful in the treatment of urinary outlet obstruction due to benign prostate hypertrophy in humans (14) and dogs (19). These drugs are more important for humans than for dogs, because BPH does not usually cause outlet obstruction in dogs, but constipation (6,13). Synthetic steroids (17) and 5-Alpha reductase aromates (16) have also been reported to cause significant prostate atrophy in dogs by causing inhibition of both epithelial and stromal components. However, prostate enlargement may relapse later on following the cessation of those drugs (16,17). Ligation of the prostate blood supply (18) may not effectively reduce the size and weight of the prostate.

These treatment methods using drugs cause only temporarily prostate atrophy and further techniques are necessary to do this permanently. As described above, the prostate innervating nerves stimulate the prostate secretory epithelium, and the dysfunction of these nerves surgically may cause prostate atrophy permanently for dogs that do not respond to medical treatment.

Therefore, the current study was designed to induce prostate atrophy by ligating prostate vessels together with nerves. We then observed changes in the prostates histologically to reveal whether ligation has any effect on prostate atrophy.

## Materials and Methods

Animal material consisted of 10 crossbred dogs. Age of dogs varied from from 2 to 5 (mean 3.4 years) and body weight varied from 15 to 52 (mean 27 kg). The prostates of these dogs were revealed to be within the normal limits of the pelvic canal by rectal palpation.

### Surgery

Before anesthesia, the dogs were fasted overnight. The dogs were placed in dorsal recumbency, and then a ventral midline incision was performed. The skin incision was made approximately 3 cm posterior to the umbilicus, around the prepuce, to the pubic bone; the prepuce was reflected laterally. The abdominal cavity was entered

through the linea alba on the midline. Periprostatic fat was reflected dorsally to either side of the gland to expose the vasculature and nerve innervation on the dorsolateral surface of the gland. By rolling the isolated gland to one side, the bifurcation of the artery was seen. The prostatic vessels were then ligated doubly with nonabsorbable suture material (Figure 1). Care was taken to preserve the caudal artery as it coursed cranially to supply the trigone area of the urinary bladder. The hypogastric and pelvic nerves were then identified and cut. The maximal length and depth on the longitudinal plane and width on the transverse plane were measured using a hand calliper. Finally, the midline abdominal incision was then closed in a routine fashion. Daily intramuscular antibiotic was administered for 1 week. The dogs were kept in kennels for 3 months and any disease related to the urinary tract or other organs was monitored. No complications were encountered. Three months post-operation, the dogs were euthanased by an overdose of sodium pentobarbital (50 mg/kg, intravenously). Each of the prostate glands was removed and trimmed of surface fat, peritoneum and loose connective tissue. The physical dimensions of the glands were measured.

Prostate weight during surgery and after euthanasia was also detected using a formula reported previously by Atalan et al. (10),

Prostate weight (g):  $0.628 \times (\text{length} \times \text{width} \times \text{depth}) - 0.216$ .

### Histopathology

For histopathological examination, 2 hemi-cross-sections of each prostate, one from the left mid portion and another from the right mid portion, were obtained. These tissues were fixed in 10% neutral buffered formalin, embedded in paraffin, and then stained with hematoxylin. Tissues were evaluated under light microscope at 5, 10 and 40x magnification.

### Statistical Analyses

A paired-t test was employed to determine whether there were significant differences between prostate dimensions and weight measured during and after euthanasia using the Minitab computing system (Pennsylvania State University).

### Results

The length, depth and width of prostate measured during surgery ranged from 2.5 to 4 cm (mean 3.14), 1.8 to 2.8 cm (mean 2.38) and 2.2 to 4.2 cm (mean 2.93), respectively. Physical measurements taken after euthanasia ranged from 2.2 to 3.7 cm (mean 2.87) for length, 1.7 to 2.7 cm (mean 2.24) for depth and 2.1 to 4 cm (mean 2.77) for width. There was a significant

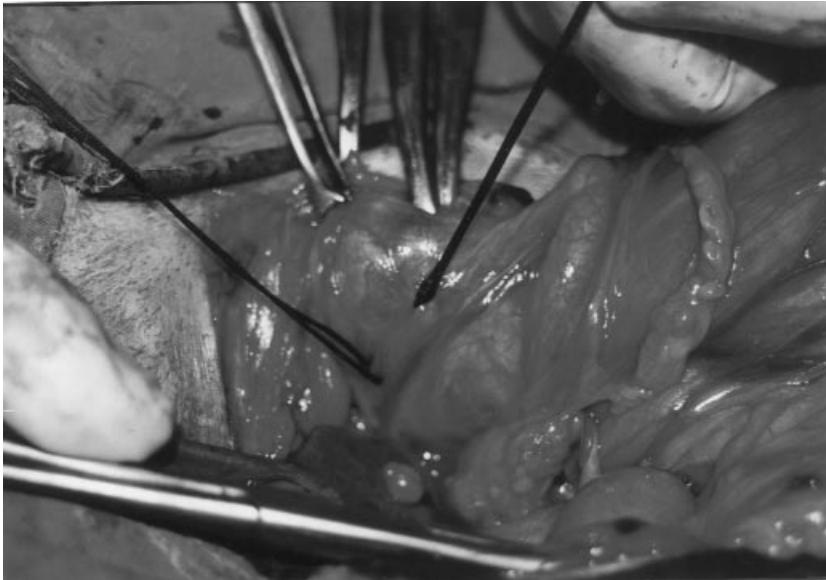


Figure 1. Ligation of prostatic vessels.

difference between the mean prostate length and weight measured during surgery and after euthanasia ( $P < 0.05$ ), with a mean difference of 0.27 cm for length and 2.52 g for weight. However, there were no differences in depth (0.14 cm) and width (0.16 cm) (Table).

The prostate weight measured during surgery ranged from 6.3 to 29 g with a mean of 13.84 g, whereas after euthanasia it ranged from 4.5 to 25 g (mean 11.32 g) (Table).

A small area of necrosis on the dorsal aspect of the prostate was detected macroscopically in 6 dogs, and these areas were only located superficially on the prostate capsule. Interestingly, an anastomosed branch of the prostate artery was detected in all dogs.

### Histopathological Examination

Under microscopic examinations, a generalized decrease in compound tubular alveolar glands was detected for all dogs, while an increase in fibrous tissue formation through the prostates was noted. Mononuclear inflammatory cells around the acini and necrotic cells in the tubular lumen were encountered in the prostates. Acines were observed to be pink when stained (Figure 2).

### Discussion

This study indicated that there was a significant decrease between prostate length and weight measured during surgery and after euthanasia. However, in clinical practice, such a decrease is not important enough to

magnify the atrophy process in cases of enlarged prostate. That is, the assurance of prostate atrophy may not be achieved by the ligation of prostate vessels and nerves. This finding was in agreement with the results of Kopp and Stockton (18) and Hodson (20) who only ligated the prostate vessels. Failure to induce prostate atrophy may be associated with the rapid formation of anastomosis following ligation. The mean estimated prostatic weight during surgery and after euthanasia was 13.84 and 11.32 g, respectively. This difference could be related to glandular tissue impairment through the prostate. Moreover, a general decrease in the glandular tubular compound for all dogs may be due to the lack of sympathetic innervation of the hypogastric and pelvic nerves. The experimental design in the present study was planned to run over a 3-month period. Significant prostate atrophy could occur over a more prolonged period, but this remains to be proven.

Various methods have been reported for reducing the prostate size in dogs including synthetic estrogens, hormone therapy and prostate-vessel ligation (6,8,9,12-20). Ligation of the prostate vessels alone was found to be ineffective for prostate atrophy (18,20). Hormone therapy was effective in reducing prostate size; however, it may cause bone marrow depression when used over the long term (8,12,13). Therefore, castration seems to be the method of choice for the treatment of prostate hyperplasia. However, some owners are opposed to castration, and therefore further research is required to develop alternative approaches for reducing prostate size.

Table. Average prostate diameters (cm) and weight (g) measured during surgery and after euthanasia for 10 dogs.

	During Surgery (mean ± sem)	After Euthanasia (mean ± sem)	Mean Difference (mean ± sem)
Length	3.14* ± 0.152	2.87* ± 0.151	0.27 ± 0.260
Depth	2.38# ± 0.097	2.24# ± 0.108	0.14 ± 0.120
Width	2.93# ± 0.181	2.77# ± 0.160	0.16 ± 0.049
Prostate Weight	13.84* ± 2.01	11.32* ± 1.78	2.52 ± 0.452

Values represent mean ± SEM (standard error mean)

Statistical analyses were performed by the comparison of prostate dimensions obtained during surgery and after euthanasia.

#: Not significant

\*:  $P < 0.05$  ( $n = 10$ ).

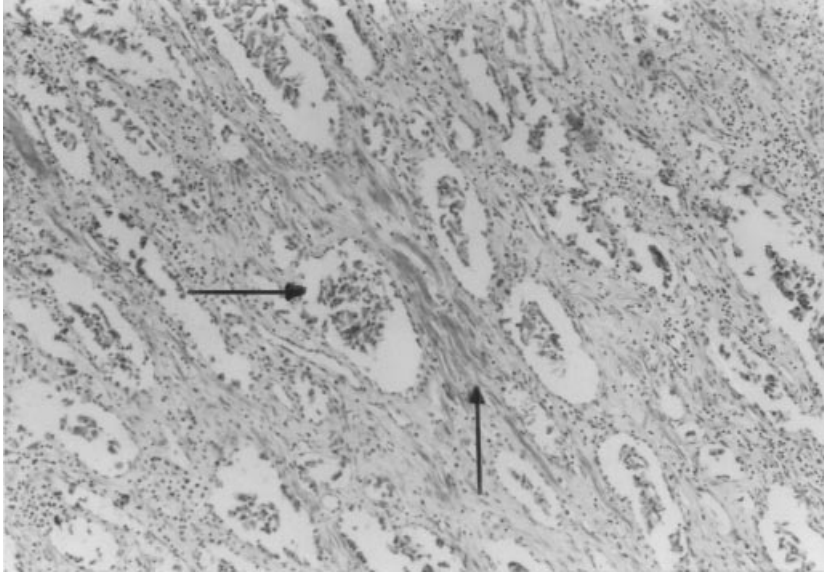


Figure 2 Obtained 3 months after ligation of the prostate vessel and nerves. A significant decrease in compound tubular alveolar glands is notable. Stroma is prominent, relatively fibroblastic and abundant (arrows).

In conclusion, the present study suggests that ligation of the prostate vessels and nerves is not the method of choice for inducing significant prostate atrophy in clinical practice, although significant differences were obtained between mean prostate length and weight. The failure

was attributed to the rapid formation of vascularization around the prostate. A general decrease in glandular tubular compound might be due to the absent nerve innervations responsible for glandular secretion.

## References

1. Neumann, F., Tunn, U., Funke, P.J.: Male accessory sex glands: experimental basis and animal models in prostatic tumour research. In: *Animal Models in Human Reproduction*. Serio, M., Marteni, L. (eds). New York, Raven Press. pp 249-282; 1980.
2. Christensen, G.C.: The urogenital apparatus. In: *Miller's Anatomy of the Dog*, 2nd edn. H.E. Evans, G.C. Christensen (eds). W.B. Saunders, Philadelphia. pp 558-566; 1979.
3. Bruchini, H., Schmidt, R.A.: Neurologic control of prostatic secretion in the dog. *Invest. Urol.*, 1978; 15: 288-290.
4. Evans, H.E., Christensen, G.C.: The prostate gland. In: *Miller's Anatomy of the Dog*. H.E. Evans, G.C. Christensen (eds). W.B. Saunders, Philadelphia. pp 565-566; 1979.
5. Smith, E.R.: The canine prostate gland and its secretions. *Adv. Sex Horm. Res.*, 1975; 1: 168-172.
6. Stone, E.A., Barsanti, J.A.: Prostatomegaly. In: *Urologic Surgery of the Dog & Cat*. Stone, E.A. (ed). Lea & Febiger, Philadelphia. 1992.
7. O'Shea, J.P.: Studies of canine prostate gland. Factors influencing its size and weight. *J. Comp. Pathol.*, 1962; 72: 321-331.
8. Berry, S.J., Strandberg, J.D., Saunders, W.J., Coffey, D.S.: Development of canine benign prostatic hyperplasia with age. *Prostate*, 1986; 9: 363-373.
9. Barsanti, J.A., Finco, D.: Canine prostatic disease. In: *Textbook of Veterinary Internal Medicine. (Diseases of the Dog and Cat)*. Barsanti, J.A. (ed.). Saunders Company, Philadelphia. pp 1859-1880; 1989.
10. Atalan, G., Holt, P.E., Barr, F.J., Brown, P.J.: Ultrasonographic estimation of prostatic size in canine cadavers. *Res. Vet. Sci.*, 1999; 67: 7-15.
11. Brendler, C.B., Berry, L.L., Ewing, A.R., McCullough, A.R., Cochran, R.C., Strandberg, J.D., Zirkin, B.R., Coffey, D.S., Wheaton, L.G., Hiller, M.L., Niswender, G.D., Scott, W.W., Walsh, P.C.: Spontaneous benign prostatic hyperplasia in the beagle: Age-associated changes in serum hormone levels, and the morphology and secretory function of the canine prostate. *J. Clin. Invest.*, 1983; 71: 1114-1123.
12. Dorfman, M., Barsanti, J.: Diseases of the canine prostate gland. *Comp. Contin. Educ. Pract. Vet.*, 1995; 17: 791-810.

13. Olson, P.N., Wrigley, R.H., Thrall, M.A., Husted, P.W.: Disorders of the canine prostate gland: Pathogenesis, diagnosis and medical therapy. *Comp. Contin. Educ. Pract. Vet.*, 1987; 9: 613-623.
14. Meyer, M.D., Altenbach, R.J., Bault, B.T., Basha, F.Z., Carroll, W.A., Kerwin, J.F., Lebold, S.A., Lee, E., Pratt, J.K., Sippy, K.B., Tietje, K., Wendt, M.D., Brune, M.E., Buckner, S.A., Hancock, A.A., Drizin, I.: Structure activity studies for a novel series of bicyclic substituted hexahydrobenz (e) isoindole alpha-1 adrenoceptor antagonists as potential agents for symptomatic treatment of benign prostatic hyperplasia. *J. Med. Chem.*, 2001; 44: 1971-1985.
15. Suzuki, T., Okazaki, H., Ono, Y., Kurokawa, K., Suzuki, T., Onuma, E., Takanashi, H., Mamiya, Y., Yamanaka, H.: Effects of dual inhibitor of 5-alpha reductase and aromatase on spontaneously developed canine prostatic hyperophy. *Prostate*, 1998; 37: 70-76.
16. Ito, K., Fukabori, Y., Shibata, Y., Suzuki, K., Mioda, M., Gotando, K., Honma, S., Yamanak, H.: Effects of a new steroidal aromatase inhibitor, TZA-2237, and/or chlormadinone acetate on hormone induced spontaneous canine benign prostatic hyperplasia. *Eur. J. Endocrinol.*, 2000; 143: 543-554.
17. Murakoshi, M., Tagawa, M., Ikeda, R.: Atrophic effects of antiandrogen, hormadione acetate (CMA) on dog prostate with spontaneous benign prostate hyperplasia. *J. Toxicol. Sci.*, 2000; 25: 143-150.
18. Kopp, H., Stockton, N.: Ligation of blood supply in the treatment of canine prostatic hyperplasia. *J. Am. Vet. Med. Assoc.*, 1960; 136: 327-330.
19. Suzuki, Y., Kanada, A., Okaya, Y., Aisaka, K.: Effects of JTH-601, a novel alpha (1)-adrenoceptor antagonist, on prostate function in dogs. *Eur. J. Pharmacol.*, 2000; 391: 123-130.
20. Hodson, N.: On the intrinsic blood supply to the prostate and pelvic urethra in the dog. *Res. Vet. Sci.*, 1968; 9: 274-278.