

Meningitis Associated with *Brucella abortus* in an Aborted Bovine Foetus

Cengiz ÇETİN

Department of Microbiology, Faculty of Veterinary Medicine, Uludağ University, 16059 Bursa - TURKEY

İ. Taci CANGÜL

Department of Pathology, Faculty of Veterinary Medicine, Uludağ University, 16059 Bursa - TURKEY

Mehmet AKAN

Department of Microbiology, Faculty of Veterinary Medicine, Ankara University, 06110 Ankara - TURKEY

Ebru ÖZEL

Department of Microbiology, Faculty of Veterinary Medicine, Uludağ University, 16059 Bursa - TURKEY

Ahmet AKKOÇ

Department of Pathology, Faculty of Veterinary Medicine, Uludağ University, 16059 Bursa - TURKEY

Received: 25.12.2002

Abstract: In this study, the brain and other organs from an aborted bovine foetus were examined histopathologically and microbiologically. In addition, a serum sample from the aborting cow was examined serologically. A granulomatous inflammation, characterised by the infiltration of lymphocytes, plasma cells with some neutrophils and macrophages was observed in the meninges of the brain, liver and kidney. *Brucella abortus* biovar 1 was isolated in pure culture from the brain and other organs. The serum sample was positive for brucellosis. These findings indicate that *Brucella abortus* is a pathogen capable of inducing meningitis in bovine foetuses.

Key Words: Brucellosis, bovine, foetus, abortion, meningitis

Bir Atık Sığır Fötusunda *Brucella abortus* ile İlişkili Meningitis

Özet: Bu çalışmada atık bir sığır fötusunun beyin ve diğer dokularının histopatolojik ve mikrobiyolojik incelemesi yapıldı. Ayrıca atık yapan inekten alınan serum örneği serolojik olarak incelendi. Beyin meninkslerinde, karaciğer ve böbrekte lenfosit, plazma hücresi ile az sayıda nötrofil ve makrofaj infiltrasyonu ile karakterize granümatöz yangı gözlemlendi. Beyin ve diğer organlardan saf kültür halinde *Brucella abortus* biovar 1 izole edildi. Serum örneği brusellozis yönünden pozitif bulundu. Bu bulgular *Brucella abortus*'un sığır fötüslerinde meningeze sebep olabilen bir patojen olduğunu göstermektedir.

Anahtar Sözcükler: Brusellozis, sığır, fötus, abort, meningitis

Introduction

Brucellosis is a disease characterised by abortion, a reduction in fertility and decreased milk production (1). Brucellosis in cattle is usually caused by biovars of *Brucella abortus*, with biovar 1 being the most frequently isolated type worldwide (2). In cattle, lesions of the female reproductive tract and of the placenta and foetus can lead to abortion with consequent severe economic loss (3). Variable lesions in the foetus include necrotising arteritis, especially of the pulmonary vessels, focal areas of necrosis and granulomas with giant cell formation in the lymph nodes, liver, spleen and kidney (1). There are very few reports on lesions in the brain in naturally

occurring *B. abortus* infection in bovine foetuses (4-6). This paper reports a case of granulomatous meningitis in the brain of an aborted bovine foetus naturally infected with *B. abortus*.

Case definition

One bovine foetus aborted at 5 months of gestation was submitted to the Faculty of Veterinary Medicine, University of Uludağ, Bursa, Turkey for postmortem examination. The aborting cow was reported to be vaccinated against infectious bovine rhinotracheitis and leptospirosis.

Necropsy was performed just after abortion and the organs were investigated macroscopically. Samples were taken from the lung, liver, spleen, kidney, prescapular lymph node and brain for histopathological examination, and smears of tissues were stained with Hemacolor (Merck, 1.11956/1.11957).

Samples were taken from the stomach, lung, liver, spleen, kidney and brain for microbiological examination and smears of foetal stomach content and tissues were stained with Gram and modified Ziehl-Neelsen methods. Samples of stomach content and tissues were inoculated onto Brucella Selective Medium (Brucella Medium Base [Oxoid CM 169] plus Brucella Selective Supplement [Oxoid SR 83]) and incubated at 37 °C for 72 h under microaerobic conditions. The isolates were identified on the basis of organism morphology; staining characteristics; colonial morphology; agglutination with monospecific sera; CO₂ requirement for growth; catalase, oxidase and urease activity; indole and hydrogen sulphide production; nitrate reduction tests; growth characteristics in the presence of basic fuchsin and thionin at final concentrations of 20 µg/ml; and lysis by phage Tbilisi (7). All samples were also cultured onto special media for other known causes of bovine abortion. In addition, a serum sample was taken from the cow 10 days after the abortion and examined by Rose Bengal plate test and serum agglutination test for brucellosis.

Results and Discussion

At necropsy, the foetus had oedema of the subcutis and skeletal muscles. In the abdominal cavity approximately 250 ml of serosanguineous fluid was observed; the abdominal organs were partly covered with fibrin. When the stomachs were opened yellowish-cream coloured fluid with fibrin clumps was found. In the thoracic cavity, 100 to 150 ml of fluid with similar characteristics was observed. The meninges were hyperaemic and were partly covered with a greyish-white mucous substance.

In the examination of smears stained with Hemacolor, mononuclear inflammatory cells, especially lymphocytes and plasma cells, and basophilic coccobacilli were seen in the brain, liver, kidney and lung.

In the histopathological examination of the tissues, granulomatous inflammation was observed in the meninges of the brain (Figure 1), liver and kidney. In the leptomeninges inflammatory cell infiltrations (mainly lymphocytes and plasma cells with some neutrophils and macrophages) were seen. The severity of the infiltration varied from area to area and degenerated cells were also observed. The inflammation in the liver and kidney was characterised by focal degeneration and necrosis of the normal architecture of the organ and infiltration of similar inflammatory cells, together with some

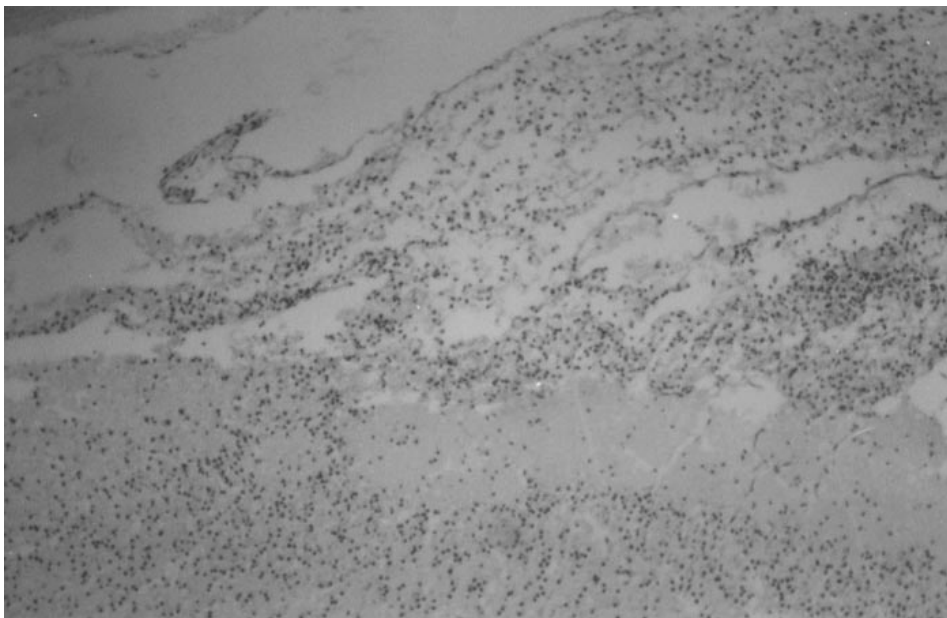


Figure 1. Dense cellular infiltrates in the leptomeninges of the brain of a bovine foetus (Haematoxylin–eosin stain, x110).

surrounding fibroblasts. Diffuse, moderate, non-purulent interstitial pneumonia was observed in the lung. These findings are in accordance with previous reports (4-6).

A microscopic examination of the smears prepared from the brain and other organs revealed large numbers of Gram negative coccobacilli in the Gram method and large aggregates of intracellular weakly acid-fast organisms of *Brucella* morphology in the modified Ziehl-Neelsen method (Figure 2). After incubation, pure cultures of convex colonies with round entire edges were

observed on the *Brucella* selective media. The strain isolated was identified as *B. abortus* biotype 1. The serum sample examined was positive by both tests.

In conclusion, histopathological findings in the meninges of the brain, isolation of *B. abortus* biotype 1 in pure culture from the brain and other samples of aborted foetus, negative findings for other known causes of bovine abortion and seropositivity for brucellosis of the aborting cow indicated that *B. abortus* biotype 1 is a pathogen that may cause meningitis in bovine foetuses.

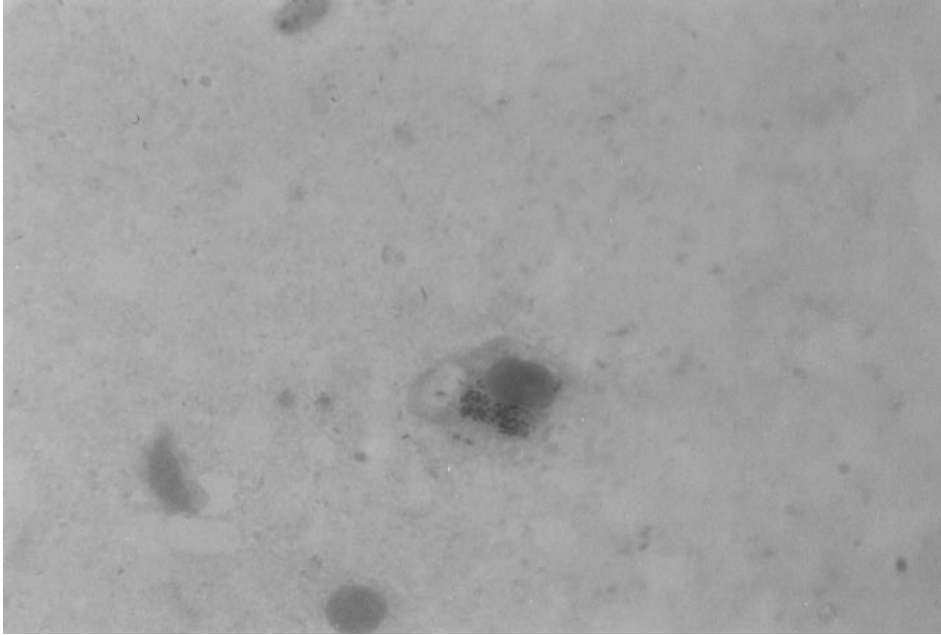


Figure 2. *Brucella abortus* in smear prepared from the brain of a bovine foetus (Modified Ziehl-Neelsen stain, x1100).

References

1. Kennedy, P.C., Miller, R.B.: The female genital system. Pathology of Domestic Animals. California, USA, Academic Press Inc., 396-402, 1993.
2. OIE: Bovine brucellosis. http://www.oie.int/norms/MANUAL/A_00044.htm, 2000.
3. Timoney, J.F., Gillespie, J.H., Scott, F.W., Barlough, J.E.: The genus *Brucella*. Hagan and Bruner's Microbiology and Infectious Diseases of Domestic Animals. New York, USA, Cornell University Press, 135-152, 1992.
4. Guarda, F.: Ulteriori ricerche sulla neuropatologia dei feti bovini abortiti (Further research on the neuropathology of aborted fetuses). Annali. Fac. Med. Vet. Torino. 1977; 24: 1-28.
5. Guarda, F.: Problemi attuali degli aborti bovini. Schweiz. Arch. Tierheilk. 1979; 121: 323-326.
6. Hong, C.B., Donahue, J.M., Giles, R.C., Poonacha, K.B., Tuttle, P.A., Cheville, N.F.: *Brucella abortus*-associated meningitis in aborted bovine foetuses. Vet. Pathol. 1991; 28: 492-496.
7. Quinn, P.J., Carter, M.E., Markey, B.K., Carter, G.R.: *Brucella* species. Clinical Veterinary Microbiology. London, UK, Wolfe Publishing, 261-267, 1994.