

The Results of Phacofragmentation and Aspiration Surgery for Cataract Extraction in Dogs

Fatma Eser ÖZGENÇİL

Department of Surgery, Faculty of Veterinary Medicine, Ankara University 06110, Dışkapı, Ankara - TURKEY

Received: 04.08.2003

Abstract: Cataract surgery was planned on 41 ERG positive eyes of 25 dogs of which 9 had unilateral and 16 had bilateral cataracts. Phacofragmentation and aspiration surgery was performed on 32 eyes of 20 dogs (and ECCE was performed on 4 eyes and ICCE was performed on 5 eyes of 5 dogs) of different breeds, sexes and ages. Vision restoration and complications were evaluated postoperatively in the short term (4 weeks). Mean age of the 20 dogs was 7.3 years. Stages of cataracts were classified as mature (n: 17), immature (n: 8) and intumescent (n: 7). While the mean phacoemulsification time was 1.50 min in immature and intumescent cases, it was 5.30 min in mature cases. The mean irrigation volume was 100 ml in intumescent and immature cases and 300 ml in mature cases. Functional vision was established in 22.2% of mature eyes and 77.8% of immature and intumescent eyes. The success rate of phacofragmentation surgery was significantly better in immature and intumescent eyes than in mature eyes ($P < 0.0001$). Mean age was 8.57 years in the dogs without functional vision and 5.88 years in those with functional vision after phacofragmentation surgery. Age of the dog at surgery was a significant factor in the restoration of vision ($P < 0.05$). In this study, the most important intraoperative complications (anterior capsular fibrosis, radial tear of anterior capsule and posterior capsular rupture-vitreous prolapsus) were observed in the mature and aged dogs. The most important postoperative complications in this study (uveitis and corneal thermal injury) were observed in mature and aged dogs. Vision was restored in eyes with immature and intumescent cataracts more successfully (11.7-fold) than in eyes with mature cataracts by phacofragmentation surgery.

Key Words: Phacofragmentation and aspiration, phacoemulsification, cataract, dog

Köpeklerde Kataraktın Sağaltımında Fakofragmentasyon ve Aspirasyon Cerrahisi Sonuçları

Özet: Dokuz unilateral, 16 bilateral kataraktlı değişik ırk, yaş ve cinsiyette toplam 25 köpeğin ERG'si pozitif olan 41 gözünde katarakt cerrahisi planlandı. Kataraktın operatif sağaltımında, 20 köpeğin 32 gözünde fakofragmentasyon ve aspirasyon cerrahisi (5 köpeğin 4 gözünde EKKE, 5 gözünde ise İKKE cerrahisi) gerçekleştirildi. Görüşün restorasyonu ile komplikasyonlar postoperatif kısa dönemde değerlendirildi (4 hafta). Yirmi köpeğin yaş ortalaması 7 yıl 3 aydı. Katarakt safhaları ise matür (n: 17), immatür (n: 8) ve intumesent (n: 7) olarak sınıflandırıldı. Ortalama fakoemülsifikasyon süresi, immatür ve intumesent olgularda 1,50 dakika iken, matür olgularda 5,30 dakika olarak bulundu. Ortalama irrigasyon volümü, intumesent ve immatür olgularda 100 ml iken matür olgularda 300 ml olarak bulundu. Postoperatif görüşün restorasyonu, matür olgularda % 22,2, intumesent ve immatür olgularda ise % 77,8 oranındaydı. Fakofragmentasyon cerrahisinin başarı oranı, immatür ve intumesent gözlerde matür gözlerle göre anlamlı olarak yüksek bulundu ($P < 0,0001$). Postoperatif olarak fonksiyonel görüşün sağlanamadığı gözlerde yaş ortalaması (yıl), 8,57 bulunurken görüşün sağlandığı gözlerde ise 5,88 bulundu. Cerrahi sırasında köpeklerin yaşı, görüş restorasyonunun sağlanmasında belirgin bir faktördü ($P < 0,05$). Bu çalışmada en önemli intraoperatif komplikasyonlar (anterior kapsüler fibrosis, anterior kapsülün radial yırtığı ve posterior kapsül rupturu - vitreus prolapsusu) ile en önemli postoperatif komplikasyonlar (uveitis ve korneal termal yanık) matür ve yaşlı olgularda gözlemlendi. Fakofragmentasyon cerrahisinden sonra görüşün restorasyonu açısından immatür ve intumesent dönem, matür dönemden 11,7 kat daha başarılı bulundu.

Anahtar Sözcükler: Fakofragmentasyon ve aspirasyon, fakoemülsifikasyon, katarakt, köpek

Introduction

Four techniques are used in the surgical treatment of cataracts in dogs: intracapsular cataract extraction (ICCE), extracapsular cataract extraction (ECCE), extracapsular phacofragmentation and intracapsular

phacofragmentation. Success rates in canine cataract surgery have increased markedly in the last 15 years, particularly as a result of the introduction of phacofragmentation techniques and reduction in the use of ECCE (1-4). In fact, the phacofragmentation and

aspiration technique is a type of ECCE for it removes the lens cortex and nucleus while leaving the posterior lens capsule intact. Phacofragmentation uses ultrasound to break up lens material (cortex and nucleus), which is then aspirated from the eye; the eye is kept inflated during the phacofragmentation. A small corneal incision is made, and a cystotome is used to tear and remove the anterior capsule (extracapsular phacofragmentation) or to make a small incision in the anterior capsule (intracapsular phacofragmentation). The ultrasound needle, which has also aspiration and irrigation capabilities, is then inserted into the eye; then the lens nucleus and cortex are broken up with ultrasound and aspirated from the eye (3,5-7). The advantages of this technique over other types of cataract extraction are the ability to remove the cataract through a small incision, keeping the eye inflated throughout surgery, and the complete removal of residual lens cortical material. These advantages generally lead to decreased inflammation and complications after surgery. The disadvantages of this technique are the cost of the instrumentation, the need for a clear cornea to observe surgery, and the trauma to the eye caused by the ultrasonic fragmentation and irrigation fluids (3,7). Especially if the lens is very hard, like in cases of aged and mature cataracts, excess time spent in breaking up the lens causes increased risk of uveitis (2,3).

The purpose of this study was the evaluation of the first results of phacofragmentation and aspiration surgery for cataract extraction to restore visual function in dogs.

Materials and methods

Criteria for selection of cases and preoperative tests

Phacofragmentation and aspiration surgery was planned on 41 ERG positive eyes of 25 dogs of which 9 had unilateral and 16 had bilateral cataracts. The age, breed and gender of the cases were varied. Of the 25 dogs, 16 were female and 9 were male. The mean age was 6 years and 8 months. Intraoperatively, it was decided to perform phacofragmentation surgery on only 32 eyes, while ECCE was performed on 4 eyes and ICCE was performed on 5 eyes for cataract extraction. Cataract was diagnosed with direct ophthalmoscopy and slit lamp biomicroscopy. Vision was evaluated by maze testing, ability to follow thrown cotton balls and by the owners'

observations. Cataracts were classified according to stage as intumescent (Figure 1), immature (Figure 2), mature (Figure 3) and hypermature (Figure 4). Stages of the cataracts are shown in Table 1. Preoperatively, electroretinographies (ERGs) were taken with an LED Google Stimulator in all cases (Medelec Synergy EMG/EP-Oxford Instruments).

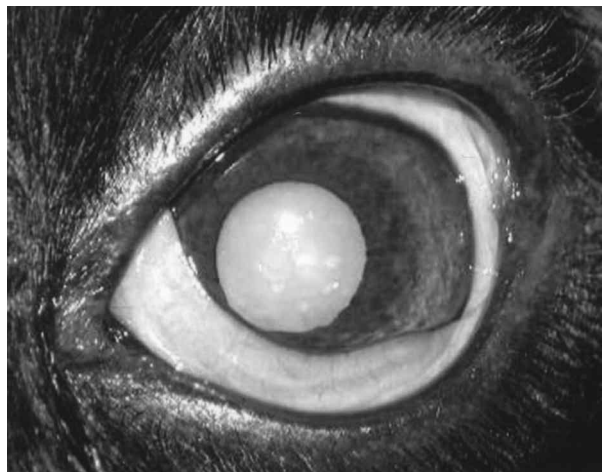

Figure 1. Intumescent cataract.

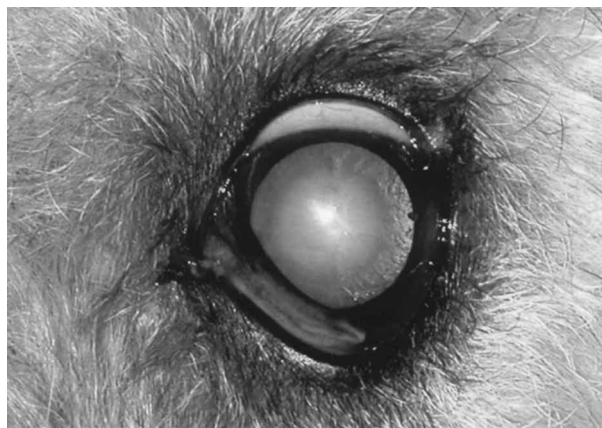


Figure 2. Immature cataract.

Phacofragmentation and aspiration surgery

Preoperatively, 0.1% dexamethasone (Onadron-İbrahim Etem), 0.3% gentamycin (Genta-İbrahim Etem), 0.1% diclofenac sodium (Voltaren-Novartis) and 2% cycloplegic (Siclomid-Abdi İbrahim) ophthalmic solutions were given topically. They were given TID on the day before surgery and it was applied every 30 min for 2 h before surgery and continued after surgery for 1 week or

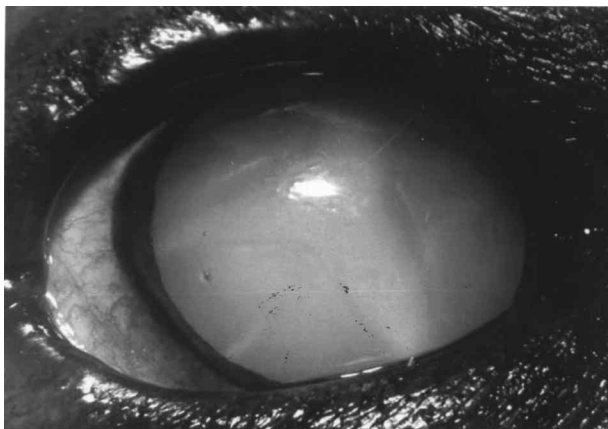


Figure 3. Mature cataract.

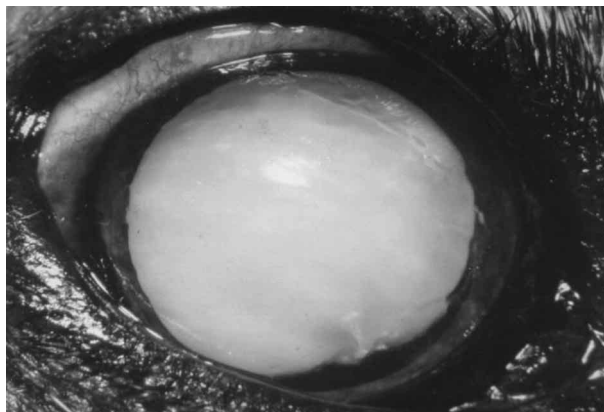


Figure 4. Hypermature cataract.

Table 1. Total number of eyes operated on, the techniques of cataract extraction and stages of cataracts.

Stage of cataracts	Extracapsular phacofragmentation	Intracapsular phacofragmentation	ECCE	ICCE	Total number of eyes operated on
Intumescent	7	-	-	-	7
Immature	8	-	-	-	8
Mature	5	12	2	5	24
Hypermature	-	-	2	-	2
Total number of eyes operated on	20	12	4	5	41

1 month. All phacofragmentation surgeries were performed with the one-handed phacofragmentation technique with the same phacofragmentation-aspiration unit by the same surgeon under propofol (Abbott) and isoflurane (Forane-Abbott) anaesthesia. The phacofragmentation and aspiration unit had phaco 1, phaco 2, anterior vitrectomy, aspiration irrigation and diathermy phases (Surgicon, Synergy AMT). The dogs were prepared and draped for intraocular surgery. First a lateral canthotomy was performed and blepharostat was inserted. Then the bulbus oculi was fixed with conjunctival forceps so that the cornea was parallel to the operation microscope (Tagaki OM 5) (Figure 5). The irrigation aspiration solution contained 500 ml lactated Ringer solution, 0.5 ml heparin and 1 ml adrenalin. A 2-3 mm clear corneal incision was made using a phacoemulsification knife at the 12 o'clock position (Figure 6). The anterior chamber was inflated with viscoelastic material (Healon, 10 mg/ml- Na hyaluronate-Pharmacia Upjohn). Extracapsular phacofragmentation was performed with irrigating cystotome in the eyes with

anterior capsular opacifications. Continuous curvilinear capsulorhexis (CCR) was performed by starting at the 6 o'clock position (Figure 7) and the anterior capsule was removed with Utrata capsulorhexis forceps (Figure 8) because of the thickness of the canine capsule. Endocapsular phacofragmentation was performed on the eyes with no anterior capsular opacifications. Anterior capsulotomy was performed with an irrigating cystotome and the flap was left in the place. After both capsulorhexis and capsulotomy, hydrodissection was performed for separation of the lens cortex from the capsule. Phaco 1 phase was used for sculpting and splitting in the lens nucleus (Figure 9) and phaco 2 phase for removing split fragments (Figure 10 a,b). Irrigation and the aspiration phase were used for removing the softer lens cortex that remained following phacofragmentation (Figure 11), and the vitrectomy phase for removing the vitreous humour when the posterior capsule ruptured. If posterior central capsular opacifications were present, they were removed with capsular polishing using Utrata forceps. Corneal incisions were closed with a traumatic needle and 8/0

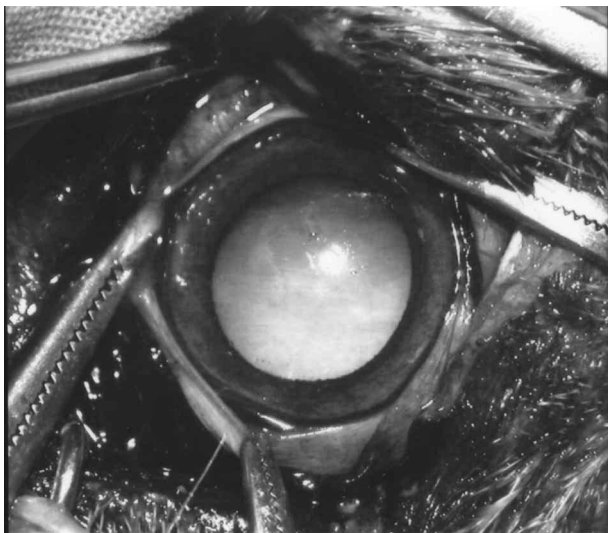


Figure 5. Fixation of the bulbus oculi.

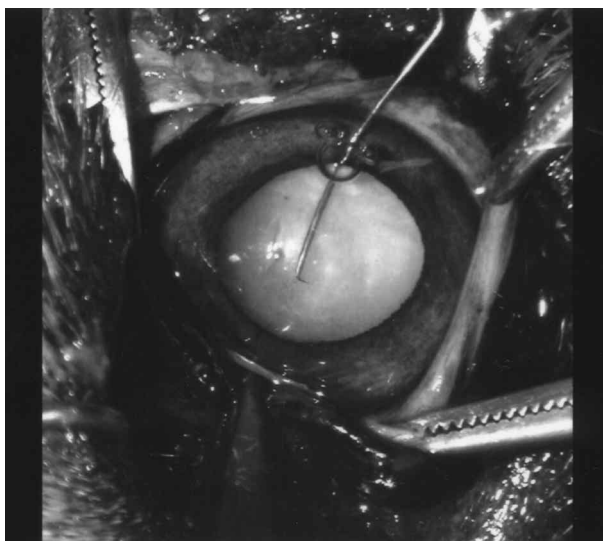


Figure 7. Continuous curvilinear capsulorhexis.

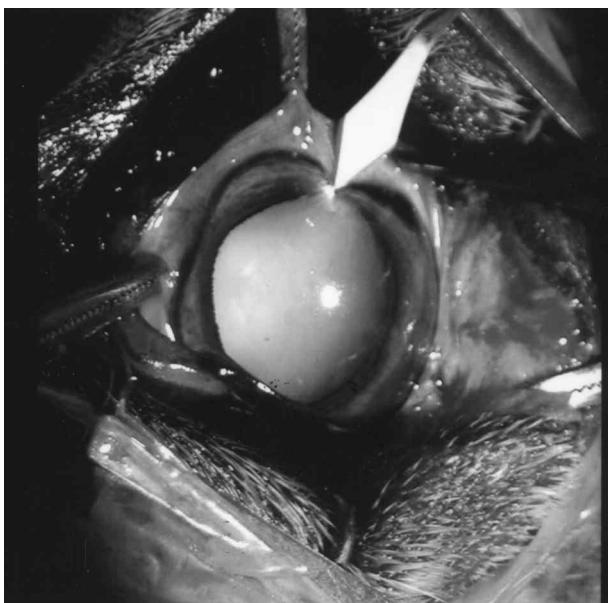


Figure 6. Clear corneal incision with knife at the 12 o'clock position.

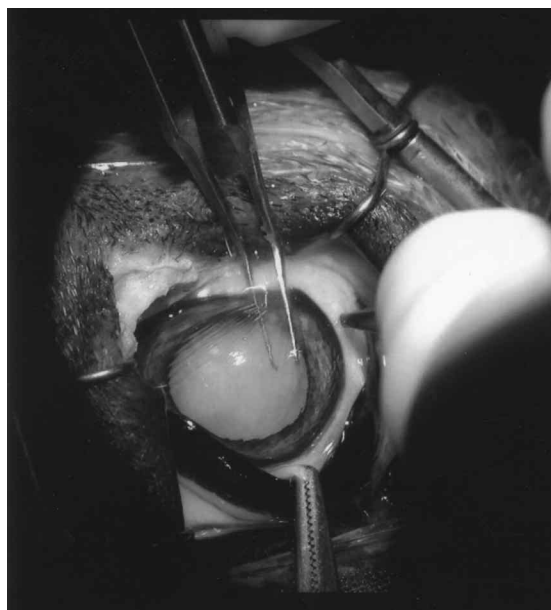


Figure 8. The removing of the anterior lens capsule using Utrata forceps.

monofilament polyamide (Ethilon) using 2 simple interrupted sutures. When the lenses could not be removed with phacofragmentation in cases of lenses that were too hard, the incision was elongated to 180° and ECCE was performed. However, in the eyes with lens luxation ICCE was performed. The surgical techniques for cataract extraction and the total number of eyes operated on are shown in Table 1.

Postoperative evaluation

The topical solutions that were used preoperatively are recommended to be continued for 4 to 6 weeks after

surgery. In the cases of corneal thermal injury and corneal oedema, topical hypertonic saline solutions were used. An Elizabethan collar was used for to prevent self-trauma.

Direct ophthalmoscopy, slit lamp biomicroscopy, maze testing, ability to follow thrown cotton balls and the owners' observations were used in the evaluation of the postoperative vision restoration and complications which could arise. For postoperative follow-up intervals were between 4 weeks and 6 months; in this study only 4 weeks of short-term observations were made.

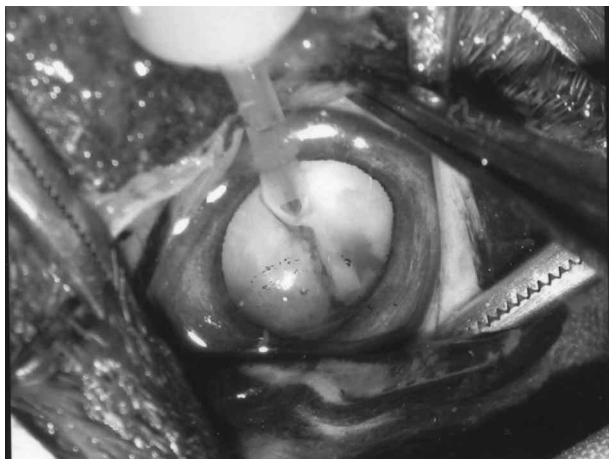


Figure 9. The use of phaco 1 phase for sculpting and splitting in the lens nucleus.

Statistical analysis

Fisher's exact test was used for the evaluation of postoperative vision between immature, intumescent and mature eyes on which phacofragmentation surgery was performed. The risk ratio in the phacofragmentation surgery according to stages of cataracts was evaluated with the odds ratio risk estimated. The Mann-Whitney U test was used to evaluate the importance of age for showing the success rate of phacofragmentation surgery.

Results

Preoperative observations

The distribution of the breeds of the 25 dogs was as follows: terrier (8), Pekingese (2), English cocker spaniel (1), Anatolian shepherd dog (2), American cocker spaniel (4), golden retriever (1), Cavalier King Charles spaniel (1), poodle (1), German shepherd dog (1), Jack Russell terrier (1) and crossbreed (3). Of the 25 dogs, 16 were female and 9 were male (1:17) and the mean age was 6 years 8 months.

The distribution of the breeds of the 20 dogs that underwent phacofragmentation surgery was as follows: terrier (5), American cocker spaniel (3), Pekingese (2), Anatolian shepherd dog (2), German shepherd dog (1), golden retriever (1), Jack Russell terrier (1), Cavalier King Charles spaniel (1), English cocker spaniel (1), poodle (1) and crossbreed (2). The mean age of these 20 dogs was 7 years 3 months and the distribution of sexes was 9 male and 11 female.

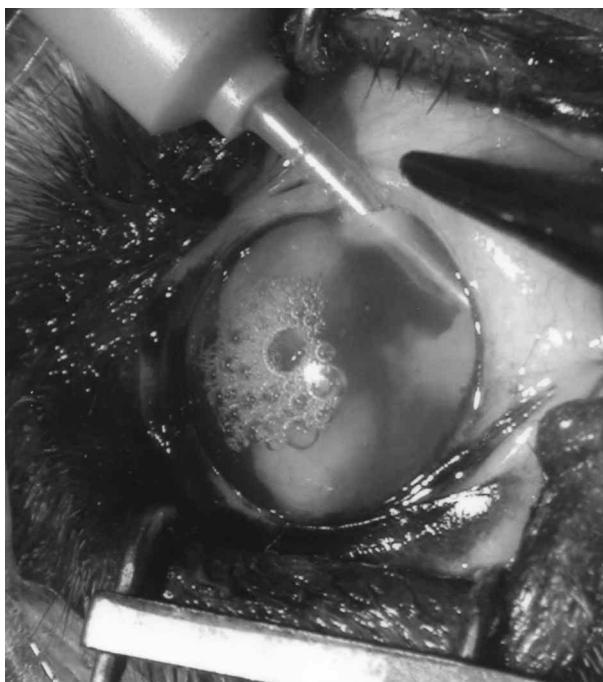
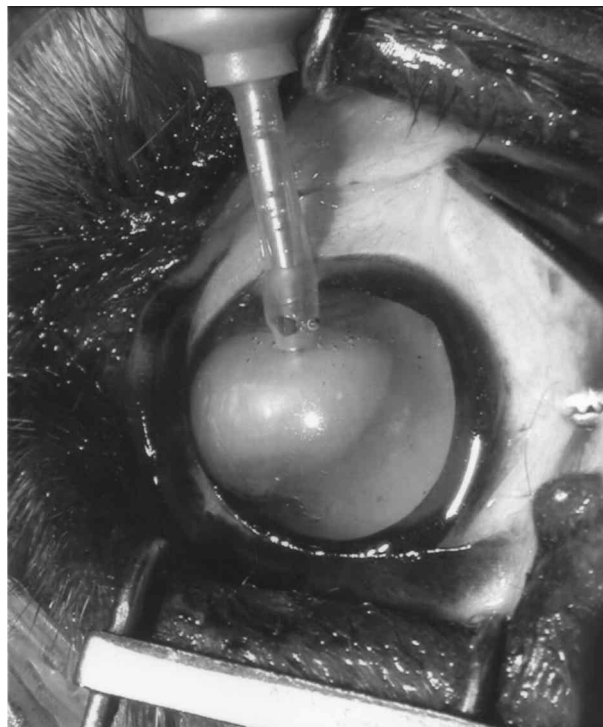


Figure 10 a. The use of phaco 2 phase for removing split fragments. b. The use of phaco 2 phase for removing split fragments.

The stages of the cataracts were as follows: intumescent (7), immature (8), mature (24) and hypermature (2). Stages of the cataracts in eyes in which

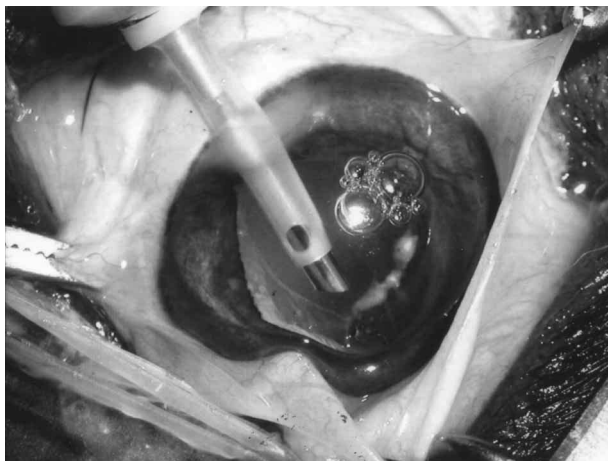


Figure 11. The use of irrigation and aspiration phase for removing the softer lens cortex.

phaco surgery was performed were as follows: 17 mature (53.1%), 8 immature (25%) and 7 intumescent (21.9%).

Phacoemulsification surgery was performed on 32 eyes, ECCE on 4 eyes and ICCE on 5 eyes. Extracapsular phacoemulsification was performed on 20 eyes and intracapsular phacoemulsification on 12 (Table 1).

Intraoperative and postoperative observations

While the mean phacoemulsification time was 1.50 min in intumescent and immature cases, it was 5.30 min in mature cases. The mean irrigation volume was 100 ml in intumescent and immature cases and 300 ml in mature cases.

Functional vision without any complications was established in 18 eyes (56.3%) (Figure 12) from the 32 eyes in which phacoemulsification was performed. Restoration of vision could not be established in 14 eyes (43.8%) because of intraoperative and postoperative complications (Figure 13 and 14) (Table 2).

Functional vision was established in 22.2 % of mature eyes after phacoemulsification surgery and in 77.8% of immature and intumescent eyes. Phacoemulsification surgery was significantly more successful in immature and intumescent cases than in mature cases ($P < 0.0001$). Vision was restored more successfully in eyes with immature and intumescent cataracts (11.7-fold) than in eyes with mature cataracts by phacoemulsification surgery.

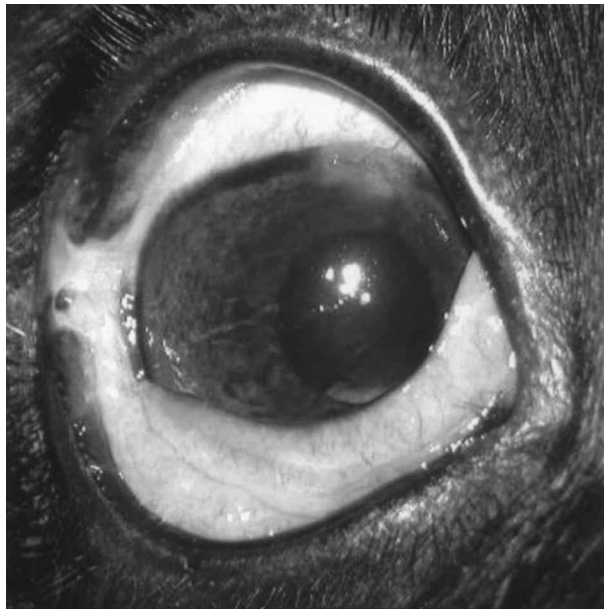


Figure 12. Case without complications postoperatively.

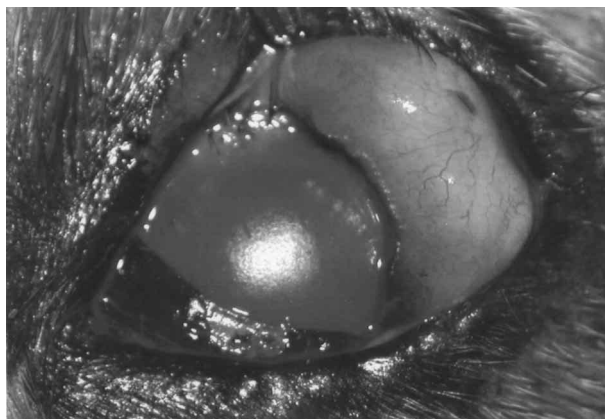


Figure 13. Corneal thermal injury (fluorescein positive).

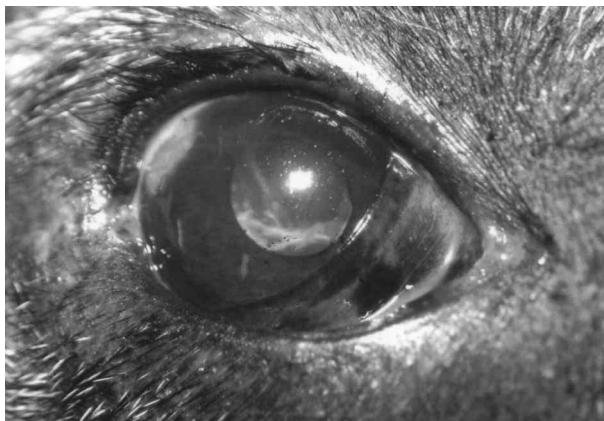


Figure 14. Posterior capsular opacification.

Table 2. The complications of phacofragmentation surgery in 14 dogs.

Breed, age (year), affected eye	Intraoperative complications	Postoperative complications
English cocker spaniel, 7, R	ACF, RTAC, PCR-VP, DFVC	U, RD
English cocker spaniel, 7, L	ACF, RTAC, PCR-VP, DFVC	U, G
Pekingese, 8, L	ACF, RTAC, PCR-VP, DFVC	U, H
Pekingese, 7, R	ACF, RTAC, PCR-VP, DFVC	U
Terrier, 4, R	ACF, RTAC, PCR-VP, CB	U*, H
Terrier, 6, L	ACF, M	U*, H, PCO
Terrier, 6, R	ACF, M	U*, PCO
Terrier, 10, R	ACF, ICH	U*, PCO
Terrier, 10, L	ACF, IH	U, PCO
Poodle, 11, R	ACF, CTI	U, CO, PCO
Poodle, 11, L	ACF, CTI	U, CO, PCO
Cavalier King Charles spaniel, 8, R	ACF, CTI	U, CO, PCO
American cocker spaniel, 10, R	-	U, PCO
American cocker spaniel, 10, R	-	U, PCO

L: left eye, R: right eye, ACF: anterior capsular fibrosis, PCR-VP: posterior capsular rupture-vitreous prolapsus, DFVC: displacement of lens fragments into the vitreous cavity, M: miosis, IH: iris herniation, CTI: corneal thermal injury, RD: retinal detachment, U: uveitis, H: hyphaema, PCO: posterior capsular opacification, G: glaucoma, CO: corneal oedema, RTAC: radial tear in the anterior capsule, CB: cavitation bubbles.

* After uveitis, pupillary occlusion and iris bombe were observed.

The mean age was 8.57 years in the dogs whose functional vision could not be established and 5.88 years in the dogs which had functional vision after phacofragmentation surgery. The observed success rate of the restoration of vision with phacofragmentation surgery was significantly higher in the lower age group than in the higher age group ($P < 0.05$).

The intraoperative complications associated with phacofragmentation surgery seen in this study were anterior capsular fibrosis (ACF, n: 12), radial tear in the anterior capsule (RTAC, n: 5), posterior capsule rupture and vitreous prolapsus (PCR-VP, n: 5), displacement of lens fragments into the vitreous cavity (DFVC, n: 5), cavitation bubbles (CB, n: 1), miosis (M, n: 2), iris herniation (IH, n: 2) and corneal thermal injury (CTI, n: 3), and the postoperative short-term complications were uveitis (U, n: 14), posterior capsular opacification (PCO, n: 9), retinal detachment (RD, n: 1), hyphaema (H, n: 3), glaucoma (G, n: 1) and corneal oedema (CO, n: 3).

Discussion

Many purebreed dogs and their crosses are predisposed to juvenile and senile cataracts (5). In this study, 22 of 25 dogs were purebreeds and only 3 were crossbreeds. 18 of the 20 dogs that underwent phacofragmentation were purebreeds and only 2 were crossbreeds. A high number of senile cataracts is seen in purebreed dogs and this was confirmed by the high mean age (6 years, 8 months) in our cases. In this study, the main reason that far more cataracts were seen in the terrier breeds (8 cases) was correlated to the predisposition of this breed to cataract formation and the preference for this breed by owners in Turkey.

While the mean postoperative success rate in ECCE surgery was reported to be 80% (6) and 42% (8), the postoperative short-term success rate reported in phacofragmentation surgery was 94.6% (1) and 84% (8). The short-term success rate of phacofragmentation surgery in the present study was 56.3%. In contrast to our findings, Miller et al. (1) reported that the age of

dogs had little effect on the success of phacofragmentation surgery. However, in this study, the mean age in the 14 vision-negative cases was 8.57 and in the 18 dogs with positive vision it was 5.88. Phacofragmentation surgery was significantly more successful in young dogs compared with aged dogs ($P < 0.05$). Most of the dogs which had complications in this study were old and they had end-stage mature cataracts, and this was considered the main reason for the low success rate of phacofragmentation surgery. In this study, achievement of vision restoration in 22.2% of mature stage cases and in 77.8% of immature and intumescent stage cases showed that end-stage maturity decreases the success rate of phacofragmentation surgery ($P < 0.0001$). Appropriate application of CCR, which is very important in the success of phacofragmentation surgery, is correlated to the fineness and elasticity of the anterior lens capsule. It is thought that both age and end-stage maturity have effects on the loss of thickness and elasticity of the anterior lens capsule.

Although the most common intraoperative complications are rupture of the posterior lens capsule and prolapse of vitreous into the capsular bag or anterior chamber (4,6,7,9), anterior capsule fibrosis (when the lenses are allowed to become hypermature), Descemet's membrane tearing (from phaco needle), miosis, iris herniation through the incision, radial tears in the anterior capsule, displacement of lens fragments into the vitreous cavity, posterior capsule opacification, cavitation bubbles (5,6), corneal thermal injury and persistent corneal oedema (10) have also been reported.

In this study intraoperative complications were ACF in end-stage mature cases, PCR-VP, M, IH, DFVC, RTAC, CB and CTI. The most commonly seen intraoperative complications, ACF, RTAC and PCR-VP, were related to the stages of the cataracts and the ages of the dogs. IH was related to vitreous expansions, and CTI and CB were related to difficulties in fragmentation of the lens cortex and nucleus by phacofragmentation. Bagley and Lavach (2) reported that mean phaco duration was 2.75 min and irrigation volume was 142 ml. However, in this study the mean phaco duration was 1.75 min in intumescent and immature cases and 11.7 min in mature cases. On the other hand, irrigation volume was 100 ml in intumescent and immature cases and 300 ml in mature cases. Therefore the high levels of mean phaco duration and irrigation volume in mature cases in this study are

thought to be the reason for the high numbers of complications.

Corneal wound dehiscence, aqueous leakage, corneal oedema (from damage to the corneal endothelia), uveitis, bacterial endophthalmitis, posterior capsule opacification, hyphaema, retinal detachment and glaucoma (developed a pupillary block from posterior synechia, iris bombe or aqueous humour outflow obstruction by inflammatory debris) (1-3,5,6), optic neuritis, retinal haemorrhage and corneal lipidosis (2) were reported to be the most common postoperative complications in phacofragmentation and aspiration surgery.

In this study the postoperative complications were PCO, U, H, RD, G and CO. Significantly high levels of irrigation volume and duration were thought to be the main reasons for the traumatic uveitis, CO and G. Postoperative opacification of an initially clear posterior capsule is a frequent complication following phacofragmentation and ECCE surgery in dogs and humans (5). In general, the posterior capsule itself does not opacify but lens epithelial cells migrate from the anterior to the posterior capsule to cause opacification. For the treatment of posterior capsular opacification (PCO), the usage of a neodymium yttrium-aluminium-garnet laser (3,5), posterior chamber intraocular lenses (IOLs) (5,11,12), 5 fluorouracil (13) and posterior capsule polishing (5) has been reported. It is also reported that capsular polishing does not prevent capsular opacification (14). A combination of CCR, hydrodissection and specific IOLs was reported to diminish these complications' incidence (15). In this study, PCO was observed in 9 eyes; however, 2 out of 9 eyes were operated on for the second time and capsular polishing was performed. Vision was restored by phacofragmentation surgery more successfully in eyes with immature and intumescent cataracts (11.7-fold) than in eyes with mature cataracts.

It is concluded that the success of phacofragmentation surgery increases if the animals are young, the cataracts are at the intumescent or immature stages, and Utrata forceps are used in CCR.

Acknowledgements

I would like to thank Associate Prof. Dr. Mehmet Orman for the statistical analysis and Research Assistant Salih Eminağa for his kind help.

References

1. Miller, T.R., Whitley, R.D., Meek, L.A., Garcia, G.A., Wilson, M.C., Rawls, B.H.: Phacofragmentation and aspiration for cataract extraction in dogs: 56 cases (1980-1984). *J. Am. Vet. Med. Assoc.*, 1987; 190: 1577-1579.
2. Bagley, L.H. and Lavach, J.D.: Comparison of postoperative phacoemulsification results in dogs with and without diabetes mellitus. 153 cases (1991-1992). *J. Am. Vet. Med. Assoc.*, 1994; 205: 1165-1168.
3. Dziezyc, J.: Cataract surgery: *Vet. Clin. North Am.*, 1990; 20: 737-753.
4. Williams, D.L., Boydell, I.P., Long, R.D.: Current concepts in the management of canine cataract: a survey of techniques used by surgeon in Britain, Europe and the USA and a review of recent literature: *Vet. Rec.*, 1996; 138: 347-353.
5. Glover, T.D., Constantinescu, G.M.: Surgery for cataracts: *Vet. Clin. North Am. Small Anim. Pract.*, 1977; 27:1143-1173.
6. Nassie, M.P., Davidson, M.G.: Surgery of the lens. In: *Veterinary Ophthalmology* (edited by Gellat, K.N., 3rd edition), Philadelphia, Lippincot Williams and Wilkins, 827-856, 1999.
7. Gilger, B.C.: Lens. In: *Textbook of Small Animal Surgery* (edited by Slatter, D., 3rd edition), Philadelphia, Saunders, 1402-1418, 2003.
8. Zahn, K., Kostlin, R.: Lens surgery in dogs. Part 2: Postoperative complications and results of 140 cataract extractions: *Tierarztl. Prax. K. H.*, 2002; 30: 98-105.
9. Zahn, K., Kostlin, R.: Lens surgery in dogs-retro- and prospective evaluation of 230 eye surgeries. Part 1: indications, surgical methods and intraoperative complications: *Tierarztl. Prax. K. H.*, 2001; 29: 164-172.
10. Polack, F.M., Sugar, A.: The phacoemulsification procedure. III. corneal complications: *Invest. Ophthalmol. Visual Sci.*, 1977; 16: 39-46.
11. Nagamoto, T., Eguchi, G.: Effect of intraocular lens design on migration of lens epithelial cells onto the posterior capsule. *J. Cataract Refract Surg.*, 1997; 23: 866-872.
12. Clark, D.S.: Posterior capsule opacification: *Curr. Opin. Ophthalmol.*, 2000; 11: 56-64.
13. Pandey, S.K., Cochener, B., Apple, D.J., Colin, J., Werner, L., Bougaran, R., Trivedi, R.H., Macky, T.A., Izak, A.M.: Intracapsular ring sustained 5 fluorouracil delivery system for the prevention of posterior capsule opacification in rabbits: a histological study: *J. Cataract Refr. Surg.*, 2002; 28: 139-148.
14. Wilhelmus, K.R., Emery, J.M.: Posterior capsul opacification following phacoemulcification: *Ophthalmic Surg. Las.*, 1980; 11: 264-267.
15. Apple, D.J., Solomon, K.D., Tetz, M.R., Assia, E.I., Holland, E.Y., Legler, U.F., Tsai, J.C., Casteneda, V.E., Hoggat, J.P., Kostick, A.M.: Posterior capsule opacification: *Surv. Ophthalmol.*, 1992; 37: 73-116.