

## Encephalomyelitis Associated With A Sarcocystis-Like Protozoan in A Ten-Month-Old Ewe Lamb

Öznur YAZICIOĞLU

Pathology Laboratory, Bornova Veterinary Control and Research Institute, 35010 İzmir - TURKEY  
E-mail: oznurya@yahoo.com

Ayşen BEYAZIT

Parasitology Laboratory, Bornova Veterinary Control and Research Institute, 35010 İzmir - TURKEY

Received: 17.06.2004

**Abstract:** This paper reports the pathological findings of non-suppurative encephalomyelitis associated with a Sarcocystis-like protozoan in a 10-month-old ewe lamb showing neurological signs. The encephalomyelitis was characterized by mild to moderate multifocal perivascular mononuclear cell infiltrations, and randomly scattered glial foci, especially more severe in the thalamus, cerebellum, and pons. A few protozoan meronts were observed within the endothelium of small capillaries in the thalamus, and small numbers of mature tissue cysts, similar to muscle sarcocysts, in sections of the cerebrum and pons. All muscle samples of this lamb had also a severe mixed infection with sarcocysts of *S. tenella* and *S. arieticanis*.

**Key Words:** Sarcocystis, lamb, encephalomyelitis

### On Aylık Bir Tokluda Sarcocystis Benzeri Bir Protozoan İle İlgili Ensefalomyelitis

**Özet:** Bu gözlemede, sinirsel semptom gösteren 10 aylık bir tokluda, Sarcocystis benzeri bir protozoan ile ilgili non-suppuratif ensefalomyelitisin patolojik bulguları sunuldu. Ensefalomyelitis, hafif-orta şiddette multifokal perivasküler mononükleer hücre infiltrasyonları ve özellikle talamus, serebellum ve ponsta daha şiddetli olan rastgele dağılmış glial odaklar ile karakterizydi. Talamusta birkaç kapillar damar endoteli içinde protozoan merontlar ve serebrum ile pons kesitlerinde kas sarkokistlerine benzer az sayıda olgun doku kistleri gözlemlendi. Bu kuzunun tüm kas örnekleri de çok sayıda *S. tenella* and *S. arieticanis* kistleri ile şiddetli derecede miks bir enfeksiyona sahipti.

**Anahtar Sözcükler:** Sarcocystis, kuzu, ensefalomyelitis

### Introduction

Sarcocystis species are cyst-forming sporozoan parasites with an obligatory 2-host cycle. Of the 4 species of Sarcocystis reported from sheep, *Sarcocystis tenella* and *Sarcocystis arieticanis* form microscopic sarcocysts (1,2) and can cause neurological disease, characterized by ataxia leading to recumbency (3-7). It has been reported that outbreaks of ovine protozoan encephalomyelitis associated with sarcocystosis mostly affected individual animals or small proportions of the flocks (3,5,7), together with often mild neurological signs and a clinical recovery (7-9), or rarely a high mortality rate (4,6). The diagnosis usually depends on the presence of Sarcocystis meronts and mature sarcocysts in the histologic sections of the brain and spinal cord (3,5,7,8). However, the

precise etiological diagnosis of encephalic sarcocystosis on morphological grounds alone may be difficult if death occurs after the peak of second generation merogony and before cysts develop in large numbers (8). In such a case, immunohistochemistry is advised not only for the identification of sparsely distributed meronts in infected tissue (10) but also for the differentiation of Sarcocystis spp. from 2 other protozoans, *Toxoplasma gondii* (7,9,10) and *Neospora caninum* (5,7,9,11), resulting in encephalitis mainly in fetal and neonatal lambs.

In Turkey, the prevalences of Sarcocystis species present in sheep in different provinces have been well-documented but encephalomyelitis associated with this protozoan parasite has not been reported yet.

This paper describes the pathological findings of non-suppurative encephalomyelitis associated with a Sarcocystis-like protozoan in a 10-month-old ewe lamb showing neurological signs in İzmir province, Turkey.

### Case History

The case involved a 10-month-old ewe lamb from a flock of 170 sheep in Menemen, İzmir province. The flock was moved to the hills for grazing in the mornings and was kept in a pen adjacent to the owner's house at nights, along with 3 shepherd dogs. This pen had a soil floor permanently polluted with feces. No antiparasitic compound had been given to the dogs. These dogs had occasionally been fed residual raw meat from a slaughterhouse by the owner. The owner stated that one lamb showing initially clinical signs such as anorexia, weight loss, lagging behind the rest of flock, and difficulty in getting up developed hindlimb ataxia and convulsions, and was often lying in lateral recumbency with limbs stretched out to one side over the previous several days. This ill ewe lamb with marked skeletal muscle weakness was submitted alive to the Pathology Laboratory, Bornova Veterinary Control and Research Institute, İzmir, for diagnosis on December 14, 2000.

Samples from the brain, cervical spinal cord, esophagus, diaphragm, tongue, heart, fore- and hindlimb muscles, and visceral organs including the liver, lungs, kidneys, small intestine and mesenteric lymph nodes were fixed in 10% neutral buffered formalin, processed routinely, sectioned at 5 µm, and stained with hematoxylin and eosin (12). Meront dimensions were measured with an ocular micrometer. In addition, the muscle samples were also examined for the presence of Sarcocystis species by the digestion method, using a NaCl-buffered 0.25% trypsin solution as described by Erber (13). Sarcocystis species present were identified on the basis of differences in their cyst wall morphologies as described by Dubey et al. (2).

### Results and Discussion

No gross lesions were observed in the muscles or visceral organs or in the brain or cervical spinal cord at necropsy, except for mucoid atrophy of body fat and hydropericardium. Histopathological examination revealed mild to moderate multifocal non-suppurative

encephalomyelitis and mild multifocal mononuclear cell infiltrations throughout the leptomeninges. The encephalitis was characterized by multifocal perivascular infiltrations of mononuclear cells, and randomly scattered glial foci in both the gray and white matter of the brain, which were especially severe in the thalamus, cerebellum, and pons. Perivascular cuffs were composed primarily of lymphocytes and fewer plasma cells in varying numbers one to several cells thick. A few protozoan meronts were detected within the endothelium of small capillaries in the vicinity of inflammatory foci in the thalamus. Meronts (n = 5) were measured as 10-10x10-15 µm. They had filled the cytoplasm of endothelial cells so that they interfered with visualization of nuclei of cells and obstructed them by projecting into the lumens of capillaries (Figure 1). Lesions in the cervical spinal cord included mild perivascular mononuclear cell infiltrations. Small numbers of mature tissue cysts, similar to muscle sarcocysts, sparsely distributed, were also observed in most sections of the cerebrum and pons (Figure 2).

Tissue cysts in the cerebrum were frequently localized in the layer of stratum moleculare of the gray matter immediately beneath the meninges, and rarely in the periventricular white matter of the cerebral cortex. They had no associated host reaction. All muscle samples of the lamb had also a severe mixed infection with numerous sarcocysts of *S. tenella* and *S. arieticanis*. There were mild to moderate, multifocal interstitial and mostly perivascular mononuclear cell infiltrations in the skeletal and cardiac muscles. Muscle fibers containing degenerative cysts, some of which were infiltrated and surrounded by mononuclear cells mingled with, in varying numbers, neutrophils, were especially numerous in the skeletal muscles. No meront was seen in the muscles or visceral organs other than the brain.

There have recently been many reports of non-suppurative encephalomyelitis associated with naturally and experimentally moderate to severe Sarcocystis infestations of muscle tissues in lambs (3-6,8,9,14) and adult sheep (7). Although 2 morphologically distinct types of microscopic sarcocyst are common and sometimes numerous in the muscles of sheep, Sarcocystis-associated encephalomyelitis affecting largely immature sheep is rarely diagnosed. It has been reported that the predisposing husbandry factors can influence the animals' degree of exposure to the infective stages and lead to outbreaks of the condition (5). Most outbreaks have

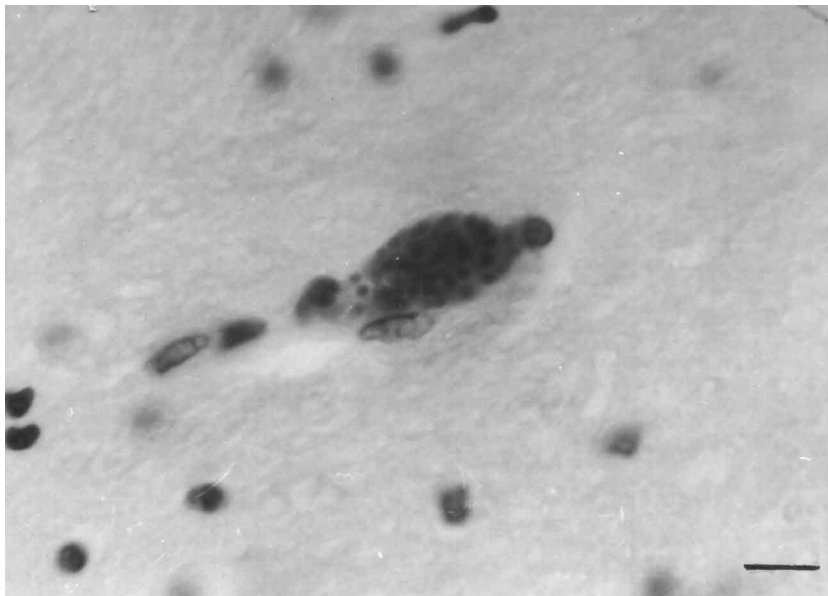


Figure 1. A meront within the endothelium of a capillary in the thalamus. Bar = 10  $\mu$ m.

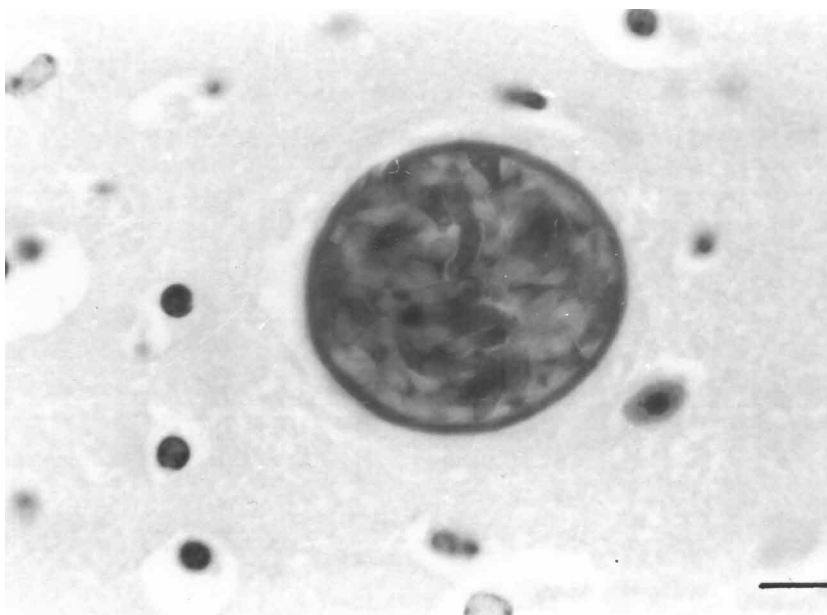

Figure 2. A mature sarcocyst in the cerebrum. Bar = 10  $\mu$ m.

occurred after the flocks were moved from a clean environment such as the hill pastures to areas heavily contaminated by dog feces or when they were housed in such an infected environment (3-7). In addition, stresses such as pregnancy, lactation, poor nutrition, and weather may play an important role in the severity of clinical

illness and susceptibility to infection (2). The present case also occurred in a flock kept in poor management conditions and housed along with dogs that were fed raw meat occasionally. Histopathological changes detected in the central nervous system were consistent with the observations of most researchers (3-7,9), except for

some findings reported such as the malacic changes in the spinal cord (3,9) or neuronal necrosis and microcavitation of the neuropile adjacent to the areas of cuffing in the brain (7). However, all levels of the spinal cord weren't examined. In addition, a parasitophorous vacuole was not observed around the mature tissue cysts in the brain sections, unlike those described by Parihar (15) and Henderson et al. (7). Since *Sarcocystis* meronts develop and multiply in the vascular endothelium throughout the body, they are identified by their specific endothelial cell tropism (2,10). In this case, the endothelial localization of

meronts and the morphology of tissue cysts in the brain were consistent with *Sarcocystis*. Moreover, all muscle samples of this lamb were also infected with very large numbers of sarcocysts, as reported by others (3-7).

The present case is the first report of ovine protozoan encephalomyelitis presumably associated with sarcocystosis in a young sheep in Turkey. This protozoan should also be considered in immature sheep showing clinically neurological findings and from areas with high prevalence of *Sarcocystis* infection, as well as in the present case.

## References

1. Dubey, J.P.: A review of *Sarcocystis* of domestic animals and of other Coccidia of cats and dogs. J. Am. Vet. Med. Assoc., 1976; 169: 1061-1078.
2. Dubey, J.P., Speer, C.A., Fayer, R.: *Sarcocystosis of Animals and Man*. CRC Press, Inc., Boca Raton, Florida, 1989; 113-120.
3. Stubbings, D.P., Jeffrey, M.: Presumptive protozoan (*Sarcocystis*) encephalomyelitis with paresis in lambs. Vet. Rec., 1985; 116: 373-374.
4. Fitzgerald, S.D., Janovitz, E.B., Kazacos, K.R., Dubey, J.P., Murphy, D.A.: *Sarcocystosis* with involvement of the central nervous system in lambs. J. Vet. Diagn. Invest., 1993; 5: 291-296.
5. Caldwell, G.L., Gidlow, J.R., Schock, A.: Clinical, pathological and epidemiological findings in three outbreaks of ovine protozoan myeloencephalitis. Vet. Rec., 2000; 146: 7-10.
6. Sargison, N.D., Schock, A., Maclean, I.A., Rae, A., Heckerorth, A.R., Clark, A.M.: Unusual outbreak of sporozoan encephalomyelitis in Bluefaced Leicester ram lambs. Vet. Rec., 2000; 146: 225-226.
7. Henderson, J.M., Dies, K.H., Haines, D.M., Higgs, G.W., Ayroud, M.: Neurological symptoms associated with sarcocystosis in adult sheep. Can. Vet. J., 1997; 38: 168-170.
8. O'Toole, D., Duffell, S.J., Upcott, D.H., Frewin, D.: Experimental microcyst *Sarcocystis* infection in lambs: Pathology. Vet. Rec., 1986; 119: 525-531.
9. O'Toole, D., Jeffrey, M., Challoner, D., Maybey, R., Welch, V.: Ovine myeloencephalitis-leukomyelomalacia associated with a *Sarcocystis*-like protozoan. J. Vet. Diagn. Invest., 1993; 5: 212-225.
10. Jeffrey, M., O'Toole, D., Smith, T., Bridges, A.W.: Immunocytochemistry of ovine sporozoan encephalitis and encephalomyelitis. J. Comp. Pathol., 1988; 98: 213-224.
11. McAllister, M.M., McGuire, A.M., Jolley, W.R., Lindsay, D.S., Trees, A.J., Stobart, R.H.: Experimental neosporosis in pregnant ewes and their offspring. Vet. Pathol., 1996; 33 : 647-655.
12. Luna, L.G.: *Manual of Histologic Staining Methods of the Armed Forces Institute of Pathology*. 3rd ed, McGraw-Hill Book Company, New York, Toronto, London, Sydney, 1968; 38-39.
13. Erber, M.: Möglichkeiten des Nachweisses und der Differenzierung von Zwei *Sarcocystis*-Arten des Schweines. Berl. Münch. Tierarztl. Wochenschr. 1977; 90: 480-482.
14. Scott, P.R., Watt, N.J., Woodman, M.P., McGorum, B., McDiarmid, A.: Protozoan encephalomyelitis causing pelvic limb paresis in a yearling sheep. New Zeal. Vet. J., 1993; 41: 139-141.
15. Parihar, N.S.: *Sarcocystis* in sheep brain. Indian J. Anim. Sci., 1987; 57: 1291-1293.