

## Sebaceous Gland Adenoma in a Dog

M. Özgür ÖZYİĞİT\*, Ahmet AKKOÇ, Raşan YILMAZ

Department of Pathology, Faculty of Veterinary Medicine, Uludağ University, 16059, Görükle, Bursa - TURKEY

\*E-mail: ozyigit@uludag.edu.tr

Received: 22.10.2004

**Abstract:** A 14-year-old male cocker spaniel was diagnosed with sebaceous gland adenoma in the right external ear canal. Macroscopically, a whitish nodular mass, 3.1 x 3.5 x 2.2 cm in size, moderate to firm in consistency, was seen. The cut surface of the tumoral mass was solid. In the microscopical examination, the tumoral mass was formed by many lobules composed of 2 types of different cells (basaloid and sebaceous cells). Because of the mass within the external ear canal, the dog had severe otitis externa and problems in hearing.

**Key Words:** Sebaceous gland adenoma, dog, otitis externa

### Bir Köpekte Yağ Bezi Adenomü

**Özet:** Bu olayda 14 yaşında erkek bir Spaniel Cocker ırkı köpeğe sağ dış kulak kanalında yağ bezi adenomu teşhisi konuldu. Makroskopik olarak, boyutları 3,1 x 3,5 x 2,2 cm, beyaz renkli nodüler yapıda, orta sert kıvamlı ve kesit yüzü solid olan tümöral kitle gözlemlendi. Mikroskopik incelemede, tümöral kitlenin bazaloid ve sebasöz hücrelerin oluşturduğu çok sayıda lobüllerden meydana geldiği görüldü. Tümörün dış kulak kanalı girişine yerleşerek hayvanda sekonder olarak şiddetli otitis eksternaya ve işitme problemlerine yol açtığı tespit edildi.

**Anahtar Sözcükler:** Yağ bezi adenomu, köpek, otitis eksterna

### Introduction

Sebaceous gland tumors are seen in all domestic animals but are more common in older dogs and cats (1-4). They are the most common epithelial skin tumors and may be observed in the skin anywhere on the body in dogs. The head, abdomen and thorax are the primary sites for sebaceous gland tumors (1,2,5). Additionally, the eyelid is the most common site for these tumors (2,4,6). The exact etiology of sebaceous gland tumors is not known (7,8), but it is supposed that hormonal dysfunction may play a significant role in their development (9). Sebaceous gland tumors can be classified according to the level of cell maturation including nodular hyperplasia, sebaceous adenoma, sebaceous epithelioma and sebaceous adenocarcinoma. Sebaceous adenomas may be single or multiple and they are larger than 1 cm in diameter (2,8). The mean age of affected dogs is 9-10 years (1,2,5,7-9). Cocker spaniels, huskies, samoyeds and Alaskan malamutes are

predisposed to develop sebaceous gland tumors (2,4,10). The reported occurrence frequency of sebaceous adenomas, after incomplete surgical removal, is rather high (1,2,4).

### Case History

A 14-year-old male cocker spaniel was referred to a veterinary clinic with a history of progressive otitis externa, purulent discharge, problems in hearing, pruritus and the presence of a mass within the right external ear canal. The mass was surgically removed and antibiotic treatment was started. One month later, the dog was again referred to the clinic with the same problems. A second surgical operation was performed and tissue samples taken from the right ear were sent to the pathology department for histopathological examination. The dog was diagnosed with sebaceous adenoma. At the end, the dog was again referred to the

clinic with the same but severe lesions. Then total ear extirpation was performed with the consent of the owner.

## Results and Discussion

In the macroscopical examination, a whitish nodular tumoral mass, 3.1 x 3.5 x 2.2 (w x l x h) cm in size, moderate to firm in consistency, was observed in the right external ear canal (Figure 1). The cut surface of the tumoral mass was solid.

In the microscopical examination, well-delimited and circumscribed lobules, varying in size, were seen below the ulcerated epidermis (Figure 2). These lobules were composed of 2 types of cells, undifferentiated generative (peripheral basaloid) cells and sebaceous cells showing different degrees of sebaceous differentiation (fatty vacuolization in the cytoplasm) located in the center of the lobules (Figure 3). The center of some lobules was cystic and filled with pinkish, necrotic amorphous material. Cellular atypia and mitotic figures were uncommon. No inflammatory cells were seen around the lobules but many mononuclear and polymorphonuclear leukocytes were observed below the ulcerated epidermis.

Sebaceous adenomas are relatively uncommon and characterized by mostly sebocytes with basaloid cells and ducts (2,4,11-13). They are more common in small

breeds (1,2,4,8,10). Some researchers have reported that the frequency of sebaceous gland adenomas in all tumors was 5% and the mean age was 9-10 years (1,5,7,8,9). It was stated that the tumor may involve the skin anywhere on the body (1,2,4,8) and may cause loss of function according to settlement (10,14). Secondary bacterial infections may occur together with sebaceous adenomas in the ear because of their obstructive effects (10), as in the present case. Recurrence of sebaceous adenomas is usually observed after an incomplete surgical operation (1,2,7). In the case reported here, because of the incomplete surgical operation and insufficient supporting treatments, the tumor recurred twice. It is not very easy to distinguish sebaceous adenoma from sebaceous hyperplasia microscopically, but the macroscopic features of sebaceous adenomas are characteristic (4,8). Sebaceous adenoma is usually less lobulated and greater than 1 cm in diameter, while sebaceous hyperplasia is commonly papillated, and 2-5 mm in diameter (2,4). In the case described here, the tumor was 3.5 cm in diameter and this macroscopic feature can be used as a diagnostic tool for distinguishing sebaceous adenoma from sebaceous hyperplasia. The tumor is mainly composed of 2 types of cells, namely, undifferentiated basaloid cells at the periphery and cells showing varying degrees of sebaceous differentiation toward the center (11-13). Lobules were well-demarcated from surrounding tissue and the centers of

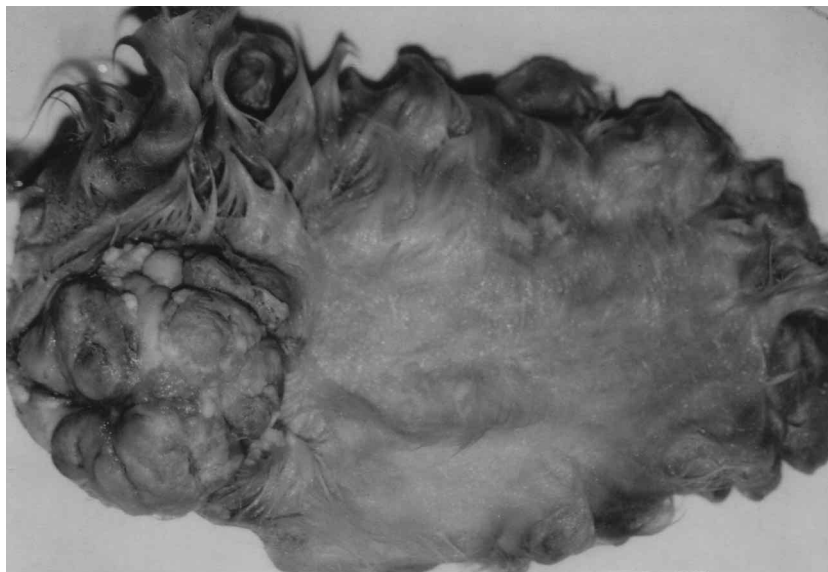


Figure 1. Whitish nodular, tumoral mass in the external ear canal.

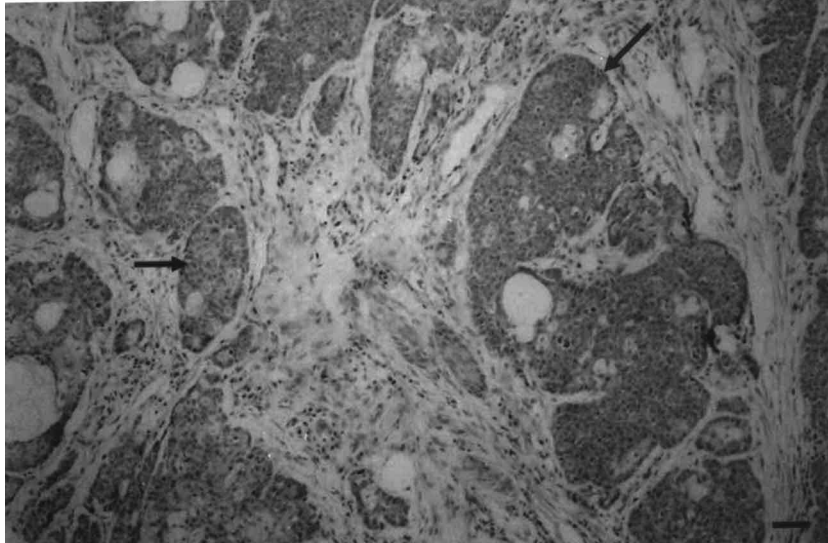


Figure 2. Varying in size, well-delimited and circumscribed lobules (arrows) Bar = 50  $\mu$ m (H&E).

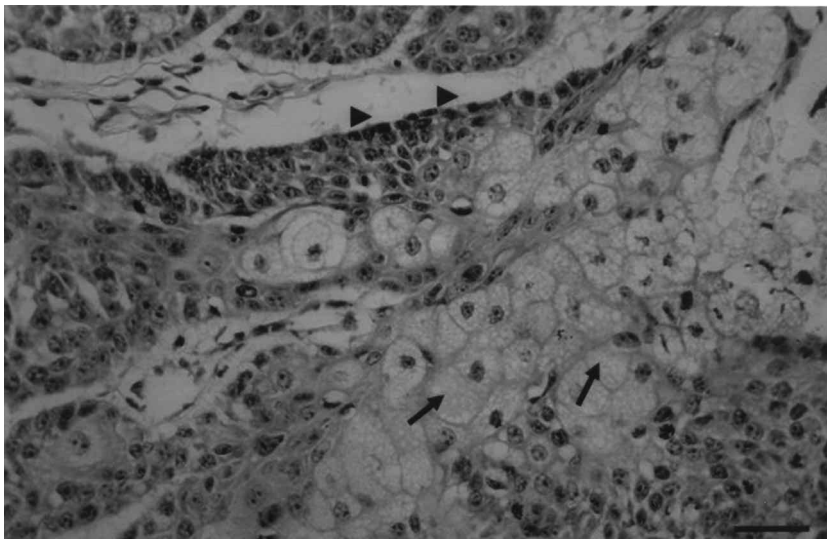


Figure 3. Sebaceous lobule, peripheral basaloid cells (arrow heads) and sebaceous cells (arrows). Bar = 50  $\mu$ m (H&E).

some lobules were cystic and filled with amorphous material, in agreement with the literature (2,11,15). While some lobules contain mainly basaloid cells, some predominantly contain mature sebaceous cells in nodular sebaceous hyperplasia (1,11,12). Unlike in the case described here, both basaloid and mature sebaceous cells were observed together in the lobules. The infiltration of lymphocytes, plasma cells and the observation of mature melanocytic cells around the lobules are prominent

features of sebaceous epitheliomas (2). In contrast, no inflammatory reaction was observed in our report.

In the present case, all gross and histopathological features suggested sebaceous adenoma. Although sebaceous epithelioma was reported in a retrospective study (16), to our knowledge, this case is the first detailed description of a sebaceous gland adenoma in the right external ear canal of a cocker spaniel in Turkey.

## References

1. Strafuss, A.C.: Sebaceous gland adenomas in dogs. *J. Am. Vet. Med. Assoc.*, 1976; 15: 640-642.
2. Pullet, L.T., Stannard, A.A.: Tumor of the Skin of Soft Tissues. In: Moulton J.E., Ed. *Tumors in Domestic Animals*. 3rd ed., University of California Press, California. 1990; 23-87.
3. Roberts, S.M., Severin, G.A., Lavach, J.D.: Prevalence and treatment of palpebral neoplasms in the dog: 200 cases (1975-1983). *J. Am. Vet. Med. Assoc.*, 1986; 189: 1355-1359.
4. Vail, M.D., Withrow, S.J.: Tumors of the skin and subcutaneous tissue. In: Withrow, S.J., MacEwen, E.G., Eds. *Small Animal Clinical Oncology*. 2nd ed., W.B. Saunders Company, Pennsylvania. 1996; 167-191.
5. Halouzka, R., Nevole, M.: Sebaceous gland tumors in dogs. *Vet. Med. (Praha)*, 1976; 21: 565-572.
6. Krehbiel, J.D., Langham, R.F.: Eyelid neoplasms of dogs. *Am. J. Vet. Res.*, 1975; 36: 115-119.
7. Jakab, C.: Histopathological analysis of tumours of the sebaceous gland in spaniels. *Kisallat Praxis.*, 2003; 4: 36-38.
8. Muller, G.H., Kirk, R.W., Scott, D.W.: Neoplastic Diseases. In: Dyson, J., Ed. *Small Animal Dermatology*. 4th ed., W.B. Saunders Company, Philadelphia, 1989; 844-958.
9. Rungsipat, A.: Neoplasms of dogs in Bangkok. *Thai J. Vet. Med.*, 2003; 33: 59-66.
10. Angus, J.C., Lichtensteiger, C., Campbell, K.L., Schaeffer, D.J.: Breed variations in histopathologic features of chronic severe otitis externa in dogs: 80 Cases (1995-2001). *J. Am. Vet. Med. Assoc.*, 2002; 221: 1000-1006.
11. Goldschmidt, M.H.: Sebaceous and hepatoid gland neoplasms of dogs and cats. *Am. J. Dermatopathol.*, 1984; 6: 287-293.
12. Mahesh Kumar, M.J., Nagarajan, P., Venkatesan, R., Sakthivelan, S.M., Majumdar, S.S.: Sebaceous gland adenoma in a rhesus monkey (*Macaca mulatta*). *J. Med. Primatol.*, 2004; 33: 214-218.
13. Kaminagakura, E., Andrade, C.R., Rangel, A.L. Coletta, R.D., Graner, E., Almeida, O.P., Vargas, P.A.: Sebaceous adenoma of oral cavity: Report of case and comparative proliferation study with sebaceous gland hyperplasia and Fordyce's granules. *Oral Dis.*, 2003; 9: 323-327.
14. Stout-Graham, M., Kainer, R.A., Whalen, L.R., Macy D.W.: Morphologic measurements of the external horizontal ear canal of dogs. *Am. J. Vet. Res.*, 1990; 51: 990-994.
15. Lezzi, G., Rubini, C., Fioroni, M., Piattelli, A.: Sebaceous adenoma of the cheek. *Oral Oncol.*, 2002; 38: 111-113.
16. Erer, H., Kıran, M.M.: Konya'da 1985-1992 yılları arasında köpeklerde görülen tümörler. *Selçuk Üniv. Vet. Fak. Derg.*, 1993; 9: 87-89.