

## Evaluation of Echocardiographic Examination Findings in Dogs with Mitral Valve Prolapse

Murat KİBAR

Department of Surgery, Faculty of Veterinary Medicine, Erciyes University, 38090 Kayseri - TURKEY

Melihat TOKER

Social Security Organization Ankara Training and Research Hospital, 06110 Ankara - TURKEY

Savaş ÖZTÜRK

Department of Surgery, Faculty of Veterinary Medicine, Kafkas University, 36040 Kars - TURKEY

Received: 17.09.2004

**Abstract:** The present study was performed to investigate the prevalence of mitral valve prolapse (MVP) in dogs, and to evaluate protrusive changes in the mitral valve by echocardiographic examination.

Thirty-five dogs were examined, including those observed clinically normal, and animals with suspected cardiac disease displaying lethargy, coughing, dyspnea, exercise intolerance, or syncope. The echocardiographic examination revealed 19 (54.2%) of the dogs to have MVP, whereas 16 (45.7%) had a normal mitral valve.

It was concluded that the degree of protrusion of the mitral valve in systole differs in individual dogs with mitral prolapse. MVP, determined to be widespread in dogs, can be reliably diagnosed by means of echocardiographic findings.

**Key Words:** Mitral valve prolapse, echocardiography, dog

### Mitral Kapak Prolapsusu Bulunan Köpeklerde Ekokardiografik Muayene Bulgularının Değerlendirilmesi

**Özet:** Sunulan bu çalışmada, köpeklerde mitral kapak prolapsusu'nun yayılışının araştırılması ve ekokardiografik muayeneler ile mitral kapakta meydana gelen çökme şeklindeki değişikliklerin değerlendirilmesi amaçlanmıştır.

Bu çalışmada, klinik olarak sağlıklı ve uyusukluk, öksürük, solunum güçlüğü veya bayılma belirtileri gösterdiği için kalp hastalığı olduğundan şüphelenilen toplam 35 köpek muayene edildi. Ekokardiografik muayene ile 19 (% 54,2) köpekte mitral kapak prolapsusu olduğu, 16 (% 45,7) köpekte ise mitral kapağın normal yapıda olduğu belirlendi.

Mitral prolapsus bulunan köpeklerde, sistol sırasında mitral kapaktaki prolapsus derecesinin bireysel farklılıklar içerdiği belirlendi. Sonuç olarak, köpeklerde yaygın olduğu belirlenen mitral kapak prolapsusunun güvenilir tanısının ekokardiografik muayeneler ile yapılabildiği görüldü.

**Anahtar Sözcükler:** Mitral kapak prolapsusu, ekokardiografi, köpek

### Introduction

Abnormal systolic protrusion of the mitral valve leaflets into the left atrium, namely, mitral valve prolapse (MVP), is a common cause of severe mitral regurgitation (MR) in dogs (1-3). MVP has been reported to have many causes but in the majority of cases it is a primary condition (primary MVP) characterized by a progressive myxomatous degeneration of the mitral valve leaflets and chordae tendineae. The disease typically emerges in adolescence but complications such as severe MR usually do not occur until middle age or senescence (1-4).

From pathological studies, it has long been known that most dogs develop myxomatous mitral valve disease with age. Recently, a number of studies, including many based on well-defined echocardiographic criteria for the diagnosis of MVP, have increased our understanding of this disease in the dog (5,6).

With regard to the pathogenesis of progressive myxomatous degeneration, an often advanced theory is that it is a response to repeated impacts to the leaflets. In support of that, the myxomatous changes begin along the line of apposition of the leaflets and progress in severity

with advancing age. A recent echocardiographic screening of 190 clinically healthy dachshunds disclosed a continuum of valvular changes, the degree of which correlated positively with age (7). This was true irrespective of whether the disease severity was assessed by measuring leaflet thickness, degree of leaflet protrusion or regurgitant jet size (8,9). Mitral valve disease appears to be approximately 10 times more common in dogs than in humans. Thus, marked changes are found at post-mortem examination in approximately 5%-7% of old people and more than 50% of old dogs (5,10). Despite the knowledge of predisposition in some dog breeds, practically all dogs are affected. For instance, 50% of Cavalier King Charles spaniels have a murmur due to MR by the age of 5-6 years, and at 10 years of age the prevalence of murmurs approaches 100% (2,11,12).

In dogs, males have approximately twice the risk of females of developing severe disease with old age (5,13). With regard to the influence of body weight, it has long been known that small dog breeds are affected more than large ones by myxomatous valvular disease (2,14). Several studies have documented that MVP is associated with a low anteroposterior chest diameter (15).

Echocardiographically, it is possible to assess several different manifestations of myxomatous mitral valve disease, including leaflet thickness, degree of leaflet protrusion and degree of MR (2,3). By combining several quantitative or semiquantitative measurements, rather than mainly focusing on whether or not abnormal leaflet protrusion is present, a better assessment of valve status will likely be obtained (16,17).

In dogs, the hinge points of the 2 leaflets have been used to define the position of the mitral annulus in all recent studies assessing the presence and severity of MVP (2,3,7,18,19).

By means of power Doppler examinations, E/A ratio (E: ventricular diastolic filling wave, A: atrial contraction filling wave) and mitral valve area (MVA) could be measured in dogs with suspected cardiac diseases (20-24).

The present study was performed to investigate the prevalence of MVP in dogs, and to evaluate protrusive changes in the mitral valve by means of echocardiographic examination.

## Materials and Methods

Thirty-five dogs were examined, including those observed clinically normal, and animals with suspected cardiac disease displaying lethargy, coughing, dyspnea, exercise intolerance, or syncope. Dogs referred from other veterinarians due to suspected heart disease, and dogs with a history or signs of heart failure were not included in the study. The experimental animals comprised 25 mixed-breed dogs, including 16 males and 19 females, 3 Anatolian shepherds, 3 German shepherds, 1 beagle, 1 cocker spaniel, 1 husky and 1 boxer. Their mean  $\pm$  SD body weight (BW) was  $19.8 \pm 8.39$  kg, and ranged from 7 to 38 kg, whereas their age was between 2 and 10 years.

All echocardiographic examinations were performed with a commercially available system (ESAOTE AU5, ESAOTE BIOMEDICA; Via Siffredi 58; 16 153 Genova, Italy) with a 3.5 to 5.0 MHz multifrequency sector transducer. Echocardiography was performed with dogs restrained in lateral recumbency without sedation, and the transducers were applied to the left parasternal border at the fourth or fifth intercostal space. The mitral valve was systematically imaged from left parasternal long axis 4-chamber views that we defined.

Four cross-sections were selected to afford a wide field of view of the mitral valve. We used 3 cardiac structures of the aorta and the ventral and dorsal papillary muscles to reproducibly image the cross-sections in each dog, and 4 cross-sections of the mitral valve were imaged, including the portion dorsal to the aorta scanned with the ventral and dorsal papillary muscle, and the mitral valve from the space between the 2 papillary muscles to the dorsal portion to the aorta. Using these 4 cross-sections, the mitral valve, excluding the ventral and dorsal commissures, could be imaged. Images were obtained at a speed of 116 frames/s with reduction of the sector angle, and they were temporarily recorded in a preinstalled cine-memory.

The mitral annulus was defined as the hinged points of the mitral cusps depicted, using images from the cine-memory. The mitral echo was traced on the screen before measurement of the mitral apparatus. The tracing proceeded from the ventral hinged point to the septal cusp and then the parietal cusp, and finally each hinged point was connected by a straight line, which was regarded as the mitral annular plane. Each cusp was

traced on the center of its echo with care not to mistake the chordae tendineae for the cusp. Even when the cusp itself was thick, the cusp was traced on the exact center of its echo, and the tip was determined. The reason for this step is that tracing of the cusp on the surface of the atrial side when the tip of the valve is thick tends to hamper identification of the tip of the cusp by various observers because of the round or complicated shapes of the mitral echo.

The end-systolic left atrial dimension (LAD) and diastolic aortic dimension (AoD) were measured from the left parasternal left ventricular long-axis view, using 2-D echocardiography. The LAD was measured from the leading edge of the dorsal aortic root to the leading edge of the dorsal left atrial wall at the level of the aortic cusp. The AoD was assessed as the distance between each base of the aortic cusp. The LAD-AoD ratio (LA/Ao) was calculated as an index of the LAD. The left ventricular end-diastolic dimension (LVEDD) was measured from the left parasternal left ventricular long-axis view by M-mode echocardiography, and the LVEDD-to-BW ratio (LVEDD/BW) was calculated as an index of the left ventricular dimension.

Statistical analyses of data were performed by SPSS 10.0 version for Microsoft and an independent-samples t test was used. All data were expressed as means  $\pm$  SEM.

## Results

The echocardiographic examination performed in this study revealed 19 (54.2%) of the dogs to have MVP, whereas 16 (45.7%) had a normal mitral valve. Two dogs that gave a murmur sound and 7 dogs with any pathological sounds were supposed to have MVP evidenced by the echocardiographic examination. In addition, 10 dogs were diagnosed with MVP coincidentally.

In clinically normal dogs, the mitral valve could be clearly imaged on 2-D echocardiogram. In mid- and especially late systole, it was difficult to accurately determine the mitral annulus and coaptation point of the mitral valve due to movement of the mitral valve toward the apex with contraction of the left ventricle. In clinically normal dogs, the tip of the mitral valve coapted on the ventricular side of the mitral annular plane (Figure 1).

The mitral valve protruded toward the left atrium in the dogs with MR. In most dogs, the septal cusp clearly had more severe mitral protrusion than the parietal cusp under observation by 2-D echocardiography (Figure 2). By color Doppler echocardiography, mitral regurgitant jet was detected, which is directed from the septal cusp toward the dorsal wall of the left atrium. Regurgitant jet in the left atrium was confirmed in 2 dogs by color Doppler echocardiography (Figure 3).

Heart rate in dogs with MVP was not significantly increased, compared with that in clinically normal dogs ( $131 \pm 45$  beats/min vs.  $132 \pm 45$  beats/min;  $P > 0.05$ ). The dogs with MVP did not have significantly different LAD/AoD and LVEDD/BW, compared with those in clinically normal dogs ( $1.15 \pm 0.19$  vs.  $1.05 \pm 0.93$ , respectively, for LAD/AoD, and  $2.27 \pm 1.01$  mm/kg vs.  $2.62 \pm 1.37$  mm/kg, respectively, for LVEDD/BW; both  $P > 0.05$ ,  $n = 35$ ). E/A ratio and MVA values did not significantly differ in the 2 groups (Table).

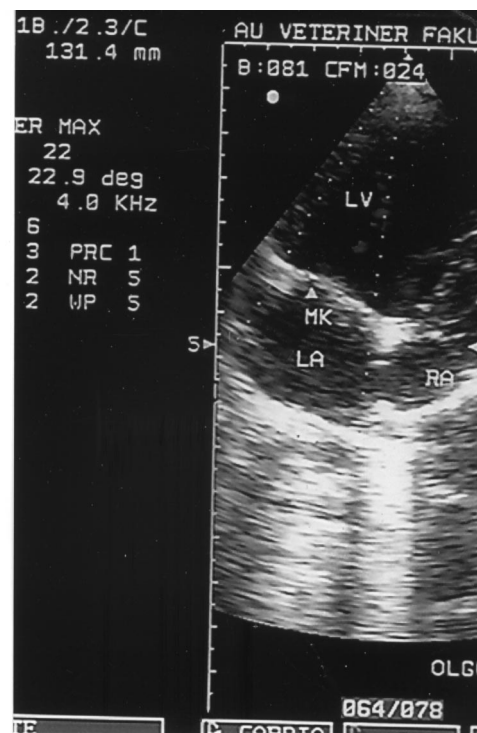


Figure 1. Criteria used to diagnose normal mitral valve in dogs using the left parasternal long axis 4-chamber view. Echocardiogram showing the normal mitral valve in systole (Case no: 26). The tip of the mitral valve coapted on the ventricular side of the mitral annular plane (white arrow-head) (LV: Left ventricle, LA: Left atrium, RA: Right atrium).

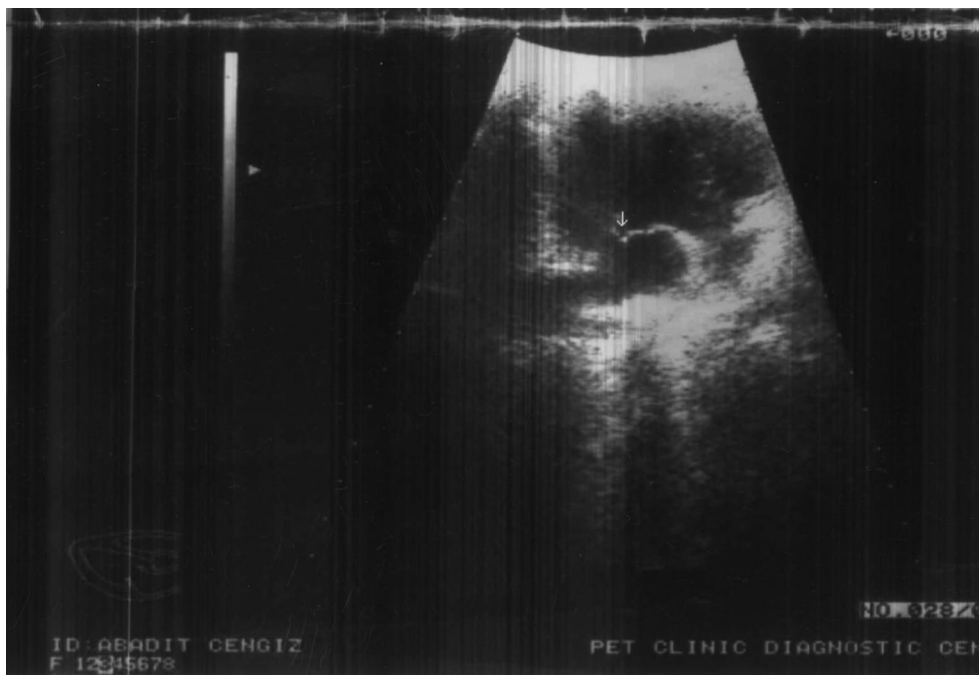


Figure 2. Criteria used to diagnose MVP in dogs using the left parasternal long axis 4-chamber view. Echocardiogram showing the mitral valve prolapse in systole (Case no: 34). The septal cusp clearly had more severe mitral protrusion than the parietal cusp (white arrow).

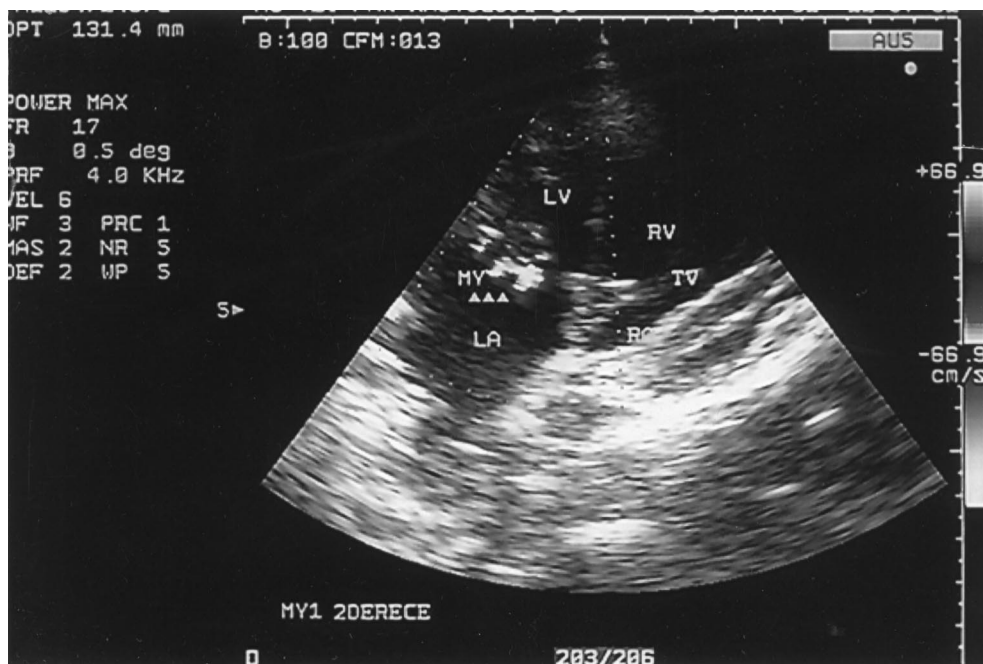


Figure 3. Mitral valve regurgitation caused by MVP in a dog (Case no: 13). This image demonstrates a relatively wide origin jet that crosses the mitral valve and enters the left atrium (white arrow-heads), (LV: Left ventricle, LA: Left atrium, MV: Mitral valve, RA: Right atrium, TV: Tricuspid valve).

Table. Comparison of different values in dogs with and without mitral valve prolapse. MVP: Mitral valve prolapse, HRT: Heart rate, LA/Ao: Left atrium diameter/Aorta diameter, E/A: E wave/A wave, MVA: Mitral valve area.

	MVP (+)	MVP (-)	P
HRT (beats/min)	132.55 ± 37.55	131.90 ± 45.16	P > 0.05*
LA/Ao	1.05 ± 0.09	1.15 ± 0.19	P > 0.05
LVEDD/BW	2.62 ± 1.37	2.27 ± 1.01	P > 0.05
E/A	1.30 ± 0.19	1.24 ± 0.19	P > 0.05
MVA (cm <sup>2</sup> )	4.77 ± 1.63	4.21 ± 1.26	P > 0.05

\*P > 0.05: not significant  
n = 35

## Discussion

MR in dogs is principally attributable to degenerative changes in the mitral apparatus, but the change has not been sufficiently assessed clinically. Previous reports indicate that nodular thickening and rupture of the chordae tendineae can be observed in dogs with MR by the use of M-mode or 2-D echocardiography, but application of these techniques has long been limited to diagnostic purposes for this valvular disease, probably because it has been difficult to qualify the mitral apparatus in motion with rapid heart rate (2,3,7,16,17). More recently, cine-memory has been used in echocardiography, providing 2-D mode images with faster frame rates, and it has become possible to clinically observe the mitral valve in detail. Although the mitral changes can be described as either gross thickening or protrusive lesions, only the latter changes were assessed in this study. The thickening lesions were not evaluated owing to some difficulties in the assessment of their complex shape by echocardiography, and because, as a result of the insertion of many chordae tendineae on the edge and ventricular surface of the mitral cusp, it may often be difficult to distinguish thickening lesions from such attachments of the chordae tendineae, especially in mild mitral lesions.

The 2-D echocardiographic assessment of lesions of the mitral valve requires observation of a broad area of the valve, using a combination of multiple images (2,3,21). To clearly recognize the spatial locations of the cross-sections obtained and to standardize the 4 cross-sectional images of the mitral valve, we used 3 cardiac structures (i.e. the aorta, and ventral and dorsal papillary

muscles). Using these cross-sections, it was possible to reproducibly image and assess the mitral valve excluding the commissure. The mitral lesions are frequently located in the dorsal half of the septal cusp, the dorsomedial commissural scallop, and the middle scallop (6,10,18,19). Therefore, these cross-sections seem to image the parts of the mitral valve that are most frequently affected by degeneration and may afford the opportunity to assess changes in the mitral apparatus in many instances when no major lesion is present in the commissure.

During the isovolumic systolic phase, the condition of the left ventricle is coincident with the time immediately before the initiation of the ejection phase, and cardiac movement seems to pause (1,2,4,5,8). Thus, at that time, it is possible to clearly identify the mitral cusp and mitral annulus. On the other hand, it was difficult to accurately determine the location of the mitral annulus and coaptation point at mid and especially late systole attributable to cardiac movement. Although maximal protrusion must be obtained at the time after mid-systole, we considered that this phase would not be appropriate for the method of assessment of the mitral echo in which the mitral annulus is regarded as the reference structure.

In MVP, the valve is displaced, extending into the left atrium often accompanied by mid-systolic click or late systolic murmur. Echocardiography has an important role in the diagnosis of valvular disease (13-17). The most common echocardiographic finding was abrupt superior displacement of one or both mitral leaflets from the normal position or relation in mid-systole, and a secondary finding was pansystolic prolapse of the leaflet.



The normal relationship between the mitral filling waves changes as one moves the sample volume closer to the mitral annulus and into the left atrium. This will yield a time-velocity spectrum with a larger A wave than E wave, and may be useful if one is timing the duration of early and late cardiac filling (11,12,20,21). We measured E/A ratio and MVA in dogs with and without MVP. We

determined the difference between values in the 2 groups to be non-significant ( $P > 0.05$ ).

It was concluded that the degree of protrusion of the mitral valve in systole differs in individual dogs with mitral prolapse. MVP determined to be widespread in dogs, can be reliably diagnosed by means of echocardiographic findings.

## References

1. Devereux, R.B.: Recent developments in the diagnosis and management of mitral valve prolapse. *Curr. Opin. Cardiol.*, 1995; 10: 107-116.
2. Pedersen, H.D., Lorentzen, K.A., Kristensen, B.Ø.: Echocardiographic mitral valve prolapse in Cavalier King Charles spaniels: epidemiology and prognostic significance for regurgitation. *Vet. Rec.*, 1999; 144: 315-320.
3. Nakayama, T., Wakao, Y., Nemoto, H., Uechi, M., Kageyama, T., Muto, M., Takahashi, M.: Mitral valve protrusion assessed by use of B-mode echocardiography in dogs with mitral regurgitation. *Am. J. Vet. Res.*, 1996; 57: 791-797.
4. Tarnow, I., Olsen, L.H., Jensen, M.B., Pedersen, K.M., Pedersen, H.D.: Determinants of weak femoral artery pulse in dogs with mitral valve prolapse. *Res. Vet. Sci.*, 2004; 76: 113-120.
5. Pedersen, H.D., Haggström, J.: Mitral valve prolapse in the dog: a model of mitral valve prolapse in man. *Cardiovasc. Res.*, 2000; 47: 234-243.
6. Kogure, K.: Pathology of chronic mitral valvular disease in the dog. *Jpn. J. Vet. Sci.*, 1980; 42: 323-335.
7. Olsen, L.H., Fredholm, M., Pedersen, H.D.: Epidemiology and inheritance of mitral valve prolapse in Dachshunds. *J. Vet. Intern. Med.*, 1999; 13: 448-456.
8. Fukuda, N., Oki, T., Iuchi, A., Tabata, T., Manabe, K., Kageji, Y., Sasaki, M., Yamada, H., Ito, S.: Predisposing factors for severe mitral regurgitation in idiopathic mitral valve prolapse. *Am. J. Cardiol.*, 1995; 76: 503-507.
9. Zuppiroli, A., Rinaldi, M., Kramer-Fox, R., Favilli, S., Roman, M.J., Devereux, R.B.: Natural history of mitral valve prolapse. *Am. J. Cardiol.*, 1995; 75: 1028-1032.
10. Pomerance, A.: Cardiac pathology in the elderly. *Cardiovasc. Clin.*, 1982; 12: 9-54.
11. Darke, P.G.G.: Valvular incompetence in Cavalier King Charles spaniels. *Vet. Rec.*, 1987; 120: 365-366.
12. Haggström, J., Hansson, K., Kvarn, C., Swenson, L.: Chronic valvular disease in the Cavalier King Charles spaniels in Sweden. *Vet. Rec.*, 1992; 131: 549-553.
13. Swenson, L., Hagsström, J., Kvarn, C., Juneja, R.K.: Relationship between parental cardiac status in Cavalier King Charles spaniels and prevalence and severity of chronic valvular disease in offsprings. *J. Am. Vet. Med. Assoc.*, 1996; 208: 2009-2012.
14. Thrusfield, M.V., Aitken, C.G.G., Darke, P.G.G.: Observations on breed and sex in relation to canine heart valve incompetence. *J. Small Anim. Pract.*, 1985; 26: 709-717.
15. Schutte, S.E., Gaffney, F.A., Blend, L., Blomqvist, C.G.: Distinctive anthropometric characteristics of women with mitral valve prolapse. *Am. J. Med.*, 1981; 71: 533-538.
16. Hickey, A.J., Wilcken, D.E.L.: Age and clinical profile of idiopathic mitral valve prolapse. *Br. Heart J.*, 1984; 55: 582-586.
17. Devereux, R.B., Kamer-Fox, R., Shear, M.K., Kligfield, P., Pini, R., Savage, D.D.: Diagnosis and classification of severity of mitral valve prolapse: methodologic, biologic and prognostic considerations. *Am. Heart J.*, 1987; 113: 1265-1280.
18. Pedersen, H.D., Kristensen, B.Ø., Lorentzen, K.A., Koch, J., Jensen, A.L., Flagstad, A.: Mitral valve prolapse in 3-year-old healthy Cavalier King Charles spaniels: an echocardiographic study. *Can. J. Vet. Res.*, 1995; 59: 294-298.
19. Pedersen, H.D., Lorentzen, K.A., Kristensen, B.Ø.: Observer variation in the two-dimensional echocardiographic evaluation of mitral valve prolapse in dogs. *Vet. Radiol. Ultrasound.*, 1996; 37: 367-372.
20. Bonagura, J.D., Miller, M.W., Darke, P.G.G.: Doppler echocardiography. I. Pulsed-wave and continuous-wave examinations. *Vet. Clin. North Am. Small Anim. Pract.*, 1998; 28: 1325-1359.
21. Kibar, M.: Doppler echocardiographic examination of atrioventricular valves in dogs. PhD Dissertation. University of Ankara, Ankara, Turkey. 2002.
22. Schober, K.E., Fuentes, V.L.: Effects of age, body weight, and heart rate on transmitral and pulmonary venous flow in clinically normal dogs. *Am. J. Vet. Res.*, 2001; 62: 1447-1454.
23. Rivas-Gotz, C., Khoury, D.S., Manolios, M., Rao, L., Kopelen, H.A., Nagueh, S.F.: Time interval between onset of mitral inflow and onset of early diastolic velocity by tissue doppler: a novel index of left ventricular relaxation: experimental studies and clinical application. *J. Am. Coll. Cardiol.*, 2003; 42: 1463-1470.
24. Choi, H., Lee, K., Lee, H., Lee, Y., Chang, D., Eom, K., Youn, H., Choi, M., Yoon, J.: Quantification of mitral regurgitation using proximal isovelocity surface area method in dogs. *J. Vet. Sci.*, 2004; 5: 163-171.