

## Comparison of Electrocautery and Quantum Energy Surgical Devices in Experimental Partial Hepatectomies

Cem PERK<sup>1\*</sup>, Zihni MUTLU<sup>1</sup>, Aydın GÜREL<sup>2</sup>, Damla HAKTANIR<sup>2</sup>

<sup>1</sup>Department of Surgery, Faculty of Veterinary Medicine, İstanbul University, Avclar 34320, İstanbul - TURKEY

\*E-mail: perkcem@istanbul.edu.tr

<sup>2</sup>Department of Pathology, Faculty of Veterinary Medicine, İstanbul University, Avclar 34320, İstanbul - TURKEY

Received: 22.02.2005

**Abstract:** The quantum energy surgical device (QESD) is a new medical instrument that uses kinetic energy to heat the atoms of argon gas to a high temperature and to apply them on tissues. Unlike other devices operating on the principle of argon plasma technology, the QESD can be used in tissue vaporisation, resection, coagulation and superficial sterilisation of tissues. This study aimed to compare the amount of bleeding, duration of liver incision, duration of the whole operation and histopathological changes occurring on the surface of the incision in partial hepatectomies performed by QESD and bipolar electrocautery. The study was carried out on 16 rabbits, and showed that the QESD caused less bleeding and made it possible to perform the operations in a shorter period of time. Histopathologic examination revealed that in both the groups of rabbits operated on either by QESD or bipolar electrocautery, various changes occurred on the surface of the incision due to thermal trauma. However, the former technique was superior to the latter in terms of the efficiency of haemostasis.

**Key Words:** Quantum energy surgical device, argon plasma scalpel, electrocautery, hepatectomy, rabbit.

### Deneyisel Parsiyel Hepatektomilerde Elektrokoter ve QESD (Quantum Energy Surgical Device) Cihazlarının Karşılaştırılması

**Özet:** Yeni bir medikal enstruman olan QESD (Quantum energy surgical device, kuantum enerji operasyon cihazı), kinetik enerji verilerek yüksek sıcaklığa çıkarılmış olan argon gazı atomlarının dokulara uygulanması prensibi üzerine tasarlanmıştır. Diğer argon plazma teknolojisiyle çalışan cihazlardan farklı olan QESD ile doku buharlaştırma, rezeksiyon, koagulasyon ve dokuların yüzeysel sterilizasyonu yapılabilmektedir. Bu çalışmada QESD ve bipolar elektrokoter ile yapılan parsiyel hepatektomilerde kanama miktarı, karaciğer ensiyoz süresi, toplam operasyon süresi ve kesit yüzeyindeki histopatolojik değişimler incelenmiştir. Toplam 16 tavşanda gerçekleştirilen bu deneysel çalışma sonucunda, QESD ile yapılan uygulamalarda kanamanın çok daha az olduğu ve operatif prosedürlerin daha kısa sürede tamamlandığı saptanmıştır. Histopatolojik incelemelerde kesit yüzeylerinde her iki grupta termal travmaya ilişkin farklı değişiklikler saptanmakla birlikte, hemostaz etkinliği yönünden QESD grubunun üstünlüğü ortaya konulmuştur.

**Anahtar Sözcükler:** Kuantum enerji operasyon cihazı, argon plazma scalpel, elektrokoter, hepatektomi, tavşan.

### Introduction

Electrocauteries have long been used as cutters or coagulants in various surgical operations. These devices are either monopolar or bipolar in type and work on the principle that alternative current is applied to a heat-resistant and semi-conductive metal like tungsten. When the metal heats up, it cauterises tissues and serves as a coagulant. When used to make incisions, a bipolar electrocautery carbonises a considerable amount of tissue. Besides, there is the undesirable effect of bleeding, which has to be stopped by using the tip of the cautery that coagulates blood (1,2).

Designed to serve in medicine, the quantum energy surgical device (QESD) is a combination of plasma physics and electronics. It is based on plasma technology, and was developed after laser technology. In various studies carried out by using the prototypes of plasma scalpels, it has been reported that this device was superior to bistouries or electrocauteries in terms of the amount of bleeding, tissue damage and duration of healing (3-5).

Nechai et al. (6) reported that, in stomach, intestine and liver operations, the plasma scalpel ensured safer haemostasis compared to an electrobistoury, ultrasonic scalpel or a laser scalpel.

Kabanov et al. (7) stated that, the plasma scalpel was effective in treating pleural empyema, as it ensured sufficient haemostasis, aerostasis and regional sterilisation.

In surgery of the liver and gallbladder, the plasma scalpel was found to decrease bleeding and bile leakage to a considerable degree (8,9).

Pleshkov et al. (10) reported that, in stomach and duodenum transections performed by using a plasma scalpel, the wound on the surface of incision was aseptic and haemostatic, and thermal trauma was not deeper than 3-4 mm.

It was also reported by other authors that operations performed by using this device took a shorter time to complete than those performed by conventional methods (11,12).

Developed in the KOSGEB Laboratories of the Istanbul Technical University in 2000, the QESD operates on the principle explained below. The atoms of argon gas in the device are kinetically energised, heated up to very high degrees and applied to tissues through a mechanism that controls its energy level. The atoms of argon gas are sprayed through the tiny channels on the tip of the application mechanism, or rather the application pen. The ionised argon atoms can reach a temperature of 10,000-20,000 °C. The device can perform different functions (superficial sterilisation of tissues, coagulation, resection or vaporisation of tissues) at different energy levels (13-15).

Surgery of the liver is complicated by the fact that hepatic tissue is friable. The most common and serious complication of hepatic surgery is haemorrhage (16).

This study therefore aimed to examine the use of the QESD and electrocautery in partial hepatectomy operations, and compare the efficiency of these two devices in terms of the amount of bleeding, duration of liver incision, duration of the whole operation and histopathologic changes.

## Materials and Methods

This study was carried out in the Istanbul University, Veterinary Faculty, Surgery Department. Sixteen rabbits (*Oryctolagus cuniculus*) of the same age and weight were used in this study. Official permission was granted by the Department of Surgery to carry out an experimental

study on rabbits. The rabbits were divided into 2 groups of equal numbers. Eight rabbits formed the electrocautery group and the other 8 formed the QESD group. Partial hepatectomy was performed on 1/3 of the left lateral lobe of the liver of each rabbit.

In the anaesthetic protocol of the cases, 5 mg/kg xylazine (Rompun 2%, Bayer) and 35 mg/kg ketamine (Ketalar, Parke Davis) i.m. were used.

The liver was opened by median laparotomy in all the operations, performed under aseptic conditions.

In order to determine the amount of bleeding, all the sterile gauze in the operation kit was weighed on precision scales. The measurement was repeated following the operation. The difference was recorded as the amount of bleeding.

The period between the initiation of the operation (with the first incision made on the skin) and its completion was taken as the total duration of the operation. Time spent for the removal of 1/3 of the liver was taken as the total duration of liver incision. A chronometer was used to measure the time. The argon plasma device used in this study was developed in the KOSGEB Research Laboratories of Istanbul Technical University (patent filed in United States Patent and Trademark Office on October 12, 2000 with serial number: 09/689.216) (Figures 1 and 2). The device, called the QESD, was used to resect liver tissue from a distance of 0.5 cm (non-contact technique). Following resection, there was almost no bleeding in the incision area of the liver (Figure 3).

In the second group of rabbits, we used Martin-Elektrotom 60 (Tuttlingen-Germany), which is a bipolar electrocautery. In this group, liver tissues were resected by means of the tip of the device used for cutting. Following resection, attempts were made to stop bleeding by operating the device in coagulation mode. However, our efforts were in vain, and the incised section had to be sutured.

Following the operations, 20 mg/kg of penicillin G benzathine (Penedur-LA, Wyeth) was administered intramuscularly once every 3 days to each rabbit. The sutures of both groups of rabbits that had recovered per primam were removed 1 week after the operation. The rabbits were followed up for 6 months and were observed to survive healthily.




Figure 1. View of the control panel of the QESD.




Figure 2. General view of the QESD.

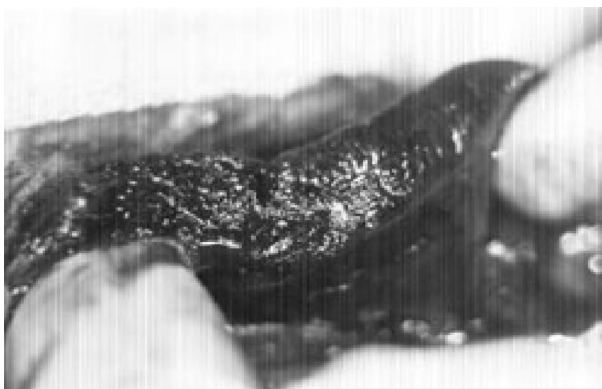

Figure 3. Macroscopic view of the liver resected by the QESD.

As the pathological examinations were carried out on the cross-sectional profile of the resected part of livers only, none of the animals were sacrificed.

1/3 of each liver removed during the operations was fixed in a 10% formal saline solution. Following routine processes, the preparations were stained with Haematoxylin-Eosin and examined under a light microscope. An ocular micrometer was used to measure the thickness of the necrosed tissues and the area where bleeding occurred. Ten different measurements were obtained, and mean values were given in millimetres.

Data were compared by nonparametric test using the Mann-Whitney test. Probabilities of 0.05 or less were considered statistically significant.

## Results

The results achieved in this study are shown in Figure 4 and Table. In the QESD group, bleeding was almost half that in the electrocautery group.

Following partial hepatectomy, the incision surface had to be sutured, for bleeding in this area could not be stopped by electrocautery. In the QESD group, however, bleeding was rather limited and, without the need for sutures, could easily be stopped by using the device at a low energy level.

The hepatectomy procedure was successfully completed in about 45 s by using the QESD. The duration of the same procedure was 67 s when the electrocautery was used. The difference was statistically significant.

In the QESD group, the whole operation took approximately 30 min, which was 6.5 min less than that in the electrocautery group. The difference was statistically significant.

Overall, the operations caused considerably less bleeding and took less time to complete in the QESD group. The QESD made non-contact incisions and cauterisations possible, which are normally not easy procedures as far as soft tissues are concerned.

The cross-sections of the liver tissues removed during hepatectomy were histopathologically examined and compared. In the QESD group, there was a cyst-like formation on the cross-sections of the liver tissues, with an average thickness of 0.17 mm. Caused by the

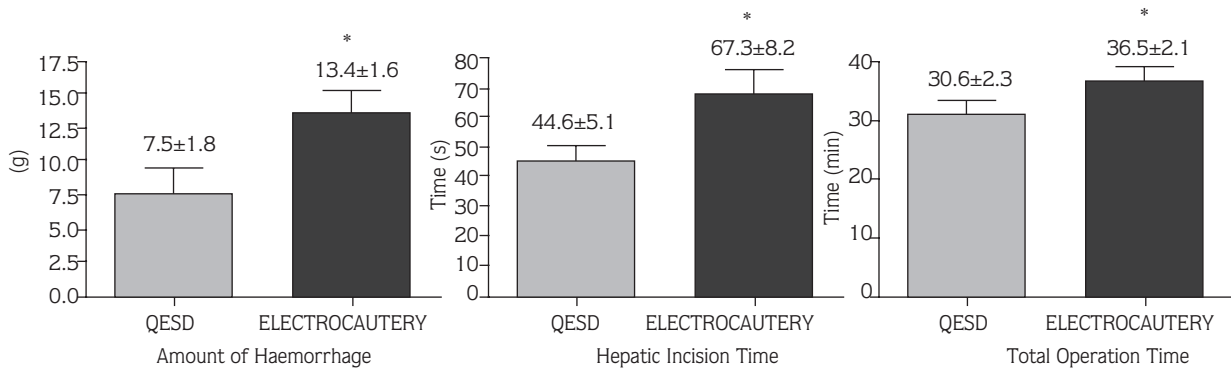


Figure 4. Comparison of amount of haemorrhage, hepatic incision and total operation time in QESD and electrocautery groups. (Data are shown as mean + S.D. and \*P ≤ 0.05 compared to QESD groups).

Table. Comparison of histopathological results in QESD and electrocautery groups. (Data are shown as mean + S.D. and \*\*\*P < 0.001 compared to QESD groups).

QESD		ELECTROCAUTERY	
Cystic area (mm):	0.17 +/- 0.01	Haemorrhagic area (mm)	0.19 +/- 0.03
Coagulated area (mm):	0.11 +/- 0.06	Coagulated area (mm):	0.07 +/- 0.01
Total (mm):	0.28 +/- 0.07	Total (mm):	0.26 +/- 0.04***

vaporisation of tissues, this formation was oval or circular and had well-defined margins. Below this area was a layer with an average thickness of 0.11 mm. This layer was characterised by coagulated cytoplasm, pyknotic nuclei and dead parenchymal cells. In the electrocautery group, a highly haemorrhagic area with an average thickness of 0.19 mm was observed on the cross-sections of the liver tissues. Below was an area with an average thickness of 0.07 mm, made up of parenchymal cells whose cytoplasm was coagulated and nuclei pyknotic. The difference between the above values, measured by an ocular micrometer, were not of any statistical significance but total area was. Histopathological slides of the QESD and electrocautery groups are shown in Figures 5 and 6.

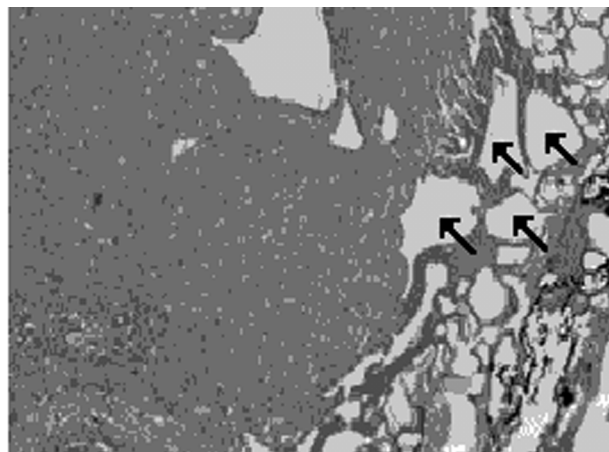


Figure 5. Cyst-like formations (↑) on the cross-sectional surface observed following the use of the QESD device to resect the liver. H.E. X10.

**Discussion**

Incision and coagulation are essential surgical procedures, particularly in soft tissue surgery. Over the years, various kinds of electrocautery have been used to accomplish incision and coagulation. With the advances in

technology, new devices have been introduced to accomplish the above procedures more rapidly, safely and effectively. Among these devices are those that work according to the principle of argon plasma technology.



Figure 6. Noticeable areas of bleeding (↑) following liver resection with the electrocautery. H.E. X10.

In operations in which an electrocautery is used, it takes a longer time to complete an incision or coagulation, and there is a greater amount of necrosed tissue. This has been shown by Link et al. (3,4) and Glover et al. (5), the first authors to develop device operating according to argon plasma technology. However, these were prototypes with limited use. Following the attempts of the above authors, Nechai et al. (6), Kabanov et al. (7), Arkhipov (11), Pleshkov et al. (10) and Bergler et al. (12) performed a number of soft tissue operations, using argon plasma devices which they reported were superior to the classic methods. The QESD, used in this study, is quite different from those mentioned above in that its energy does not come from electrons or electrical currents, but from atoms. Unlike other devices of its kind, the QESD does not rely on thermal energy, but on energy that is created by the plasma medium. Thus, per atom of the gas, the energy yield in QESD is 50-100 times greater than that in other devices working on the same principle. The device has 4 energy levels, which can be used in accomplishing the below-mentioned procedures: Level 1 (minimum) - superficial sterilisation of tissues; level 2 (low) - coagulation; level 3 (moderate) - resection of tissues, and level 4 (maximum) - vaporisation of tissues. This study therefore aimed to examine and compare the use of the

QESD and electrocautery in the procedures of incision and coagulation as applied in soft tissue surgery.

The findings obtained in this study revealed that the amount of bleeding caused by the QESD was 50% less than that caused by the electrocautery. This is in accordance with the findings of other authors (6,7,10). Another advantage of the QESD is that it enables haemostasis during the resection of tissues. Unlike electrocauterries, it eliminates the need for holding the bleeding area with a pair of pliers and then cauterising it, for the device is not in direct contact with tissues (non-contact technique). This is how it enables rapid incision and haemostasis, and thereby causing less bleeding.

Compared to the electrocautery, with the QESD, both the duration of liver incision and that of the whole operation were shorter. This finding is similar to those of Arkhipov (11) and Bergler et al. (12).

Histopathological examination of the hepatectomised tissues revealed no statistically significant differences but a comparison of total area did. As far as thermal trauma is concerned, the presence of a haemorrhagic area was evident on the cross-sections removed by the electrocautery. There was a cyst-like formation on the same area on the cross-sections removed by the QESD. These structures are formed by the cells of dead tissues which have either liquefied on the cross section or have stuck together to become a compact mass. This is a natural occurrence due to very high temperature. Thermal trauma caused by this device had a total thickness of 0.28 mm (0.17 mm of cyst-like formation + 0.11 mm of necrosed parenchymal cells). This finding is in accordance with Nechai et al. (6), who reported an area of 0.2-0.3 mm affected by the plasma scalpel.

It was determined in this study that the QESD ensured shorter operations with less bleeding. Although histopathological examinations revealed different changes in the tissues due to thermal trauma, the QESD was still superior to the electrocautery in terms of haemostatic efficiency.

In conclusion, the authors would like to emphasise that QESD makes it possible to perform soft tissue operations rapidly, safely and efficiently.

## References

1. Toombs, J.P., Bauer, M.S.: Basic operative techniques. In: Slatter, D. Ed. Textbook of Small Animal Surgery. 2nd ed., Vol. 1, W.B. Saunders Co. Philadelphia. 168-191, 1993.
2. Parker, R.B.: Electrosurgery and laser surgery. In: Bojrab, M.J. Ed. Current Techniques in Small Animal Surgery. 4th ed., Williams & Wilkins Co. Baltimore. 41-44, 1998.

3. Link, W.J., Zook, E.G., Glover, J.L.: Plasma scalpel excision of burns. An experimental study. *Plast. Recons. Surg.*, 1975; 55: 647-663.
4. Link, W.J., Incropera, F.P., Glover, J.L.: A plasma scalpel: Comparison of tissue damage and wound healing with electrosurgical and steel scalpels. *Arch. Surg.*, 1976; 111: 392-397.
5. Glover, J.L., Bendick, P.L., Link, W.J., Plunkett, R.J.: The plasma scalpel: A new thermal knife. *Lasers Surg. Med.*, 1982; 2: 101-106.
6. Nechai, A.I., Kostyuk, G.A., Dzhaiani, S.V., Iushkin, A.S., Kalashnikov, S.A.: Characteristics of the healing of wounds of the stomach, intestines and liver after exposure to the plasma scalpel. *Vestn. Khir., Im II Grek.*, 1989; 143: 7-12.
7. Kabanov, A.N., Kozlov, K.K., Kotov, I.I., Sitnikova, V.M., Gal'perin, A.M.: Surgical tactics in pleural empyema with regard to the use of a carbon dioxide laser and argon plasma. *Grud. Serdechnososudistaia. Khir.*, 1992; 11-12: 40-44.
8. Savel'ev, V.S., Filimonov, M.I., Vasil'ev, V.E., Stupin, I.V., Alekseenkov, V.I., Trofimov, V.I.: Potential uses of plasma scalpel in liver and gallbladder surgery. *Khirurgiia*, 1994; 4: 3-6.
9. Kasum'ian, S.A., Novikov, I.G., Varchuk, O.D., Bazhenov, S.M., Zaitseva, V.V.: Application of plasma scalpel for cholecystectomy. *Khirurgiia*, 1997; 9: 30-32.
10. Pleshkov, V.G., Afanas'ev, V.N., Babichev, A.V.: Use of plasma scalpel and one-layer suture in resection of the stomach. *Khirurgiia*, 1998; 11: 27-29.
11. Arkhipov, V.F.: The characteristics of the early postoperative period in patients with organic hyperinsulinism. *Vestn. Khir. Im. I I. Grek.*, 1996; 155: 29-32.
12. Bergler, W., Huber, K., Hammerschmitt, N., Hormann, K.: Tonsillectomy with argon plasma coagulation (APC): Evaluation of pain and hemorrhage. *Laryngoscope*, 2001; 111: 1423-1429.
13. Çelik, S.: The determination of antioxidant enzyme levels and radical of free oxygen on blood and liver of rabbits that are operated with APS. Master Dissertation. Dumlupınar University, Department of Molecular Biology. Kütahya, Turkey. 2001.
14. Elmacı, İ., Kurtkaya, Ö., Ercan, F., Tuncer, N., Bakırcı, N., Şan, T., Sav, A., Pamir, M.N., Tanrısever, E.: The effects of quantum energy surgical device and of bipolar coagulation: A comparative experimental study. *Acta Neurochir.*, 2002; 144: 377-383.
15. Perk, C., Mutlu, Z., Gürel, A., Haktanır, D.: Comparison of electrocautery and APS devices in experimental hepatectomies. 8th National Veterinary Surgery Congress. Van. 2002; 63-64.
16. Fossum, T.W.: Surgery of the liver. In: Fossum, T.W. Ed. *Small Animal Surgery*. 2nd ed. Mosby. St. Louis, Missouri. 452-457, 2002.