

Immunohistochemical Diagnosis of Aspergillosis in Adult Turkeys

Enver BEYTUT*

Department of Pathology, Faculty of Veterinary Medicine, Kafkas University, Kars - TURKEY

Received: 16.01.2006

Abstract: The aim of the present study was to apply immunohistochemistry, using a commercially available monoclonal antibody, for the diagnosis of aspergillosis in adult turkeys. Eight adult turkeys were studied. The lungs revealed grossly a few yellowish-white granulomas. Histopathologically, the granulomas were distributed in the pulmonary parenchyma or occasionally located around the airways. A few fungal hyphae were detected within the necrotic debris of the granulomas in the lungs using routine fungal stains. Immunohistochemical staining performed on lung sections from all of the turkeys disclosed fungal hyphae and their fragments clearly within the necrotic debris and within the cytoplasm of macrophages and multinucleated foreign-body giant cells in the granulomas. In conclusion, even though fungal elements within the granulomas with histologic characteristics are indicative of the disease, immunohistochemistry should be applied to ensure a reliable diagnosis of aspergillosis in adult turkeys, and to differentiate it from other filamentous mycelia.

Key Words: Turkey, aspergillosis, immunohistochemistry

Erişkin Hindilerde Asperillozisin İmmunohistokimyasal Tanısı

Özet: Bu çalışma ile, ticari olarak mevcut olan monoklonal antikorlar kullanılarak erişkin hindilerde asperillozisin immunohistokimyasal tanısı amaçlandı. Çalışma materyalini 8 adet erişkin hindi oluşturdu. Nekropside, akciğerlerde az sayıda sarımsı-beyaz granülomlar gözlemlendi. Histopatolojik olarak, granülomların akciğer parenkimine yayıldığı, bazı olgularda ise hava yolları çevresinde yerleştikleri saptandı. Rutin mantar boyaları ile, akciğerlerde granülomların merkezinde az sayıda branşlı hifaların bulunduğu görüldü. Akciğer kesitlerine uygulanan immun boyamada granülomların merkezindeki nekrotik doku ile makrofajlar ve çok çekirdekli yabancı cisim dev hücrelerinin sitoplazmalarında hifalar ve parçaları tespit edildi. Sonuç olarak, granülomlarda karakteristik özellikleri ile mantara ait yapılar hastalığın göstergesi olarak kabul edilmekle birlikte, erişkin hindilerde asperillozisin güvenilir tanısı ve *Aspergillus* türlerinin benzer filamentöz etkenlerden ayırt edilmesi için immunohistokimyasal yöntemlerin kullanılmasının uygun olacağı kanaatine varıldı.

Anahtar Sözcükler: Hindi, asperillozis, immunohistokimya

Introduction

Infection by *Aspergillus* species is a growing problem in both birds and mammals, including humans (1). Since the symptoms and gross lesions of avian mycoses are fairly nonspecific, most cases remain undiagnosed, or are misdiagnosed as neoplasia or inflammation of uncertain aetiology (2-4). Consequently, in the absence of specific findings, most mycotic infections, including aspergillosis, are not recognised until the histopathological evaluation is completed as part of a postmortem examination (3,5-7).

Although infection caused by *Aspergillus* species may be disclosed by routine histopathology, in some cases

where fungi remain unstained or where only a few fungal elements are present histopathological identification may be difficult. Thus, an accurate identification of fungi by using routine histopathology is not always possible, particularly in relation to the differentiation of *Aspergillus* species from other fungi (3,4,8,9). Additionally, a failure to find typical diagnostic elements, or misdiagnosis, may occur because of morphological similarities among the tissue forms of several fungal genera (1,5,6). For these reasons, during recent years a number of immunohistochemical techniques have been developed to improve the identification of fungi in tissues and it has

* E-mail: enverbeytut@hotmail.com

been suggested that a presumptive diagnosis of aspergillosis in birds should ideally be confirmed by immunological techniques (1-3,9-11).

To date, aspergillosis has commonly been reported to cause acute and severe infections with high mortality in various young avian species. Our literature review yielded no detailed report about gross and microscopic findings of the disease either in adult turkeys or in other adult birds, even though the disease has been known in birds for a long period. Furthermore, immunohistochemical techniques using monoclonal or polyclonal antibodies have only been applied for the diagnosis of the disease in young birds. Therefore, the aim of the present study was to apply immunohistochemistry, using a commercially available monoclonal antibody, for the diagnosis of aspergillosis in adult turkeys and to document gross and histopathological features.

Materials and Methods

Birds

The materials for this research were 8 adult turkeys (5 live and 3 dead) of various ages (1-3 years), about 3-5 kg in body weight, with respiratory distress, brought to the Department of Veterinary Pathology of Kafkas University for diagnosis during 2001-2003.

Histopathology

The animals were grossly examined following necropsy and samples were taken from the lungs, trachea, heart, liver, spleen, kidneys, cerebrum and cerebellum and conjunctiva. The tissue samples were fixed in 10% buffered formalin, processed routinely and stained with haematoxylin and eosin (H&E), some of them with Gridley, Periodic Acid Schiff (PAS) and Ziehl-Neelsen (ZN) methods.

Immunohistochemistry

Tissue specimens from all of the turkeys were stained using the avidin-biotin-peroxidase complex (ABC) technique (12), employing a monoclonal mouse anti-aspergillus IgM antibody (Dako, Copenhagen, Denmark). All of the sections were dewaxed in xylene and hydrated through graded alcohols. Endogenous peroxidase was blocked with 3% hydrogen peroxide. The sections were incubated with phosphate-buffered saline (PBS) for 5 min, citrate buffer saline in a microwave oven for 50 min, monoclonal mouse anti-aspergillus IgM at a concentration

of 1/50 in PBS for 1 h, biotinylated rabbit anti-mouse antibody at a concentration of 1/300 in PBS for 30 min and peroxidase-conjugated streptavidine at a concentration of 1/300 in tris-buffered saline for 30 min. The tissues were washed in PBS after each step. Immunostaining was performed using 3,3 diaminobenzidine as the chromogen. Haematoxylin was used as the counterstain.

Results

Clinical signs

Respiratory distress, a significant reduction in muscle mass, poor body condition, dullness, a slight decrease in activity, and anorexia were the common signs in the 5 turkeys submitted live for necropsy. Slow loss of weight and respiratory symptoms had also been noticed by breeders prior to the deaths of the 2 turkeys submitted dead.

Necropsy

No granulomas typical of the disease were observed on the lungs in any of the cases when the thorax was opened, and therefore cultivation from the turkeys was not attempted. In 2 cases, yellowish-white necrotic foci of about 5 mm in diameter were encountered (Figure 1) when the lobes of the organ were sectioned for laboratory processes. Furthermore, in 3 turkeys, a few granulomas, 1-2 mm in diameter and yellowish-white, were detected on the cut surfaces of lungs following formalin fixation. In no case did air sacs or abdominal organs show mycotic plaques or granulomas. In addition,

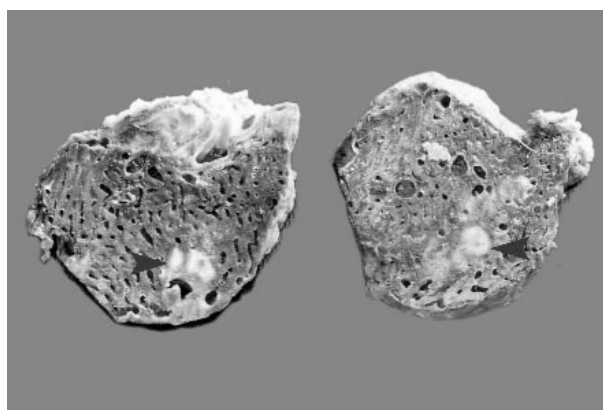


Figure 1. Few granulomas (arrows) of varying size on the cut surface of the lungs (postfixation).

a small (about 5 mm in diameter) yellowish granuloma was detected on the conjunctiva in a turkey with pulmonary plaques. When the conjunctival granuloma was opened, it was seen to contain a whitish caseous mass distributed in the adjacent subcutaneous tissues.

Histopathology

Histopathological examination of the lungs revealed that the lesions were similar in all cases and that a few granulomas of varying size were distributed in the pulmonary parenchyma. The granulomas were characterised by a necrotic centre surrounded by macrophages, lymphocytes, plasma cells, and large multinucleated foreign-body giant cells, and again by an outer thick fibrous capsule (Figure 2). It was noted that a few small granulomas were located in the wall of the bronchi and bronchioles, and that the lumina of the airways were narrowed occasionally because of compression by the peripheral granulomas. Apart from the granulomas, the pulmonary parenchyma often revealed atelectatic alveoli around the granulomatous areas, severe congestion, oedema, haemorrhages and focal lymphocellular infiltrations. The lumina of the airways were occluded by necrotic masses comprised of heterophil leukocytes, erythrocytes and desquamated necrotic epithelium in clusters of a deep eosinophilic shape. The submucosae of the bronchi and bronchioles were enlarged by severe congestion, oedema and diffuse lympho-plasmocytic infiltration. On occasion, numerous foreign multinucleated giant cells were scattered in the parenchyma adjacent to the granulomas, and aggregated around a lesser amount of caseous material.

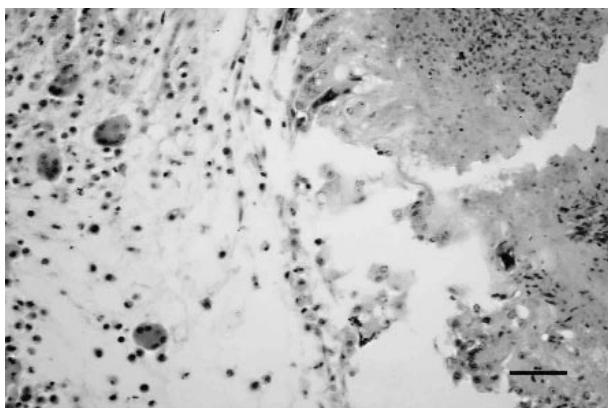


Figure 2. A lung granuloma showing central caseation necrosis with multinucleated giant cells in the pulmonary parenchyma. H&E. Bar = 50 μ m.

Conjunctival granuloma, as seen in the lungs, showed a necrotic centre surrounded by multinucleated foreign-body giant cells, and again by an outer fibrous capsule associated with diffuse heterophil leukocyte infiltration, haemorrhages and small lymphoid foci.

In the lungs, few fungal hyphae with septate and branching without the characteristic conidiophores were observable within the necrotic centre of the granulomas, using Gridley and PAS staining techniques (Figure 3). However, in some small granulomas fungal hyphae were not detected or only a few hyphal fragments were seen using the fungal stains. Ziehl-Neelsen staining found no acid-fast bacilli in the lungs in any case. Neither the fungal stains nor ZN revealed fungal elements or acid-fast bacilli in sections from the conjunctival granuloma.

Immunohistochemistry

All of the cases tested with anti-*Aspergillus* monoclonal antibody showed intense staining of fungal hyphae and their fragments within the necrotic debris of the granulomas in the lungs (Figure 4), with severe reaction of the hyphal walls. However, in a case of chronic pneumonic lesions, staining with the monoclonal reagent was somewhat less intense. Fungal hyphae were observed to be uniform in diameter, with septate and branchings at acute angles, and were abundant within the large granulomas, compared to the small granulomas, which showed severe central caseation in some cases. *Aspergillus* antigen was also detected in the areas adjacent to the identifiable fungal hyphae and in the cytoplasm of macrophages (Figure 5) and multinucleated

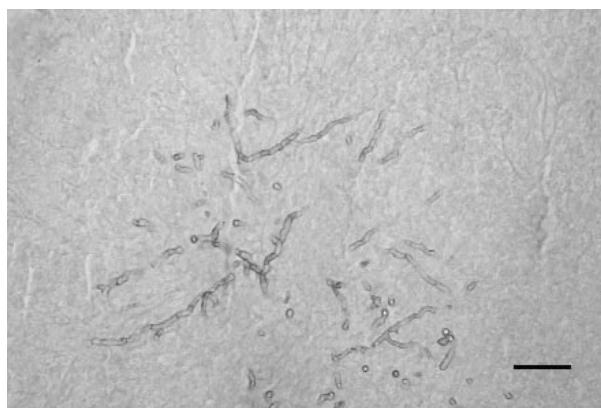

Figure 3. A few fungal hyphae within the centre of a granuloma in the lung. PAS. Bar = 20 μ m.

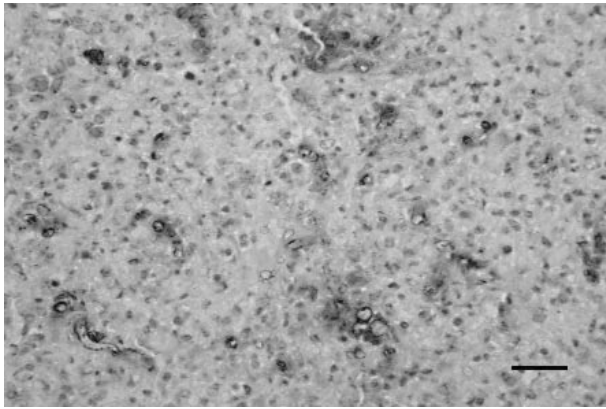


Figure 4. Fungal hyphae and their fragments reacted with monoclonal antibody in the lungs. ABC. Bar = 50 μ m.

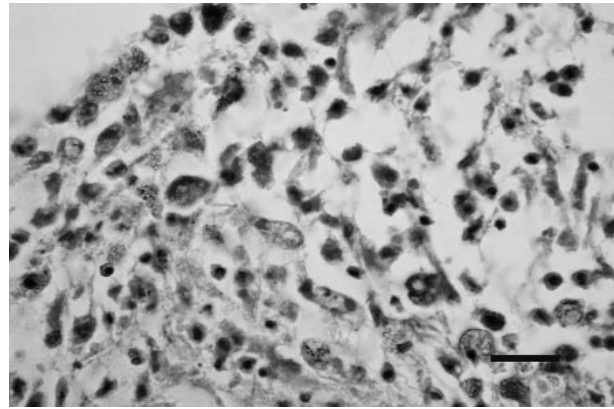


Figure 5. Numerous macrophages with phagocytised fungal fragments reacted with monoclonal antibody in the pulmonary parenchyma. ABC. Bar = 20 μ m.

foreign-body giant cells at the periphery of the lung granulomas. Neither conidial heads nor spores released from the heads were observed in any case, since the granulomas did not open into the lumina of the airways. Upon immunohistochemical staining, the conjunctival granuloma did not show any fungal elements within the necrotic centre.

Discussion

In the present study, all of the adult turkeys examined were found to have the pulmonary lesions of aspergillosis. Likewise, it is well known that aspergillosis results mainly from the inhalation of spores of fungi commonly found in the environment (13-17). It has also been established that low humidity and excessive dust may damage the respiratory epithelium and increase susceptibility to the disease (15). Therefore, the lower respiratory system is especially affected by the disease.

It has been reported that older birds usually have a debilitating type of infection with clinical signs that include dyspnoea, a major clinical sign in birds with aspergillosis, as well as gasping, inappetence and emaciation (13,14). Similarly, adult turkeys with aspergillosis admitted for necropsy showed severe respiratory distress, reduction in muscle mass and poor body condition, and these clinical signs were also identical to earlier observations in birds with aspergillosis (18-20).

In various domestic and wild birds with the disease, the most dramatic changes occur in the lower respiratory

system, with the bird's sinuses, trachea, bronchi and air sacs being affected. It has also been reported that although the lungs may show an acute diffuse form of pneumonia an acute nodular pulmonary form is most often encountered and is characterised by soft, yellow-white caseous necrotic miliary nodules measuring 1-3 mm in diameter, distributed evenly throughout the lung tissue (13,15-18,21). In the present study, upon postmortem examination, the birds revealed a few yellowish-white granulomas or necroses on the lungs, which were mainly encountered when the organ was sectioned for laboratory processes, with no involvement of air sacs. However, the granulomas typical of the disease were not observed in the lung lobes in any case, because, following inhalation of a high dose of spores, the fungus rapidly colonises the lungs and the host mounts a granulomatous response in the early stage of infection (13,14). Thus, it may be said that the gross lesions found in the turkeys at necropsy were of little diagnostic importance, when compared to young birds with acute aspergillosis. It is most likely that the death of the turkeys was due to the pulmonary granulomas and to pneumonic lesions. Likewise, it has been well documented that the death of young birds affected by aspergillosis resulted principally from respiratory failure due to the lung parenchyma being affected (20,22).

The histopathological findings in the adult turkeys were almost typical of aspergillosis in the lungs. As in young birds of various species (11,16-18), the granulomas were mainly located in the lungs and

contained a central caseation necrosis surrounded by heterophils, macrophages, lymphocytes and marked multinucleated foreign-body giant cells and again by a thick outer fibrous capsule. Moreover, occluding by necrotic debris or narrowing by peripheral granulomas of the bronchi and bronchioles may somewhat explain the difficulty in respiration in the animals. It has been documented, consistent with our results, that luminal fungal plaques and necrotic debris might obstruct the airways, resulting in respiratory problems (13,14). In particular, thick fibrous capsule formation at the periphery of the granulomas and multinucleated giant cells associated with focal lymphoid infiltration in the pulmonary parenchyma might be an important sign of the chronic form of the disease. These histological features are not constant findings for acute aspergillosis in young birds (11,16,18).

The histological appearance of some fungi is so characteristic as to be diagnostic (5). However, the appearance of fungi in tissues may be affected by steric orientation, the age of the fungi, the type of infected tissue, the number of fungal elements present and the host response, and therefore, histologically, distinctive morphological details may only allow a tentative mycological diagnosis (5,8,10), without assisting an aetiological diagnosis. It has also been stated by Jensen (8) that, especially in chronic lesions containing non-viable hyphae, staining may be only weak, or in overstained sections fungal fragments may be masked. Thus, many of the filamentous fungi cannot be reliably differentiated from one another with any of the commonly used fungal stains (2,5,9,10,23). Our study found that fungal hyphae often showed only slight staining with H&E, and that in some cases where few hyphae were present they were masked in the sections overstained using the Gridley staining technique, and therefore in such sections many hyphae were overlooked or were only distinguished with difficulty. Some authors (1,2,4,9,10) have pointed out that the diagnosis of fungal infections based on routine histopathology should be confirmed by immunostaining

using monoclonal antibodies raised against *Aspergillus* species. In accordance with the opinion of the above-mentioned authors, our study of fungal immunohistochemistry revealed that fungal hyphae and their fragments within the granulomas in the lungs of the turkeys reacted strongly when immunostaining with monoclonal antibody was used. In cases where small granulomas contained caseation necrosis, few fungal hyphae were disclosed using the fungal stains. Numerous fungal fragments apart from the hyphae were detected within the necrotic centre of the granulomas and within the cytoplasm of macrophages and foreign-body giant cells when the immunostaining was applied, in accordance with earlier observations in young birds (3,7,11,18).

Species identification of the fungi normally requires mycological culture, but this cannot always be accomplished (5,24). In such cases, the morphology of the conidial heads in the organs with access to air may be very helpful in the identification of the infecting agent (8). Unfortunately, in the present research, gross lesions found in the postmortem examination did not indicate aspergillosis, and therefore cultivation from the lungs and conjunctiva was not performed. Furthermore, diagnostic conidiophores of the fungi were not seen in the organs with access to air. Consequently, the infecting agent could not be identified to species level in the turkeys. However, upon immunostaining, all of the animals were clearly diagnosed as having aspergillosis.

In conclusion, immunohistochemistry confirmed the diagnosis of aspergillosis in the adult turkeys. Even though fungal elements within the granulomas in the lungs and other viscera of birds may be indicative of aspergillosis histologically, immunohistochemistry should be applied to obtain a reliable diagnosis in adult birds, as well as in young avian species, and to differentiate it from the tissue forms of many filamentous mycelia. It may also be suggested that in adult birds with respiratory problems aspergillosis should be considered, and that in the differential diagnosis tuberculosis and air sacculitis should be considered.

References

1. Piérard, G.E., Arrese Estrada, J., Piérard-Franchimont, C., Thiry, A., Stynen, D.: Immunohistochemical expression of galactomannan in the cytoplasm of phagocytic cells during invasive aspergillosis. *Am. J. Clin. Pathol.*, 1991; 96: 373-376.
2. Buckley, H.R., Richardson, M.D., Evans, E.G., Wheat, L.J.: Immunodiagnosis of invasive fungal infection. *J. Med. Vet. Mycol.*, 1992; 30: 249-260.

3. Carrasco, L., Bautista, M.J., de las Mulas, J.M., Jensen, H.E.: Application of enzyme-immunohistochemistry for the diagnosis of aspergillosis, candidiasis, and zygomycosis in three lovebirds. *Avian Dis.*, 1993; 37: 923-927.
4. Jensen, H.E., Schonheyder, H.C., Hotchi, M., Kaufman, L.: Diagnosis of systemic mycoses by specific immunohistochemical tests. *Acta Pathol. Microbiol. Immunol. Scand.*, 1996; 104: 241-258.
5. Phillips, P., Weiner, M.H.: Invasive aspergillosis diagnosed by immunohistochemistry with monoclonal and polyclonal reagents. *Hum. Pathol.*, 1987; 18: 1015-1024.
6. Kaufman, L.: Immunohistologic diagnosis of systemic mycoses: an update. *Eur. J. Epidemiol.*, 1992; 8: 377-382.
7. Carrasco, L., Gomez-Villamandos, J.C., Jensen, H.E.: Systemic candidosis and concomitant aspergillosis and zygomycosis in two Amazon parakeets (*Amazona aestiva*). *Mycoses*, 1998; 41: 297-301.
8. Jensen, H.E.: Systemic bovine aspergillosis and zygomycosis in Denmark with reference to pathogenesis, pathology, and diagnosis. *Acta Pathol. Microbiol. Immunol. Scand. Suppl.*, 1994; 42: 5-48.
9. Fenelon, L.E., Hamilton, A.J., Figueroa, J.I., Bartholomew, M.A., Allen, M.H., McCarthy, P., Hay, R.J.: Production of specific monoclonal antibodies to *Aspergillus* species and their use in immunohistochemical identification of aspergillosis. *J. Clin. Microbiol.*, 1999; 37: 1221-1223.
10. Jensen, H.E., Aalbæk, B., Lind, P., Frandsen, P.L., Krogh, H.V., Stynen, D.: Enzyme immunohistochemistry with mono- and polyclonal antibodies in the pathological diagnosis of systemic bovine mycoses. *Acta Pathol. Microbiol. Immunol. Scand.*, 1993; 101: 505-516.
11. Jensen, H.E., Christensen, J.P., Bisgaard, M., Nielsen, O.L.: Immunohistochemistry for the diagnosis of aspergillosis in turkey poults. *Avian Pathol.*, 1997; 26: 5-18.
12. Hsu, S.M., Raine, L., Fanger, H.: Use of avidin-biotin-peroxidase complex (ABC) in immunoperoxidase techniques: a comparison between ABC and unlabeled antibody (PAP) procedures. *J. Histochem. Cytochem.*, 1981; 29: 577-580.
13. Richard, J.L.: Aspergillosis. In: Calnek, B.W., Barnes, H., Beard, C.W., Reid, W.M., Yoder, H.W., Eds. *Diseases of Poultry*. Wolfe Publishing Ltd, London, 1991; 326-334.
14. Singh, N., Grewal, G.S., Brar, R.S., Singh, B., Dhaliwal, A.S., Jand, S.K.: Outbreak of mycotic tracheitis in domestic fowl. *Mycoses*, 1993; 36: 65-67.
15. Machin, K., Langelier, K.M., Lewis, R.J.: Aspergillosis outbreak in Stellar's jays (*Cyanocitta stelleri*) from central Vancouver Island. *Can. Vet. J.*, 1993; 34: 247-248.
16. Hawkey, C.M., Pugsley, S.L., Knight, J.A.: Abnormal heterophils in a king shag with aspergillosis. *Vet. Rec.*, 1984; 114: 322-324.
17. Reece, R.L., Taylor, T.K., Dickson, D.B., Kerr, P.J.: Mycosis of commercial Japanese quail, ducks and turkeys. *Aust. Vet. J.*, 1986; 63: 196-197.
18. Beytut, E., Ozcan, K., Erginsoy, S.: Immunohistochemical detection of fungal elements in the tissues of goslings with pulmonary and systemic aspergillosis. *Acta. Vet. Hung.*, 2004; 52: 71-84.
19. Pal, M., Gangopadhyay, R.M., Prajapati, K.S.: Systemic aspergillosis in chicks due to *Aspergillus flavus*. *Indian J. Anim. Sci.*, 1989; 59: 1074-1075.
20. Pandita, A., Sadana, J.R., Asrani, R.K.: Studies on clinical signs and haematological alterations in pneumonic aspergillosis due to *Aspergillus flavus* in Japanese quail. *Mycopathologia*, 1991; 116: 119-123.
21. Chute, H.L.: Diseases caused by fungi. In: Biester, H.E., Schwarte, L.H., Eds. *Diseases of Poultry*. The Iowa State University Press, Iowa, 1965; 494-502.
22. Okoye, J.O.A., Okeke, C.N.: Pathogenicity of an isolate of *Aspergillus flavus* in chickens. *Avian Pathol.*, 1986; 15: 259-270.
23. Sancak, A.A., Paracikoğlu, J.: Aspergillosis and gastric impaction in an ostrich. *Turk. J. Vet. Anim. Sci.*, 2005; 29: 933-935.
24. Jensen, H.E., Schonheyder, H.: Immunofluorescence staining of hyphae in the histopathological diagnosis of mycoses in cattle. *J. Med. Vet. Mycol.*, 1989; 27: 33-44.