

Histopathological Changes after Transplantation of Stored Osteochondral Allografts into Articular Cartilage Lesions in Dogs

Zbigniew ADAMIAK, Wojciech BRZESKI

Department of Surgery and Roentgenology, Faculty of Veterinary Medicine, University of Warmia and Mazury in Olsztyn, ul. Oczapowskiego 14, 10-957 Olsztyn - POLAND

Received: 14.12.2005

Abstract: The aim of this study was to evaluate histopathological changes in the recipient site after transplantation of stored osteochondral allografts into articular cartilage defects in 8 dogs. In all dogs a single osteochondral allograft was transplanted into articular cartilage lesions. The results of the completed surgeries include a 12-month follow-up study. It was found that the stored osteochondral allografts were very firmly connected to the recipient tissue and no arthritis changes were noted.

Key Words: Dog, osteochondral allografts, chondral lesions, articular cartilage, OATS

Treating articular cartilage lesions in dogs is a challenge in the contemporary orthopedics of small animals. Currently, there are numerous methods for treating chondral lesions, which, among others, result from the fact that the cartilage that covers articular surfaces of the long bones in adult animals has little potential for regeneration. Chondral lesions, which do not penetrate into the subchondral lamella of a bone, do not heal and may lead to the development of osteoarthritis. The appearance of such lesions initiates a destructive and proliferative process. In the veterinary and human medicine literature various surgical treatments of cartilage injuries are described, e.g., joint lavage and arthroscopic debridement, drilling, abrasion arthroplasty, microfracture, osteochondral allo- and autografting techniques, periosteal and perichondral resurfacing, and chondrocyte transplantation (1-10). The current literature does not contain many reports on the treatment of chondral lesions by osteochondral autografts in dogs. There are few articles describing the use of chondrocytes in the regeneration of articular cartilage lesions (11,12). The majority of papers deal with osteochondral grafting in the treatment of articular cartilage defects in horses (13-16).

The aim of the present study was to evaluate the histopathological changes in the articular cartilage of knee joints in mature dogs after the application of single, stored osteochondral allografts.

The experiment was conducted with 8 crossbred dogs, 7-9-years old, of both sexes, 4 male and 4 female. The females were neutered. The body weights of all dogs ranged from 35 to 50 kg. Criteria for inclusion were no history of earlier episodes of lameness, no arthritic changes on pre-study radiographs, and no pre-existing cranial cruciate ligament or OCD problems. The study was performed with the approval of the Local Ethics Committee. All dogs were treated according to animal welfare legal regulations.

Each dog was pre-medicated with acepromazine 0.025 mg/kg i.m. (Calmivet Vetoquinol, F), buprenorphine 0.02 mg/kg i.m. (Bunondol WZF Polfa, Poland), xylazine 1 mg/kg i.m. (Rometar 2% Spofa, Prague, Czech Republic). General anesthesia was induced by the administration of thiopental 12 mg/kg i.v. (Thiopental, VÚAB-Roztoky u Prahy, Czech Republic). Anesthesia was maintained with isoflurane in oxygen in a semiclosed system. Post-operative treatment comprised of buprenorphine 0.02 mg/kg i.m. (Bunondol WZF Polfa,

*E-mail: zbigniew.adamiak@wp.pl

Poland) for 3 days, and meloxicam 0.2 mg/kg p.o. (Meloxam; Polfa Warszawa, Poland) for 10 days and cefalexin 10 mg/kg i.m. (Ceporex; Schering-Plough, UK) for 3 days.

The surgeries of osteochondral allografts were conducted with OATS (Osteochondral Autograft Transfer System) sets (Arthrex, Naples, USA). The OATS system allows for single osteochondral cylinder transplantation.

After the pre-medication, the surgical field was prepared according to the asepsis requirements.

Osteochondral allografts were taken from 2 dogs, which were euthanized due to systematic diseases. All allografts were sampled from the external part of the lateral trochlea of the femoral bone, which is a non-weight bearing spot of the joint, laterally from the sulcus of the trochlea. Obtained allografts were stored in Ringer's solution with 5% gentamicin sulfate at 4 °C for 7 days. Next, osteochondral grafts were transplanted into the recipient site (Figure 1). The osteochondral plug was introduced into the cartilage defect on the central weight-bearing portion of the medial femoral condyle in an area that would receive maximal weight bearing during ambulation (Figure 2). This site of the joint was used in all 8 dogs. At the time of surgery, there were no arthritic or wear changes on the surrounding recipient area. Single osteochondral cylinders were grafted on the left stifle joint in all the dogs. After the surgery, the fitting of the

grafted plug was checked to ensure that the articular surface of the graft was collinear with the rest of the medial femoral condyle joint surface, and the joint cavity was washed with Ringer's solution. After the surgery was finished, the soft tissues were closed routinely. Clinical observations as well as radiological (Figure 3) and arthroscopic examinations were conducted 3, 6, 9, and 12 months after surgery. Visual gait analysis varying from sound to unable to put the foot on the ground was part of the clinical examination and a grading system from 0 to 10 was used.

Six months after surgery 4 dogs were euthanized and 12 months after a completed period of follow-up the second 4 dogs were killed. The dogs were euthanized using an overdose of intravenous pentobarbitone (Morbital, Biowet Pulawy, Poland). As a control, articular cartilage from the area surrounding the osteochondral graft was removed using a scalpel and oscillating saw. Fragments 10 mm in diameter were taken for the histopathological examination. Each segment consisted of articular cartilage and a subchondral layer and included the graft with the surrounding tissue. After being taken, the osteochondral segments were immersed for 7 days in a 10% solution of buffered formalin. Osteochondral segments were electrolytically decalcified in Romeis' liquid and embedded in paraffin blocks. A single segment of the study material was correctly decalcified within 7 days. Cutting of the decalcified samples was done with

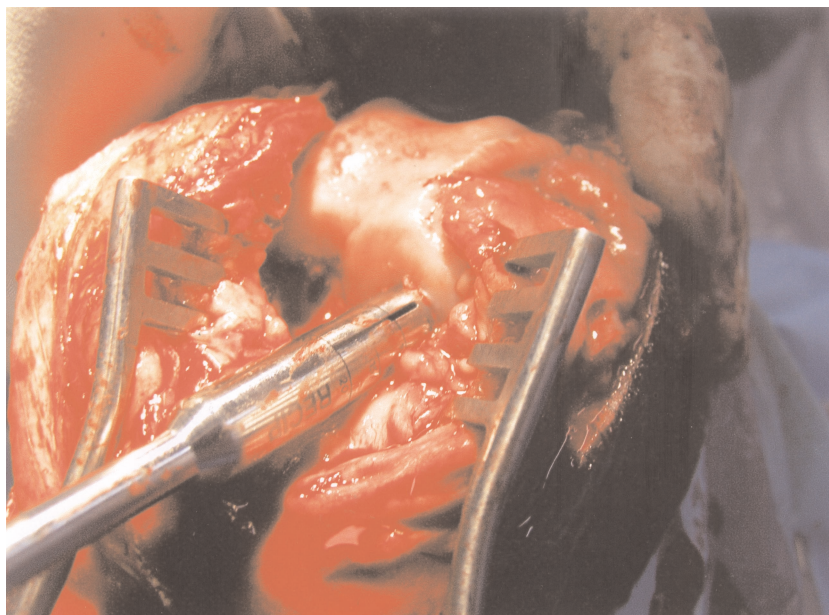


Figure 1. Osteochondral graft transplantation into the recipient site.

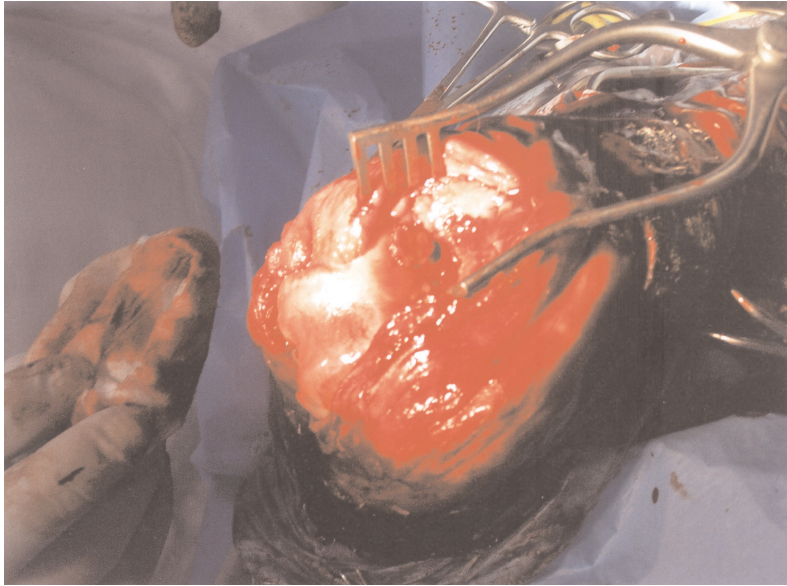


Figure 2. Macroscopic view of the introduced osteochondral graft.

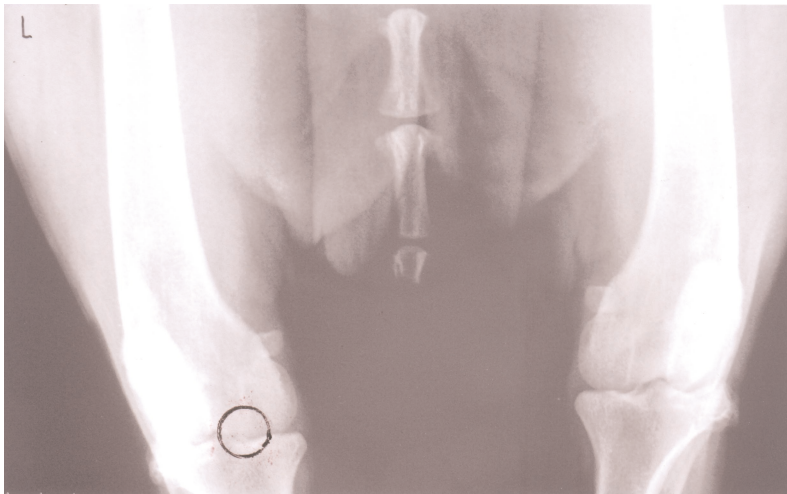


Figure 3. Radiograph performed 12 months after surgery.

Reichert's microtome. The preparations were stained with hematoxylin and eosin.

In our study no complications were observed during or after surgery in any of the operated dogs. In the clinical tests conducted during the post-operative period, a slight limping (3 degree of lameness) was observed in the left operated limb when walking in all the dogs; it subsided 3-7 days after the surgery. After this period lameness was not observed and all dogs were sound before euthanasia.

A histopathological examination of preparations taken from the dogs 6 months after the surgery revealed a firm

connection of the allograft with the cartilage and bone tissue of the recipient site (Figure 4). The preparations contained large amounts of hyaline cartilage, thick bone trabeculae with intensive lanular resorption of the trabeculae. It was also observed that cells of hyaline cartilage were arranged in columns, with part of the chondrocytes transformed into bone trabeculae. A fissure between the recipient site and implanted osteochondral plug was filled with fibrous tissue. No histopathological changes were found in the recipient subchondral bone. The defects left by the grafts were filled with fibrocartilage, which was well fixed to the osteochondral donor site.

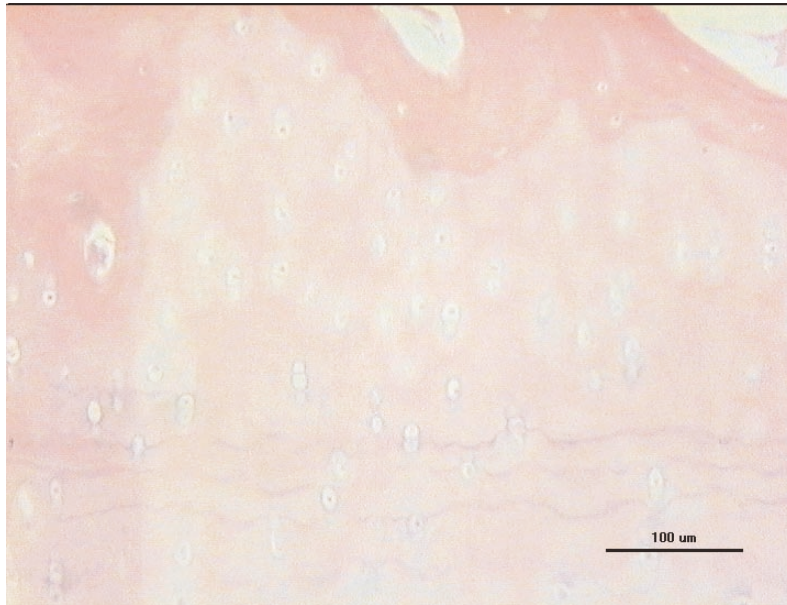


Figure 4. Firm connection of the allograft with the cartilage and bone tissue of the recipient site 6 months after transplantation. HE staining, magn. X 120.

Twelve months after the surgery, a histological examination of segments taken from the osteochondral allografts in the recipient site revealed a thick layer of hyaline cartilage (Figure 5). Chondrocytes were arranged in normal columns and the connection with host cartilage bone tissue was very firm.

After 12 months no histopathological abnormality was found in the recipient subchondral bone.

The veterinary literature does not contain many studies of histopathological changes after osteochondral allograft transplantations in the treatment of cartilage

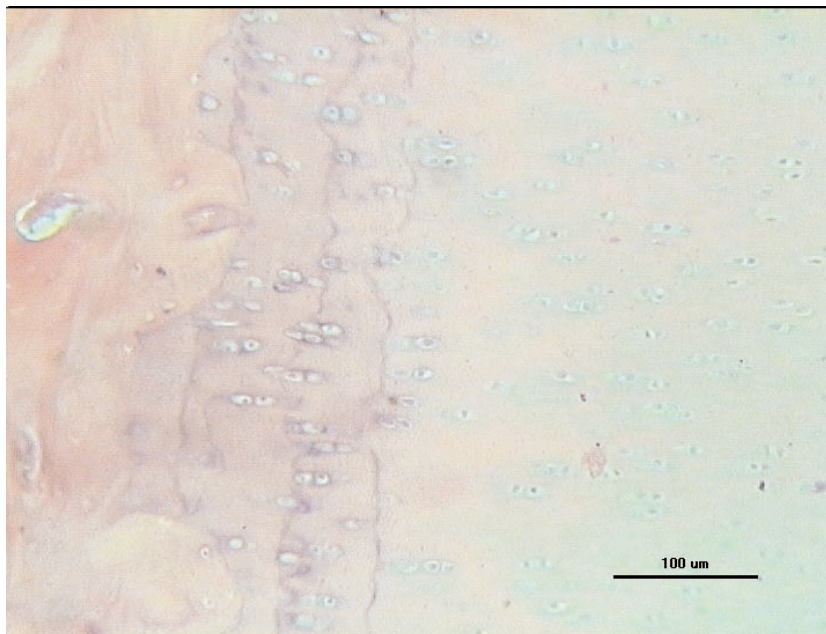


Figure 5. Twelve-month post-operation autograft with normal hyaline cartilage tissues and solid fusion with recipient bone tissue. HE staining, magn. X 120.

defects (17,18). Our own research included an evaluation of the histopathological changes after osteochondral allograft transplantation in cartilage defects in mature dogs, where adult articular cartilage has an extremely a very low ability to repair itself after injury. In all the dogs used for the surgery with osteochondral grafts, the articular cartilage of the transplanted plugs and host tissue in the joints operated on were as histologically healthy as normal cartilage. In the experiment, all the osteochondral plugs used for grafting were taken from healthy articular cartilage. During the surgery the donor site did not show any signs of pathological lesions.

Histological examinations revealed that in all cases chondrocytes were arranged in columns like in normal

cartilage. It was also found that the osteochondral allografts were very firmly connected to the trabecular bone of the subchondral layer of the defect.

The present histopathological research into the use of osteochondral allografts found that osteochondral allografts stored for 7 days united with recipient tissue. Grafted osteochondral plugs did not induce any arthritic changes in the surrounding cartilage of the host site. Histopathological examination revealed thickness of the hyaline cartilage's graft. No degenerative reactions in the knee joints operated on were observed after the transplant surgeries.

References

1. Aglietti, P., Buzzi, R., Bassi, P.B., Fioriti, M.: Arthroscopic drilling in juvenile osteochondritis dissecans of the medial femoral condyle. *Arthroscopy*, 1994; 10: 286-291.
2. Aubin, P.P., Cheah, H.K., Davis, A.M., Gross, A.E.: Long-term follow up femoral osteochondral allografts for posttraumatic knee defects. *Clin. Orthop. Relat. Res.*, 2001; 391: 318-327.
3. Bouwmeester, P.S., Kuijjer, R., Homminga, G.N., Bulstra, S.K., Geesink, R.G.: A retrospective analysis of two independent prospective cartilage repair studies: autogenous perichondral grafting versus subchondral drilling 10 years post-surgery. *J. Orthop. Res.*, 2002; 20: 267-273.
4. Carranza-Bencano, A., Garcia-Paino, L., Armas-Padron, J.R., Cayuela-Dominguez, A.: Neochondrogenesis in repair of full-thickness articular cartilage defects using free autogenous periosteal grafts in the rabbit. A follow-up in six months. *Osteoarthritis Cartilage*, 2000; 8: 351-358.
5. Chandrasekharam, B., Vasantha, M.S., Ramakrishna, O.: Autologous perichondral graft transplantation to stifle in dogs. *Indian Vet. J.*, 1991; 68: 671-672.
6. Desjardins, M.R., Hurtig, M.B., Palmer, N.C.: Heterotopic transfer of fresh and cryopreserved autogenous articular cartilage in the horse. *Vet. Surg.*, 1991; 20: 434-445.
7. Jackson, R.W., Dieterichs, C.: The results of arthroscopic lavage and debridement of osteoarthritic knees based on the severity of degeneration: a 4- to 6-year symptomatic follow-up. *Arthroscopy*, 2003; 19: 13-20.
8. Lane, J.G., Tontz, W.L., Ball, S.T. Massie, J.B., Chen, A.C., Bae, W.C., Amiel, M.E., Sah, R.L., Amiel, D.: A morphologic, biochemical, and biomechanical assessment of short-term effects of osteochondral autograft plug transfer in an animal model. *Arthroscopy*, 2001; 17: 856-863.
9. Oka, Y., Ikeda, M.: Treatment of severe osteochondritis dissecans of the elbow using osteochondral grafts from a rib. *J. Bone Joint Surg. Br.*, 2001; 83: 738-739.
10. Vachon, A., Bramlage, L.R., Gabel, A.A., Weisbrode, S.: Evaluation of the repair process of cartilage defects of the equine third carpal bone with and without subchondral bone perforation. *Am. J. Vet. Res.*, 1986; 47: 2637-2645.
11. Breinan, H.A., Minas, T., Hsu, H.P., Nehrer, S., Shortkroff, S., Spector, M.: Autologous chondrocyte implantation in a canine model: change in composition of reparative tissue with time. *J. Orthop. Res.*, 2001; 19: 482-492.
12. Shortkroff, S., Barone, L., Hsu, H.P., Wrenn, C., Gagne, I., Chi, T., Breinan, H., Minas, T., Sledge, C.B., Tubo, R., Spector, M.: Healing of chondral and osteochondral defects in a canine model: the role of cultured chondrocytes in regeneration of articular cartilage. *Biomaterials*, 1996; 17: 147-154.
13. Bodo, G., Kaposi, A.D., Hangody, L., Toth, J., Bakos, Z., Lukacs, Z., Pentek, G.: The surgical technique and the age of the horse both influence the outcome on mosaicplasty in a cadaver equine stifle model. *Acta Vet. Hung.*, 2001; 49: 111-116.
14. Hurtig, M., Pearce, S., Warren, S., Kalra, M., Miniaci, A.: Arthroscopic mosaic arthroplasty in the equine third carpal bone. *Vet. Surg.*, 2001; 30: 228-239.
15. Stover, S.M., Pool, R.R., Lloyd, K.C.K.: Repair of surgically created osteochondral defects with autogenous sternal osteochondral grafts in the horse. *Vet. Surg.*, 1989; 18: 76-77.
16. Vachon, A.M., McIlwraith, C.W., Trotter, G.W., Norrdin, R.W., Powers, B.E.: Neochondrogenesis in free intra-articular, periosteal, and perichondral autografts in horse. *Am. J. Vet. Res.*, 1989; 50: 1787-1794.
17. Adamiak, Z., Rotkiewicz, T., Brzeski, W.: Histopathological examination of articular cartilage and joint capsule after osteochondral allografts usage in sheep. *Med. Weter.*, 2005; 61: 1043-1045 (in Polish).
18. Hurtig, M.B., Novak, K., McPherson, R., McFadden, S., McGann, L.E., Muldrew, K., Schachar, N.S.: Osteochondral dowel transplantation for repair of focal defects in the knee: an outcome study using an ovine model. *Vet. Surg.*, 1998; 27: 5-16.