

Anatomical and Histological Studies of Accessory Adrenal Nodules in Caspian Miniature Horses

Javad AHMADPANAHI*

School of Veterinary Medicine, University of Semnan, P.O. Box: 35195-363, Semnan - IRAN

Received: 08.08.2006

Abstract: Microscopic and macroscopic structures of accessory adrenal nodules in Caspian miniature horses (5 males and 5 females) were studied. The accessory adrenal nodules were round or oval and yellow to red. Their maximum diameters varied from 0.1 to 0.5 cm. These nodules were found near the kidneys and adrenal glands, but they were in close contact with the adrenal gland. The accessory adrenal nodules were similar to the adrenal cortex microscopically, and from the outer layer to the inner layer they contained glomerulosa, intermedia, and fasciculata. The adrenal nodules were surrounded by a capsule of collagenous dense connective tissue as well.

Key Words: Accessory adrenal nodule, miniature horse, histology, adrenal gland

The adrenal glands are paired endocrine organs located within the abdominal cavity. Hormones are secreted by the adrenal glands, which regulate some metabolic processes and enable the animals to function in a constantly changing environment (1). These adrenal glands are a pair of compound, flattened endocrine organs located in the retroperitoneal tissue along the medial cranial poles of the kidneys (2,3). A macroscopic cross section of the gland reveals that it is composed of a distinct cortex and medulla (2-5) and is encapsulated by a thick connective tissue capsule (3,6). The cortex is flesh colored (in ruminants and swine) or cream or light yellow (in horses, dogs, and cats), and depends upon the lipid content (2). The medulla is reddish brown due to the presence of blood flow in the medullary veins (2,7).

Embryologically, each gland has a dual origin and, in fact, 2 endocrine glands have been combined within a common connective tissue capsule (1,5,8). They are derived from 2 germ layers, the mesoderm and neural crest ectoderm (1,4,8). The adrenal cortex originates from mesoderm located between the dorsal mesentery of the gut and the medial surface of the mesenteric kidney (1,9). The adrenal medulla originates from the primitive ganglia of the celiac plexus (1). The mesenchyme between the root of the mesentery and the developing gonad

proliferates and differentiates into the fetal or primitive adrenal cortex. Neural crest cells develop within the middle of the fetal cortex to form the adrenal medulla. Subsequently, other mesenchymal cells invade the developing gland, proliferate, and evolve into the adult cortex. After birth the fetal cortex regresses, but its central region changes into the reticular zone (2,8,10). Manohar et al. (11) showed that the adrenal blood flow in horses is increased significantly during both rest and activity.

One of the abnormalities of the adrenal glands is displacement of the accessory adrenal nodules (12). These nodules are usually found near the adrenal glands, kidneys, and gonads (12,13). The male gonads are derived from interstitial mesoderm near the growing adrenal and medial side of the mesonephric kidney. Then the gonads descend into the scrotum. The accessory adrenal cortex may fall into the scrotum or spermatic cord (12). In humans, especially in children, the adrenal cortical nodules were reported as pathologic defects in the spermatic cord (14,15), epididymis (16), and liver (17). The presence of accessory adrenal nodules in some animals such as the horse, dog, and sheep has been demonstrated in some studies (13). In this investigation, the presence of accessory adrenal nodules and their

* E-mail: jvd_panahi@yahoo.com

anatomical and histological structures in miniature horses were studied.

This research was performed on 10 Caspian miniature horses 4-6 years old (5 males and 5 females). Their health had been confirmed by clinical and paraclinical examinations. They were tranquilized by acepromazine maleate (0.08 mg/kg bw, IV) and then were euthanized by withdrawal of blood from the right common carotid artery after local infiltration anesthesia of the neck region. Then the abdominal cavity was opened and, at the first stage, the situation of the adrenal glands and accessory adrenal nodules was assessed anatomically and checked microscopically. Histological sections were stained using Hematoxylin & Eosin, Periodic Acid Schiff (PAS), Alcian blue, and Mallory's staining.

Accessory adrenal nodules in Caspian miniature horses were round or oval and yellow to red. Their maximum diameters varied from 0.1 to 0.5 cm. These nodules were near the kidneys and adrenal glands, but they often were

in close contact with the adrenal glands. The accessory adrenal nodules were similar to the adrenal cortex microscopically and from the external layer to the internal layer contained zona glomerulosa, zona intermedia, and zona fasciculata. These adrenal nodules had been surrounded by a capsule of collagenous dense connective tissue (Figure 1). Medullary tissue was not found in these nodules.

The zona glomerulosa (also called the zona arcuata) was a subcapsular area that included some curved cords or arcades. The cells were columnar and the parenchyma was closely related to an extensive vascular network. The cytoplasm was acidophilic and the nuclei were small and dark (Figure 2). The zona intermedia consisted of undifferentiated cells, and was situated between the zona glomerulosa and zona fasciculata. This area was narrow with highly cellular accumulation. The cells were similar but smaller than those of the zona glomerulosa (Figure 2).

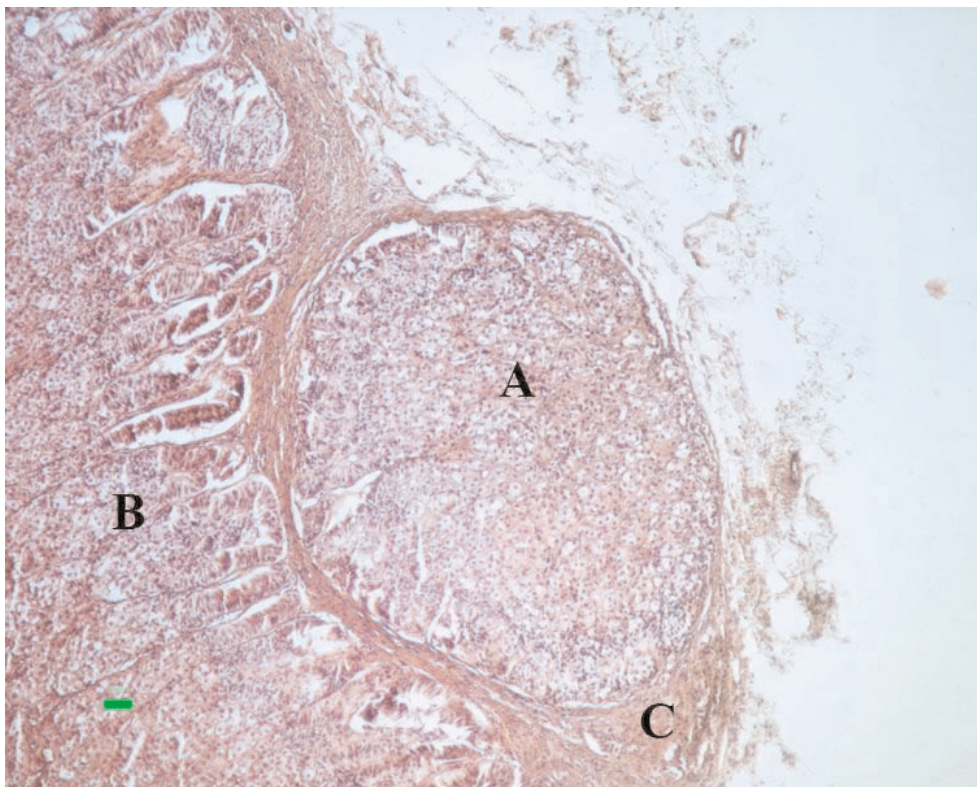


Figure 1. The accessory adrenal nodule (A) in close contact with the adrenal gland (B), which was surrounded by a capsule of dense connective tissue (C) (H&E $\times 125$).

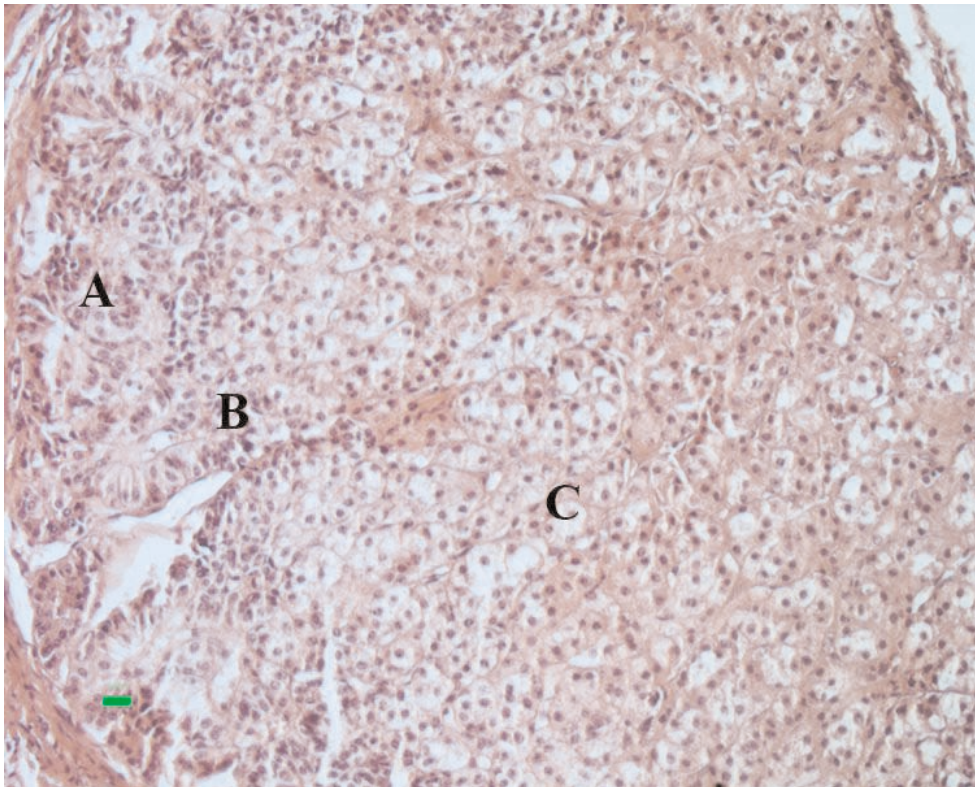


Figure 2. Accessory adrenal nodule: zona glomerulosa (A), zona intermedia (B), and zona fasciculata (C) (H&E $\times 250$).

The zona fasciculata was the widest area of the accessory adrenal nodules. It included cuboidal or polyhedral cells arranged in radial cords. Each cord contained 1 or 2 cells separated from adjacent cords by an extensive sinus network. The nuclei of the large cells of the outer two-thirds of this zone (often called spongiocytes) were larger and vesicular, and the cytoplasm of these cells was foamy. The cells of the inner third of the zona fasciculata were free of lipids (Figure 2).

Accessory adrenal nodules are abnormalities of the adrenal glands (12). These nodules are commonly found near the adrenal glands and kidneys (12,13). These nodules were also found in the same location among the Caspian miniature horses and only contained the adrenal cortex. Medulla were absent in these nodules. Probably because of the different origin of the 2 parts of the adrenal glands, the cortex from the mesoderm, and the medulla from the ectoderm (9,12,13,18), the adrenal nodules only contained the adrenal cortex. It was also reported by Prasad and Sinha (13) that the accessory

adrenal nodules were found in proximity to the main adrenal gland in 6 animals (female buffalo, bullock, horse, dog, goat, and sheep), and no medullary tissue was found in any of the accessory nodules.

No report has mentioned the size or color of the accessory adrenal nodules in animals, including horses. The histological structures of these nodules were similar between the Caspian miniature and other horses. Zona glomerulosa, zona intermedia and zona fasciculata were distinguished in the accessory adrenal nodules of the Caspian miniature horses and were enclosed by a capsule of dense connective tissue as well as the adrenal gland. Prasad and Sinha (13) also reported that accessory adrenal nodules were delineated by a distinct connective tissue capsule. They revealed that cells resembling zona glomerulosa and fasciculata were discernible in the accessory nodules of horses, goats, and sheep, but they did not explain anything about the zona intermedia.

They also reported that in dogs only cells representing zona glomerulosa were found. Both intracapsular and extracapsular accessory adrenal cortical nodules were found in the adrenals of goats and sheep, whereas accessory nodules were absent in pigs and fowl (13). It seems that the accessory adrenal nodules in Caspian miniature horses are similar to those in other horses.

Acknowledgments

Financial support for this study was provided by the University of Tehran (UT). The author also thanks Dr. M. Rezaian, Dr. H. Gilanpoor, Saboori, Chavoshi and Ebrahimpoor and all those who helped us in this study and also thanks Dr. M.R. Salimi-Bejestani for reviewing the manuscript.

References

1. McDonald, L.E.: *Veterinary Endocrinology and Reproduction*. 5th ed. Iowa State Press, Iowa. 2003; 165-201.
2. Robert, G., Septimus, S., James, D.G.: *Sisson & Grossman's The Anatomy of the Domestic Animals*. Vol. (1): 5th ed., W.B. Saunders Company, Philadelphia. 1975; 552-553.
3. Frandson, R.D., Lee Wilke, W., Anna, D.F.: *Anatomy and Physiology of Farm Animals*, 6th ed. Lippincott Williams & Wilkins, Baltimore, Maryland. 2003; 194-195.
4. Mitchell, D.G., Nascimento, A.B., Alam, F., Grasel, R.P., Holland, G., O'Hara, B.J.: Normal adrenal gland: in vivo observations, and high-resolution in vitro chemical shift MR imaging-histologic correlation. *Acad. Radiol.*, 2002; 9: 430-436.
5. Prasad, G., Sinha, R.D.: Micrometric observations on the adrenal glands of domestic animals. *Ind. J. Anim. Sci.*, 1981; 51: 1144-1147.
6. Hussin, A.M.: Anatomical and histological study on the adrenal gland of the local donkey (*Equus asinus*). *Iraq. J. Vet. Sci.*, 2003; 16: 129-132.
7. Gelberg, H., Cockerell, G.L., Minor, R.R.: A light and electron microscopic study of a normal adrenal medulla and a pheochromocytoma from a horse. *Vet. Pathol.*, 1979; 16: 395-404.
8. Rezaian, M.: *A Text Atlas of Veterinary Histology*. Tehran University publications, Iran. 1998; 174-176.
9. Yamauchi, S.: Histological development of the equine fetal adrenal gland. *J. Reprod. Fertil. Suppl.*, 1979; 27: 487-491.
10. William, J.B.: *Applied Veterinary Histology*. 3rd ed. Mosby, Inc. Missouri. 1993; 416-424.
11. Manohar, M., Goetz, T.E., Saupe, B., Hutchens, E., Coney, E.: Thyroid, renal and splanchnic circulation in horses at rest and during short-term exercise. *Am. J. Vet. Res.*, 1995; 56: 1356-61.
12. Noden, D.M., de Lahunta, A.: *The Embryology of Domestic Animals*. W.B. Saunders, Philadelphia, 1985.
13. Prasad, G., Sinha, R.D.: Occurrence of accessory adrenal cortical nodule in the domestic animals. *Indian. J. Anim. Sci.*, 1980; 50: 1060-1063.
14. Oguzkurt, P., Oz, S., Kayaselcuk, F.: Ectopic adrenal tissue: an incidental finding during inguinoscrotal operations in children. *Hernia*, 2002; 6: 62-63.
15. Savas, G., Candir, O., Bezir, M., Cakmak, M.: Ectopic adrenocortical nodules along the spermatic cord of children. *Int. Urol. Nephrol.*, 2001; 32: 681-685.
16. Perez Garcia, F.J., Guate Ortiz, J.L., Gutierrez Garcia, R., Tuero Gonzalez, J.S., Lanzas Prieto, J.M., Gonzalez Naranjo, F.: Adrenal ectopy in epididymis. *Arch. Esp. Urol.*, 2001; 54: 446-448. (Article in Spanish)
17. Vestfrid, M.A.: Ectopic adrenal cortex in neonatal liver. *Histopathology*, 1980; 4: 669-672.
18. Webb, P.D., Leadon, D.P., Rossdale, P.D., Jeffcott, L.B.: Studies on equine prematurity. 5: Histology of the adrenal cortex of the premature newborn foal. *Equine Vet. J.*, 1984; 16: 297-299.