

## Uterine and Ovarian Metastasis of Transmissible Venereal Tumor in a Bitch

Ayhan BAŞTAN<sup>1,\*</sup>, Duygu BAKİ ACAR<sup>2</sup>, Mehmet CENGİZ<sup>1</sup>

<sup>1</sup>Department of Obstetrics and Gynecology, Faculty of Veterinary Medicine, Ankara University, Ankara - TURKEY

<sup>2</sup>Department of Obstetrics and Gynecology, Faculty of Veterinary Medicine, Afyon Kocatepe University, Afyon - TURKEY

Received: 07.07.2006

**Abstract:** In this case report, metastasis of a transmissible venereal tumor (TVT) to the uterus and ovaries is presented. A 7-year-old female boxer dog with hemorrhagic vulvar discharge and a vaginal mass was brought to Ankara University Faculty of Veterinary Medicine, Clinics of Gynecology and Obstetrics. TVT was diagnosed by clinical findings and cytologic examination. Multifocal nodules in the uterus and enlargements of the uterine wall were detected by ultrasonographic examination. Ovariohysterectomy was performed because of uterine pathology. Histopathologic examination of the uterus and ovarium showed that the multifocal masses in the uterus and ovaries originated from vaginal TVT.

**Key Words:** Bitch, TVT, metastasis, uterus, ovarium

### Bir Köpekte Transmissible Venereal Tümörün Uterus ve Ovaryum Metastazi

**Özet:** Bu olgu takdiminde transmissible venereal tümörün (TVT) uterus ve ovaryuma yaptığı metastaz vurgulanmıştır. Yedi yaşlı boxer ırkı dişi köpek, 21 gündür devam eden kanlı vulva akıntısı ve vaginal kitle şikâyetiyle Ankara Üniversitesi Veteriner Fakültesi Doğum ve Jinekoloji Anabilim Dalı Kliniğine getirildi. Klinik bulgular ve sitolojik inceleme ile TVT teşhis edildi. Ultrasonografik muayenede, uterusu multifokal nodüller ve duvarındaki kalınlaşmalar tespit edildi. Uterus patolojisi nedeniyle ovaryohisterektomi uygulandı. Uterus ve ovaryumun histopatolojik muayenesinde, uterus ve ovaryum üzerindeki multifokal kitlelerin, vagina kökenli TVT olduğu ortaya kondu.

**Anahtar Sözcükler:** Köpek, TVT, metastaz, uterus, ovaryum

### Introduction

Transmissible venereal tumor (TVT) is a contagious, sexually transmitted tumor that affects only dogs (1). The tumor is effectively transmitted by contact with mucous membranes and is transmitted more easily if there are abrasions or breaks in the integrity of the mucosal surface. In addition to genital contact, the tumor can be transmitted by social behavior (e.g., sniffing and licking), which may help to explain cases of extragenital TVT in nasal and oral cavities (2,3). In bitches, the tumor may spread directly to the internal genital tract, involving the cervix, uterus, and oviducts (4).

TVTs are immunogenic tumors, and it has been demonstrated that the immune system of the host has a main role in inhibiting tumor growth and metastasis. In

young dogs or dogs with a compromised immune system, tumors may have a greater tendency to metastasize. They have been described in subcutaneous tissue, skin, lymph nodes, eyes, tonsils, liver, spleen, oral mucosa, pituitary, peritoneum, brain, and bone marrow (5).

### Case History

A 7-year-old boxer bitch that had given birth 3 months previously was brought to the clinic because of hemorrhagic vulvar discharge lasting 21 days and a fragile vaginal mass. Clinical symptoms, and cytological and ultrasonographic findings were evaluated for diagnosis. Specific TVT cells were detected by vaginal cytology. Vaginal cytology was stained according to Papanicolaou (6). Multifocal nodules in the uterus and

\* E-mail: bastan@veterinary.ankara.edu.tr

enlargements of the uterine wall were determined by ultrasound. Ovariohysterectomy was performed because of uterine and ovarian pathology. It was corrected by histopathologic examination of a hematoxylin and eosin-stained sample revealing uniform round cells containing eosinophilic cytoplasm and large nuclei with prominent, central located nucleoli. The masses in the uterus and ovaries originated from the vaginal tissue (Figures 1 and 2). After diagnosis, 0.025 mg/kg vincristine sulfate was administrated every 7 days for 4 weeks. The amount of hemorrhagic vulvar discharge decreased in the 4 days after the first administration and the clinical and vaginal cytology examinations confirmed that the bitch was cured totally after therapy.



Figure 1. Uterine and ovarian metastasis.

## Results and Discussion

The mass in the vagina was diagnosed by clinical signs and vaginal cytology showing that it was TVT. Uterine

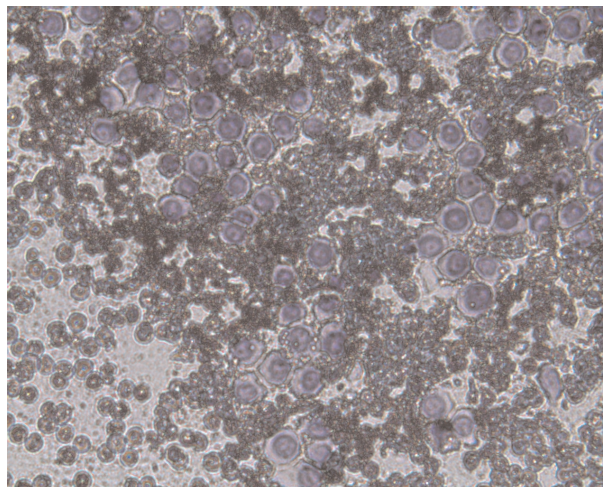


Figure 2. Cytological appearance of the vaginal mass.

and ovarian pathology was detected by ultrasonographic examination. The masses in the uterus and ovaries were described as TVT metastasis nodules by histopathological examination.

The most common site of metastasis is the regional lymph node, but distant nodes outside the expected lymphatic drainage pattern can also be involved. Skin and subcutaneous tissue have also been regularly reported sites of metastasis. Other sites include the lips, oral mucous membranes, tonsil, eye, liver, spleen, kidney, peritoneum, lung, musculature, and the central nervous system. In bitches, the tumor may spread directly to the internal genital tract, involving the cervix uterus and oviducts (4).

In conclusion, this case report shows that TVT can metastasize to the ovaries and uterus although it is rarely suggested.

## References

1. Madewell, B.R., Theilen, G.H.: Skin tumors of mesenchymal origin. In: Theilen, G.H., Madewell, B.R. Eds., *Veterinary Cancer Medicine*. 2nd edn., Lea & Febiger, Philadelphia. 1987; 282-309.
2. Nielsen, S.W., Kennedy, P.C.: Tumors of the genital systems. In: Moulton, J.E. Ed. *Tumors in Domestic Animals*. 3rd edn., University of California Press, 1990; 479- 517.
3. Higgins, D.A.: Observations on the canine transmissible venereal tumour as seen in the Bahamas. *Vet. Rec.*, 1966; 79: 67-71.
4. Rogers, K.S.: Transmissible venereal tumor. *Comp. Cont. Edu. Pract. Vet.*, 1997; 19: 1036-1045.
5. Mello Martins, M.I., Ferreira de Souza, F., Gobello, C.: The canine transmissible venereal tumor: etiology, pathology, diagnosis and treatment. In: Concannon, P.W., England, G., Verstegen, J., Linde-Forsberg, C. Eds. *Recent Advances in Small Animal Reproduction*. International Veterinary Information Service, Ithaca NY ([www.ivia.org](http://www.ivia.org)), 25-Apr-2005; A1233. 0405.
6. Papanicolaou, G.N.: A new procedure for staining vaginal smears. *Science*, 1942; 95: 438-439.