

Cryosurgical Treatment of Anal Sac Fistulae in Dogs*

Mehmet SAĞLAM**, Ümit KAYA

Department of Surgery, Faculty of Veterinary Medicine, Ankara University, 06110 Dışkapı, Ankara - TURKEY

Received: 04.01.2006

Abstract: Seven dogs of different breed, age, and sex that were diagnosed with anal sac fistulae upon clinical examination constituted the study material. Sedation for the procedure was maintained by means of xylazine hydrochloride administered intramuscularly. The patients were placed in the lateral recumbency position for the insertion into the fistulae of an appropriate probe, selected according to the lesion. Rapid cooling and spontaneous thawing were performed. This procedure was performed twice consecutively. The cooling temperature was adjusted to between -30 and -50 °C. The lesion healed completely between weeks 3 and 6 following the demarcation of necrotic tissue and growth of healthy granulation tissue. No postoperative antibiotic treatment was applied in any of the cases. Furthermore, during this period, no indicative clinical symptoms of haemorrhage, itching, or development of infection was observed. Various treatment options such as surgery and medical management are applied for the treatment of anal sac fistulae. The advantages of cryosurgical therapy in the perianal region are reported to include a low rate of recurrence, healing without any complication, ease of performance, no risk of haemorrhage, and prognosis ranging from good to excellent. According to the results from an evaluation of cases in this clinical study, cryosurgery was a more preferable option for the treatment of anal sac fistulae, when compared to surgical methods.

Key Words: Anal sacculitis, anal sac abscess, anal sac fistulae, cryosurgery, fistulae

Köpeklerde Anal Kесе Fistüllerin Krişürjikal Sađaltımı

Özet: Çalışma materyalini, klinik muayeneler sonucunda anal kese fistülü gelişimi belirlenen değişik ırk, yaş ve cinsiyette yedi köpek oluşturdu. Hastalarda xylazine hidroklorid kas içi uygulanarak prosedür için sedasyon sağlandı. Hastalar lateral pozisyonda masaya yatırılarak lezyona uygun olarak seçilen prob fistül üzerine yerleştirildi. Hızlı soğuma ve kendiliğinden olan çözülme gerçekleştirildi. Bu işlem aynı anda ard arda iki kez uygulandı. Soğuma ısısı -30 °C ile -50 °C derece olarak gerçekleştirildi. Yıkılan dokunun demarkasyonu ve sağlıklı granülasyon dokusunun şekillenmesiyle lezyondaki iyileşme 3-6. haftalar arasında tamamlandı. Olgularda postoperatif antibiyotik kullanılmadı. Ayrıca bu dönemde kanama, kaşınma ve enfeksiyon gelişimine ait klinik belirtiler gözlenmedi. Anal kese fistüllerinin sađaltımında medikal ve cerrahi uygulamalar gibi sađaltım yöntemlerinden söz edilebilir. Perianal bölgede krişürjikal sađaltımın avantajları ise; nüks oranının çok az olması, komplikasyonsuz iyileşme periyodu, uygulamada kolaylık, kanamanın olmayışı ve iyi'den mükemmel'e değişen prognoz olarak bildirilmektedir. Bu klinik çalışmada, hastaların değerlendirmesi sonucunda perianal fistüllerin sađaltımında krişürjinin cerrahi yöntemlere göre tercih edilebilir bir teknik olduğu belirlendi.

Anahtar Sözcükler: Anal kese yangısı, anal kese apsesi, anal kese fistülü, krişürji, fistül

Introduction

Anal sac impaction and abscessation constitute the most common perianal disease in dogs, especially in small breeds. Anatomically, the rectum, which forms the last part of the alimentary canal, opens to the exterior through the anus. The anus consists of 3 zones extending

from the cranial to the caudal, named the zona columnaris (5-12 mm), zona intermedia (0.5-1.5 mm), and zona cutanea. The zona cutanea is the transition zone between the anus and the skin. In dogs, it is bluish red and more than 4 cm wide. The main characteristics of this zone are the presence of Gil. circumanale (perianal glands), and the

* This study was conducted with the aid of a device purchased for a project supported by TÜBİTAK (project no. VHAG 639).

** E-mail: saglam@veterinary.ankara.edu.tr

opening of 2 ducts pertaining to the bilaterally located sinus paranales (anal sac) in cats and dogs (1-3). The paired perianal sacs are situated between the internal and external sphincter muscles at the 4-5 and 7-8 o'clock positions, and are invaginations of the inner cutaneous zone of the anus. In the dog, the anal sac duct opens into the lateral margin of the anus (4,5).

The exact cause of anal sac disease is not clearly understood. Stool consistency, decreased activity, weight, pudendal nerve dysfunction, glandular hypersecretion associated with generalised seborrhoea, perianal fistulae, and inflammatory bowel disease may play a role in anal sac disease development (6-8).

Naturally, the possibility of the opening part of the anal sacs' secretory ducts becoming contaminated with faeces during defecation is quite high. In certain cases, the secretion from the anal sacs forms a thin layer together with the remnants of accumulated faeces and other dirt originating from surrounding surfaces, and thereby causes infection and inflammation of the region. This, in turn, causes the retention of the contents of the anal sacs, and leads to the development of anal sac abscesses and fistulae, due to the resulting pressure necrosis and the disruption of the mucosa of the glands (9,10). Frequently observed cases of diarrhoea in dogs also contribute to the formation of the indicated thin film layer. Furthermore, the spread of infection from the abscessed anal sacs, presence of foreign substances, and traumas are also involved in the development of fistulae (10). Because the ductal opening is small, any cause of swelling in the perianal region may cause occlusion (5).

Anal sac inflammatory lesions are common in dogs. The 3 most common lesions characterised are impaction, sacculitis, and abscesses. Anal sacculitis and abscesses are seen more commonly in small breed dogs, with a higher incidence in chihuahuas and poodles. Diagnosis of anal sac diseases can be made on the basis of the history and physical examinations. Common clinical signs in these patients are scooting, licking and biting of the anal area and tail base, discomfort in sitting, painful defecation, and tenesmus (4,6,11,12).

The diagnosis of anal sac fistulae is not complicated and is confirmed by clinical signs, and visual and digital rectal examinations. Particularly in cases of fistulae of the anal sac, a fistulous structure is observed in the site of the indicated gland, ventrolateral to the anus. Other clinical symptoms that may be observed include constipation,

tenesmus, dyschezia, rectal or anal haemorrhage, weight loss, mucopurulent discharge, and irritation and continuous licking of the anal region (4-6,8,10).

Anal sacculitis, impaction, and abscessation are common in dogs. These conditions can be treated by gently expressing the anal sacs, applying a ceruminolytic agent or saline into the sac if the contents are too dry to express easily, hot packing or compress, local instillation of antibiotics, open drainage, and administering systemic antibiotics. Adding supplemental fibre to the diet may increase faecal bulk, facilitating anal sac compression and emptying. Surgical excision of the anal sacs often is required to treat recurrent or persistent anal sac diseases (4,5,8,12-14).

In the field of veterinary surgery, cryosurgical treatment applications were initiated with the studies by Borthwick in 1970. That researcher was the first to apply this method for the treatment of perianal fistulae in 1971 (15). Cryosurgery has been demonstrated to be effective in the treatment of lesions of the anal and perianal regions, and particularly the treatment of perianal fistulae (16,17). Greiner et al. (18) have reported the main treatment method for perianal fistulae to be cryosurgical applications.

The aim of the present clinical study was to evaluate the efficiency of cryosurgery in the treatment of anal sac fistulae, and to assess the results of cryosurgical applications from a clinical point of view.

Materials and Methods

Seven dogs referred to the Clinics of the Surgery Department of Ankara University, Faculty of Veterinary Medicine that were diagnosed with anal sac fistulae upon clinical examination and that received cryosurgical treatment constituted the study material (Table).

In this clinical study, a LIMSA MC-3000 digital model cryosurgical unit, which works based on the Joule-Thomson effect, was used. In the cryosurgery unit, comprising an electronic defrost system, a digital thermometer indicating the temperature of the probe, and probe tips of varying shapes and sizes appropriate for the fistulae, carbon dioxide was used as a freezing agent.

Adequate sedation for cryosurgical treatment was maintained in the animals by means of the intramuscular administration of xylazine hydrochloride (Rompun, 23.32

Table. Data of the clinical evaluations and results.

Case No:	Dog's			fistulae		Result
	Species	age	gender			
1	Terrier	3	F	Anal Sac Fistula	Right side	Recovery in 4 weeks
2	Poodle	6	F	Anal Sac Fistula	Right side	Recovery in 4 weeks
3	Pekinese	4.5	M	Bilateral Anal Sacs Fistulae	Right and Left	Recovery in 6 weeks
4	Pinscher	10	M	Anal Sac Fistula	Left side	Recovery in 4 weeks
6	Terrier	5	F	Anal Sac Fistula	Left side	Recovery in 3 weeks
7	Terrier	8	F	Anal Sac Fistula	Right side	Recovery in 4 weeks
8	Spaniel Cocker	10	M	Anal Sac Fistula	Left side	Recovery in 3 weeks

mg/ml, Bayer) at a dose of 2.2 mg/kg. The animals were placed in the lateral or sternal recumbency position. Perianal hair was clipped, and the area was cleaned with antiseptic solutions and prepared aseptically for cryosurgery, and the ducts of the fistulae were examined with stylets. Subsequently, the freezing procedure was performed by means of insertion of the cryoprobe, which is of appropriate shape and size for the fistulous lesion, and subsequent rapid cooling. The freeze-thawing process was performed twice, and the freezing temperature was adjusted to between -30 and -50 °C. Special attention was paid to protect the rectum during the application.

Following cryosurgical treatment, the region was left open without using any local or parenteral antibiotic, the animals were examined weekly, and the duration of healing was determined.

Results

In 7 of the cases referred to our clinics with the complaint of continuous licking and itching of the anal region, fistulae of the anal sacs were determined, and in 1 of these cases (case no. 3) both anal sacs were observed to be fistulous. As fistula development was noted in all cases, the disease was thought to be in the chronic period and caused by anal gland abscesses. No previous anal sac inflammation therapy was reported by the owner.

Upon the application of cryosurgical treatment in the cases following the maintenance of sedation, healing was achieved within 3 to 6 weeks, and neither recurrence nor any drainage tract was observed. Haemorrhaging did not occur while the cryosurgical applications were being

performed, and no licking or scratching of the region was observed during the healing process. However, we used an Elizabethan collar to protect the area in all cases. Cryosurgical treatment was not required a second time, and no local infection developed during the healing process. There were no complaints about any faecal incontinence problem from the owners.

Samples related to our cryosurgical treatment applications are shown in Figures 1-4.

Discussion

The diagnosis of anal sac fistulae is not complicated and is confirmed by clinical signs, and visual and digital rectal examinations. Particularly in cases of fistulae of the anal sac, a fistulous structure is observed at the site of the indicated anal sac, ventrolateral to the anus. Other clinical symptoms that may be observed include constipation, tenesmus, dyschezia, rectal or anal haemorrhage, weight loss, mucopurulent discharge, and irritation and continuous licking of the anal region (4-6,8,10).

Upon clinical examination for determination of localisation of the anal sac fistulae and evaluation of local symptoms, fistulae were diagnosed in the anal sacs in 7 cases. The clinical symptoms observed included anal irritation and continuous licking of the region, and in 1 case (case no. 5) dyschezia.

Results suggest that anal saccullectomy is a safe and effective treatment for non-neoplastic anal sac diseases in dogs and is associated with a low rate of complications. The standard open technique was associated with the greatest number of complications, whereas complication

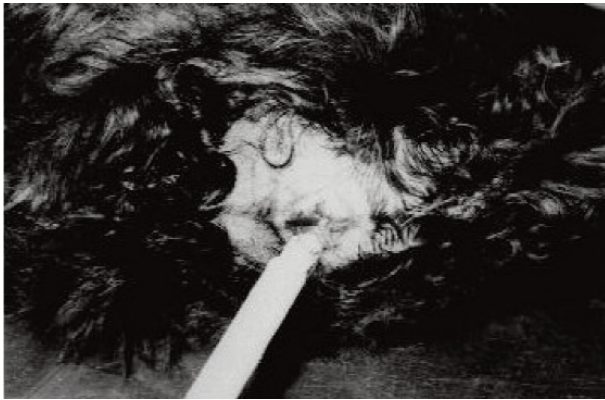

Figure 1. Showing the 2nd case treatment with probe.

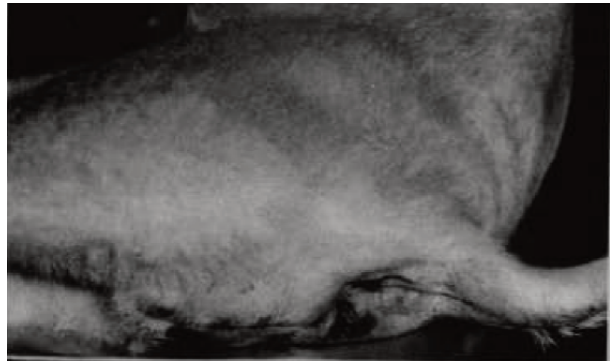


Figure 2. Showing the 7th case before treatment.




Figure 3. Showing the 7th case treatment with probe.

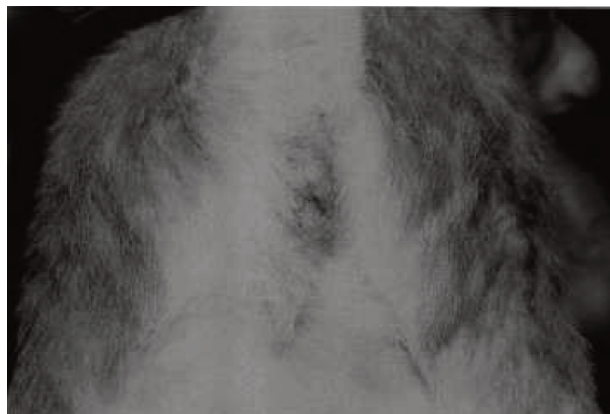


Figure 4. Completion of healing in week 4 in the 7th case.

rates for the closed and modified open techniques were similar to each other (19).

A technique is described for impregnating canine anal sacs with dental mould material. After the mould has set the sacs can be ablated surgically. The method is efficient, quick, and simple (20). A Foley catheter was also used for the same purpose. The Foley catheter was easy to place into the anal sac, and when distended it effectively outlined the dimensions of the anal sac for the surgeon (14).

In the cryosurgical treatment of perianal region fistulae, freezing with a cryoprobe (insertion of the probe inside the lesion and peripheral freezing of the tip of the probe) is applied by using appropriate cryosurgical units (16,18,21,22). In order to ensure the complete necrosis of the frozen tissue according to the indicated method, 3 conditions must be met. These conditions are: 1)

Immediate lowering of the temperature to between -20 and -30 °C; 2) Self-thawing without any external intervention; 3) Replication of the freeze-thawing procedure 2-3 times. The cryolesion is a freezing of second or third degree, and tends to result in self-cicatrisation. Infection does not develop (22). In cryosurgical applications, the risk of haemorrhage is minimal, and the possibility of the recurrence of the fistulae is very low. The frozen tissue necroses within 7-14 days, and as a result of demarcation healing is observed to develop with peripheral epithelisation. Healing is completed within 6-10 weeks. When required, the application may be repeated after 4-8 weeks (10,16,18).

Withrow et al. (22), based on their treatment of perianal fistulae by means of the cryoprobe method, have reported the possibility of faecal incontinence to be quite

low following such applications, due to the nervous system of the anal sphincter not being affected by the freezing process. According to the same researchers, the growth of healthy granulation tissue in the lesion and full healing require 10-14 days and 8-10 weeks, respectively.

The advantages of the use of cryosurgery for treatment of perianal fistulae include the low rate of recurrence, low possibility of faecal incontinence, ease of performance, short period of application, minimal blood loss, and a prognosis ranging from good to excellent (22,23).

In the present clinical study, the cryosurgery unit of the Surgery Department was used for the treatment of anal sac fistulae. Upon weekly controls performed in evaluated cases following applications, growth of healthy

granulation tissue as a result of demarcation of damaged tissue was determined in examinations performed on day 14, whereas healing was completed within 3-6 weeks.

In the evaluation of our cases, no complications or, despite no local or parenteral antibiotics being used, development of infection was observed following cryosurgical applications. Cryosurgery was determined to be an easier and more reliable method for treatment of perianal fistulae when compared to conventional surgical methods, and, with respect to the location of anal region, was demonstrated to have advantages such as no development of infection.

As a result of this clinical study, in the field of small animal surgery, cryosurgery was concluded to be a preferable method for the treatment of anal sac fistulae.

References

1. Getty, R.: Sisson and Grossman's Anatomy of the Domestic Animals. W.B. Saunders Company, Philadelphia. 1975; 1553-1554.
2. Miller, M.E., Christensen, G.C., Evans, H.E.: Anatomy of the Dog. W.B. Saunders Company, Philadelphia. 1975; 694-697.
3. Nickel, R., Schummer, A., Seiferle, E.: The Viscera of the Domestic Mammals. Verlag Paul Parey, Berlin. 1979; 130-132.
4. Fossum, T.W.: Small Animal Surgery. Mosby-Year Book, St. Louis. 1997; 348-352.
5. Aronson, L.: Rectum and Anus. In: Slatter, D. Ed., Textbook of Small Animal Surgery. Vol. I. W.B. Saunders. Philadelphia. 2003; 682-708.
6. Matthiesen, D.T., Maretta, S.M.: Disease of Anus and Rectum. In: Slatter, D. Ed., Textbook of Small Animal Surgery. Vol. I. W.B. Saunders. Philadelphia. 1993; 627-645.
7. Thompson, M.S.: Disease of the Anal Sacs. In: Kirk, R.W. Ed., Current Veterinary Therapy. XIII: Small Animal Practice. W.B. Saunders. Philadelphia, 2000; 591.
8. Aiellio, S.E.: The Merck Veterinary Manual. 8th edn., Merck, 1998; 147
9. Budsberg, S.C., Spurgeon, T.L., Liggitt, H.D.: Anatomic predisposition to perianal fistulae formation in the German shepherd dog. Am. J. Vet. Res., 1985; 46: 1468-1472.
10. Harvey, C.E.: Perianal fistula in the dog. Vet. Rec., 1972; 91: 25-33.
11. Niebauer, G.W.: Rectum, Anus and Perianal and Perianal Regions. In: Harvey C.E., Newton, C.D., Schwartz, A. Eds., Small Animal Surgery. J.B. Lippincott Company, Philadelphia, 1990; 381-402.
12. Washabau, A.J., Brockman, D.J.: Recto-Anal Disease. In: Ettinger, S.J., Fieldman, E.C. Eds., Textbook of Veterinary Internal Medicine, 4th edn. W.B. Saunders. Philadelphia, 1994; 1398.
13. Van Duijkeren, E.J.: Disease conditions of canine anal sacs. J. Small Anim. Pract., 1995; 36: 12-16.
14. Downs, M.O., Stampley A.R.: Use of a Foley catheter to facilitate anal sac removal in the dog. J. Am. Anim. Hosp. Assoc., 1998; 34: 395-397.
15. Casieux, A., Ducret, J., Mirande-Ducret, D.: La cryochirurgie. Applications pratiques chez l'animal. Revue Med. Vet., 1980; 131: 203-208.
16. Liska, W.D., Greiner, T.P., Withrow, S.J.: Symposium on surgical techniques in small animal practice. Cryosurgery in the treatment of perianal fistulae. Vet. Clin. North Am., 1975; 5: 449-456.
17. Bellangeon, M.: Cryochirurgie et médecine vétérinaire. Sci. Vét. Méd. Comp., 1985; 87: 41-48.
18. Greiner, T.P., Liska, W.D., Withrow, S.J.: Symposium on surgical techniques in small animal practice. Cryosurgery. Vet. Clin. North Am., 1975; 5: 565-581.
19. Hill, L.N., Smeak, D.D.: Open versus closed bilateral anal sacculotomy for treatment of non-neoplastic anal sac disease in dogs: 95 cases (1969-1994). J. Am. Vet. Med. Assoc., 2002, 221: 662-665.
20. Tirgari, M.: A simple, clean method for the surgical ablation of anal sacs in dogs. Vet Rec., 1988, 123: 365-366.
21. Goldstein, R.S.: Nitrous oxide cryosurgical units; their use in veterinary practice. Vet. Med. Small Anim. Clin., 1977; 72: 1587-1592.
22. Withrow, S.J., Greiner, T.P., Liska, W.D.: Cryosurgery: veterinary consideration. J. Am. Anim. Hosp. Assoc., 1975; 11: 271-282.
23. Harkin, K.R., Walshaw, R., Mullaney, T.P.: Association of perianal fistula and colitis in the German shepherd dog: response to high-dose prednisone and dietary therapy. J. Am. Anim. Hosp. Assoc. 1996; 32: 515-520.