

Morphology and Arterial Vasculature of Donkey (*Equus asinus* L.) Adrenal Gland

Emine KARAKURUM¹, Özcan ÖZGEL^{1,*}, Nejdet DURSUN²

¹Department of Anatomy, Faculty of Veterinary Medicine, Mehmet Akif Ersoy University, 15100, Burdur - TURKEY

²Department of Anatomy, Faculty of Veterinary Medicine, Ankara University, 06110-Dışkapı, Ankara - TURKEY

Received: 05.04.2007

Abstract: In this study, the shape, localization, and arterial vascularization of the gl. adrenalis were examined in 6 donkeys. It was observed that the internal side of the gl. adrenalis sinistra was located against the aorta abdominalis and the caudal aspect of the gland was in the ventral aspect of the a. renalis sinistra. The length of the left adrenal gland was approximately 41.49-47.44 mm, while its width was about 21.70-26.24 mm, and the thickness was nearly 4.65-7.56 mm. The shape of the left adrenal gland was oval or nearly circular. The gl. adrenalis sinistra was vascularized by the rr. adrenalis caudales and a. adrenalis media that were separated from the ventral side of the aorta abdominalis. The latter took part in the vascularization of both materials. The vena cava caudalis was seen in the ventral side of the gl. adrenalis dextra, and the cranial border of the gland was seen in contact with the renal impression of the liver. The right a. renalis was observed on the caudal border of the gland. The length of the right adrenal gland was approximately 43.13-56.49 mm, while the width was about 14.40-30.27 mm, and the thickness was nearly 4.74-7.68 mm. The general shape of the right adrenal gland was ranging from oval to nearly circular in outlines; however, a typical bean shape was seen only in one specimen and an elliptical gland was seen in another specimen. The gl. adrenalis sinistra was vascularized by the rr. adrenaes caudales and a. adrenalis media, the latter was originated from the ventral aspect of the aorta abdominalis to participate partly in the vascularization of this gland in a specimen.

Key Words: Donkey, adrenal gland, morphology, vasculature

Merkep (*Equus asinus* L.) Glandula Adrenalis'inin Morfolojisi ve Damarlaşması

Özet: Bu çalışmada 6 adet merkepte glandula suprarenalis'in şekli, yerleşim yeri ve arteriel vaskularizasyonu incelendi. Glandula adrenalis sinistra'nın medial kenarının aorta abdominalis'e dayanmış olduğu, bezin caudal ucunun da sol arteria renalis'in ventral'inde olduğu gözlemlendi. Sol adrenal bezin uzunluğunun yaklaşık 41.49-47.44 mm, genişliğinin yaklaşık 21.70-26.24 mm, kalınlığının da yaklaşık olarak 4.65-7.56 mm arasında bulunduğu belirlendi. Şeklinin oval ya da yuvarlağa yakın olduğu saptandı. Glandula adrenalis sinistra'yı rr. adrenaes caudales'in vaskularize ettiği, iki adet materyalde de vaskularizasyona aorta abdominalis'in ventral yüzünden ayrılan a. adrenalis media'nın katıldığı tespit edildi. Glandula adrenalis dextra'nın ventral yüzünde vena cava caudalis'in seyrettiği, cranial ucunun karaciğerin impressio renalis'ine temas ettiği, caudal ucunun üzerinde sağ arteria renalis'in olduğu belirlendi. Sağ adrenal bezin uzunluğunun yaklaşık 43.13-56.49 mm, genişliğinin yaklaşık 14.40-30.27 mm, kalınlığının da yaklaşık olarak 4.74-7.68 mm arasında olduğu saptandı. Bezin şeklinin oval veya yuvarlağa yakın, bir materyalde fasulye, bir diğerinde de uzunlamasına elips şeklinde olduğu gözlemlendi. Glandula adrenalis dextra'yı rr. adrenaes caudales'in vaskularize ettiği, bir adet materyalde de vaskularizasyona aorta abdominalis'ten ayrılan a.adrenalis media'nın katıldığı tespit edildi.

Anahtar Sözcükler: Merkep, adrenal bez, morfoloji, damarlaşma

Introduction

In domestic mammals, the right and left adrenal glands are located near the craniomedial border of the kidneys (1-3). In man, they are situated on the upper poles of the kidneys (4).

The shape of the adrenal gland varies with species. It is mostly oblate oval or triangular (1). In ruminants the right and left adrenal glands somewhat resemble the letters V and C, respectively, whereas in horses, the right adrenal gland is similar to a flat and irregular letter J or a comma,

* E-mail: ozcangel@hotmail.com

and the left adrenal gland is flat and long with a tongue-like shape; on the other hand, the adrenal glands are either long and cylindrical or somewhat oval or triangular in pigs (2). In ferrets the left adrenal gland is oval, and the right adrenal gland is longer than the left (5), whereas in rabbits, the right adrenal gland is long and resembles a large grain of rice, and the left adrenal gland is either oval or almost circular (6). In man the right adrenal gland resembles a 3-sided pyramid, and the left one has a lunate shape (4).

The colour of the adrenal glands is brown in equidae and ruminants; reddish-brown in pigs, due to their low fat content (1,2,7), greyish white in rabbits (6), and yellowish in man and carnivores (1,4).

The cranial aspect of the ventral surface of each adrenal gland is covered by the peritoneum. The remainder parts are surrounded by adipose tissue and loose connective tissue, and the caudal aspect is embedded in perirenal adipose tissue. The adrenal glands develop in well-vascularized areas, and when compared to the organs of similar size, excluding the thyroid, they display a very high rate of blood flow (3).

The adrenal glands receive one or more branches from large arterial roots passing nearby (3). These adrenal branches are directly given off by the aorta (a. adrenalis media), a. renalis (rr. adrenales caudales), a. phrenica (r. adrenalis cranialis), aa. lumbales, or by the a. phrenica accessoria (2,3,5,6,8-11). More rarely, branches originating from the a. mesenterica cranialis and a. celiaca contribute to the arterial vascularization of the adrenal glands (9-13).

While branches originating from the a. mesenterica cranialis and a. celiaca terminate in the cranial aspect of the adrenal glands, branches originating from the a. renalis and aa. lumbales enter the caudal part of the glands (3).

In rabbits, a fine a. adrenalis originating from the a. suprarenolumbalis, a branch of the a. renalis, contributes to the arterial supply of the adrenal glands (14).

According to the available literature, there was not adequate information on the donkey adrenal glands; therefore, the current study was conducted to highlight the morphology and arterial vascularization of gl. adrenalis in this animal.

Materials and Methods

Donkeys offered to carnivorous animals as a source of nutrition in the Ankara Zoo constituted the study material.

For this purpose, the diaphragm and abdominal organs of 6 male donkeys were transferred to the laboratory. Following the washing of the blood vessels by means of the injection of the aorta abdominalis with physiological saline, latex coloured with red rotring ink was injected. The material prepared was kept at +4 °C for 24 h so as to ensure the freezing of latex, and stored in 10% formalin until dissection. Images of the findings obtained were taken by a Nikon Coolpix 4300 camera. The anatomical terminology used conforms to the edition of *Nomina Anatomica Veterinaria* published in 2005 (15).

Results

The gl. adrenalis sinistra was oval or almost circular. It was observed to be localized within the angle formed by the aorta abdominalis and a. renalis sinistra, and to overlap the aorta abdominalis with its cranial aspect situated on the left lobe of the pancreas, and its caudal aspect was located ventral to the a. renalis sinistra (Figure 1.3).

The cranial aspect of the gl. adrenalis dextra was seen to overlap the renal impression of the liver, whereas the right a. renalis sinistra was demonstrated to run along its caudal aspect, and the vena cava caudalis was observed to exist on its ventral surface (Figure 1.2). Furthermore, the shape of the gland was generally oval or almost circular, resembling a bean in one animal, and was transversally elliptical in another one (Table).

Rami adrenales caudales

In 3 of the examined materials, the vascularization of both of the gl. adrenales was determined to be supplied by the a. renalis itself and rr. adrenales caudales, originating from its branches (Figures 2.3 and 3.3).

A. adrenalis media

In only one of the studied animals, the vascularization of both adrenal glands was determined to be supplied by the a. adrenalis media, which has its origin at the ventral wall of the aorta abdominalis (Figures 1.4, 2.4, and 3.2). Two aa. adrenales media were determined to terminate in the gl. adrenalis sinistra, whereas one a. adrenalis media was determined to enter the gl. adrenalis dextra.

In a material, 3 branches and in another one 2 branches originating from an artery given off by the aorta abdominalis between the a. celiaca and a. mesenterica cranialis were determined to contribute to the vascularization of the gl. adrenalis sinistra (Figure 2.10).

Table. Certain morphometric measurements of the right and left adrenal glands.

	Gl. adrenalis dextra	Gl. adrenalis sinistra
Craniocaudal length	43.13-56.49 mm	41.49-47.44 mm
Mediolateral width	14.40-30.27 mm	21.70-26.24 mm
Dorsoventral thickness	4.74-7.68 mm	4.65-7.56 mm

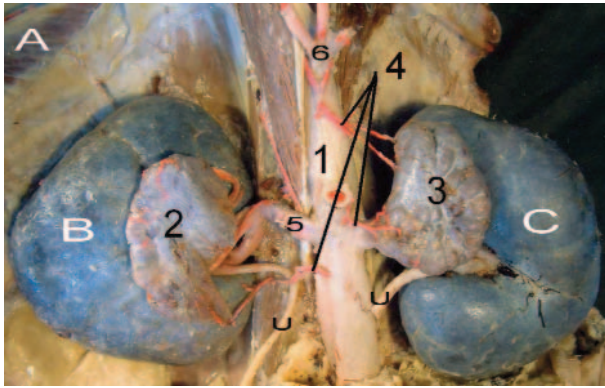


Figure 1. 1: Aorta abdominalis, 2: Gl. adrenalis dextra, 3: Gl. adrenalis sinistra, 4: A. adrenalis media, 5: A. renalis dextra, 6: A. celiaca, A: Diaphragma, B: Ren dexter, C: Ren sinister, U: Ureter.

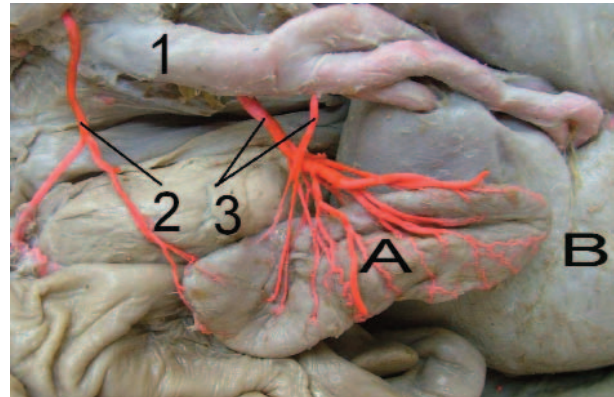


Figure 3. 1: A. renalis sinister, 2: A. adrenalis media, 3: Rr. adrenales caudales, A: Gl. adrenalis sinister, B: Ren sinister.

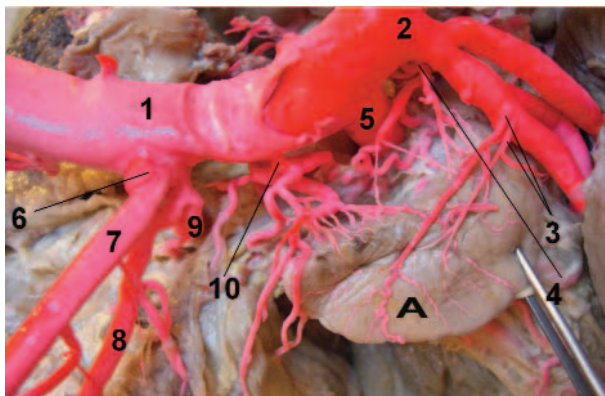


Figure 2. 1: Aorta abdominalis, 2: A. renalis sinistra, 3: Rr. adrenales caudales, 4: A. adrenalis media, 5: A. mesenterica cranialis, 6: A. celiaca, 7: A. lienalis, 8: A. gastrica sinistra, 9: A. hepatica, 10: An artery given off by the aorta abdominalis between the a. celiaca and a. mesenterica cranialis A: Gl. adrenalis sinistra.

In the first material, 3 branches originating from an artery given off by the aorta abdominalis between the a. celiaca and a. mesenterica cranialis were demonstrated to terminate in the front and middle part of the medial border of the gl. adrenalis sinistra after dividing into 2-6 branches. Similarly, 5 rr. adrenales caudales originating from the

a. renalis sinistra were determined to enter the dorsal surface of this gland after dividing into 2 - 4 branches. One a. adrenalis media originating from the ventral wall of the aorta abdominalis, at a distance of 0.2 cm medial to the origin of the a. renalis sinistra, was demonstrated to terminate in the dorsal surface of the gland. In this material, the arterial vascularization of the gl. adrenalis dextra was determined to be supplied by 4 rr. adrenales caudales originating from the a. renalis dextra. Two of the branches originating from the a. renalis dextra were determined to enter the medial border of the right adrenal gland after dividing into 2 branches, whereas 2 were demonstrated to terminate in the dorsal surface of the gland after dividing into 2-4 branches.

In the second material, 2 branches originating from an artery given off by the aorta abdominalis between the a. celiaca and a. mesenterica cranialis were determined to enter the dorsomedial surface of the cranial aspect of the gland after dividing into 2-3 branches (Figure 2.10). Furthermore, in this material, 1 rr. adrenales caudales originating from the a. renalis sinistra was demonstrated to supply the gl. adrenalis sinistra. This branch was observed to terminate in the dorsal surface of the gland

after dividing into 2. One a.adrenalis media originating from the ventral wall of the aorta abdominalis, at a distance of 1.4 cm caudal to the origin of the a. renalis sinistra, was determined to enter the ventral surface and medial border of the caudal aspect of the gland. In this material, the arterial vascularization of the gl. adrenalis dextra was demonstrated to be supplied by the a. renalis dextra itself and 2 rr. adrenales caudales originating from its branches, as well as 1 a. adrenalis media originating from the ventral wall of the aorta abdominalis at a distance of 0.8 cm caudal to the origin of the a. renalis dextra. One branch given off by the a.renalis dextra was determined to terminate in the dorsal surface of the gl. adrenalis dextra after dividing into 5 branches. The other branch given off by the branch of the a. renalis dextra was demonstrated to enter the dorsal surface of the gland, near the caudal aspect, after dividing into 2 branches.

In both materials, the artery originating from the aorta abdominalis between the a. celiaca and a. mesenterica cranialis was determined to give branches to surrounding tissues, in addition to 2-3 branches it provides for the gl. adrenalis sinistra (Figure 2.10).

Discussion

In literature (1-3) the right and left adrenal glands are reported to be located on the medial surface of the cranial border of both kidneys, whereas in man (4) they are reported to be situated on the upper poles of the kidneys. In this study, the gl. adrenalis sinistra was determined to be located within the angle formed by the aorta abdominalis and a. renalis sinistra, and to overlap the aorta abdominalis with its cranial aspect situated on the left lobe of the pancreas, and its caudal aspect located ventral to the a. renalis sinistra, whereas the cranial aspect of the gl. adrenalis dextra was demonstrated to overlap the impressio renalis of the liver, the right a. renalis was determined to extend along its caudal aspect and the vena cava caudalis was observed to exist on its ventral surface.

Similar to the reports of Dursun (1) and Sisson and Grossman (7) on equidae and ruminants, both of the adrenal glands were determined to be brown.

The shape of the gl. adrenalis sinistra and gl. adrenalis dextra was determined to be oval as also reported in ferrets (5) and sometimes in pigs (2).

In this study, similarly to the reports of Holmes (5), Getty (2), Nickel et al. (10), and Dyce et al., (11), the a. adrenalis media originating from the aorta, and the rr. adrenales caudales given off from the a. renalis were demonstrated to contribute to the arterial supply of both adrenal glands.

In conclusion, the gl. adrenalis sinistra was demonstrated to be located within the angle formed by the aorta abdominalis and a. renalis sinistra, and to overlap the aorta abdominalis with its cranial aspect situated on the left lobe of the pancreas, and its caudal aspect located ventral to the a.renalis sinistra. Its shape was determined to be oval or almost circular. The arterial vascularization of the gl. adrenalis sinistra was determined to be supplied by the rr. adrenales caudales, whereas in 2 materials, the a.adrenalis media given off from the ventral wall of the aorta abdominalis was demonstrated to contribute to the vascularization of this gland.

The cranial aspect of the gl. adrenalis dextra was determined to overlap the impressio renalis of the liver, whereas the a. renalis dextra was demonstrated to run along its caudal aspect, and the vena cava caudalis was observed to exist on its ventral surface. Furthermore, the shape of the gland was generally determined to be oval or almost circular, to resemble a bean in one material, and to be transversally elliptic in another material. The arterial vascularization of the gl. adrenalis dextra was determined to be supplied by the rr. adrenales caudales. In one material, the a. adrenalis media, given off from the ventral surface of the aorta abdominalis, was also demonstrated to contribute to the vascularization of the gland.

References

1. Dursun, N.: Veteriner Anatomi II. Medisan Yayınevi, Ankara. 1999; 184-185.
2. Getty, R.: Sisson and Grossman's The Anatomy of the Domestic Animals. Fifth edn., W.B. Saunders Company, Philadelphia. 1975; 957-958.
3. Miller, M.E., Christensen, G.C., Evans, H.E.: Anatomy of the Dog. W.B. Saunders Company. Philadelphia. 1965; 826-827.
4. Arıncı, K., Elhan, A.: Anatomi – 1. Cilt. Güneş Yayınevi, Ankara. 1995; 445-448.
5. Holmes, R.L.: The adrenal glands of the ferret, (*Mustela putorius*). J. Anat., 1961; 95: 325-336.

6. Dursun, N., Bozkurt, E.U. Ozgel, O.: The suprarenal glands and their arterial vascularization in New Zealand rabbit (*Oryctolagus cuniculus* L.). Ankara Üniv. Vet. Fak. Derg., 2001; 48: 21-25. (article in Turkish with an abstract in English)
7. Sisson, S., Grossman, J.M.: The Anatomy of the Domestic Animals. Fourth edn., W.B. Saunders Company, Philadelphia and London. 1953; 573.
8. Çakır, A.: Comparative anatomical investigations on the aorta abdominalis and its branches of domestic cat and New Zealand rabbit. PhD Thesis, Ankara University. Ankara. 1991; 25-44.
9. Hossain, M.I.: The arterial supply to the adrenal gland of the black Bengal she-goat. Res. Vet. Sci., 1972; 13: 282-283.
10. Nickel, R., Schummer, A., Seiferle, E.: The Anatomy of the Domestic Animals, Volume 3, Verlag Paul Parey, Hamburg. 1981; 175.
11. Dyce, K.M., Sack, W.O., Wensing, C.J.G.: Textbook of Veterinary Anatomy. Saunders Company. Third edn., An Imprint of Elsevier Science, London. 2002; 215-216.
12. Harrison, F.A., McDonald, I.R.: The arterial supply to the adrenal gland of the sheep. J. Anat., 1966; 100: 189-202.
13. Karadağ, H.: The arterial supply to the left adrenal gland of sheep and goat. Turk. J. Vet. Anim. Sci., 1994; 18: 153-155.
14. Craigie, E.H.: Bensley's Practical Anatomy of the Rabbit. Eighth edn., University of Toronto Press, Toronto. 1969; 132-133.
15. Nomina Anatomica Veterinaria: Prepared by the International Committee on Veterinary Gross Anatomical Nomenclature (I.C.V.G.A.N.) Published by the Editorial Committee, Hannover. 2005; 89-91.