

Disseminated *Streptococcus equi* subsp. *zoepidemicus* Infection in a Foal and Associated Mastitis in a Mare

A. Levent KOCABIYIK¹, Esra BÜYÜKCANGAZ^{1,**}, Ahmet AKKOÇ², Cüneyt ÖZAKIN³, İ. Taci CANGÜL²

¹Department of Microbiology, Faculty of Veterinary Medicine, Uludağ University, 16059 Görükle, Bursa - TURKEY

²Department of Pathology, Faculty of Veterinary Medicine, Uludağ University, 16059 Görükle, Bursa - TURKEY

³Department of Microbiology and Infectious Diseases, Faculty of Medicine, Uludağ University, 16059 Görükle, Bursa - TURKEY

Received: 09.08.2007

Abstract: A systemic infection with *Streptococcus equi* subsp. *zoepidemicus* is described in a 22-day-old female foal for the first time in Turkey. Clinically the foal was in poor condition and had severe pneumonia. Painful swellings of the carpal and tarsal joints were evident. Examination of the dam revealed clinical mastitis. Postmortem histopathological and microbiological examinations of samples from the foal revealed a disseminated infection with *S. equi* subsp. *zoepidemicus*. The causative agent was also recovered in pure culture from a milk sample of the mare.

Key Words: Septicaemia, foal, mastitis, mare, *Streptococcus equi* subsp. *zoepidemicus*

Bir Tayda Yaygın *Streptococcus equi* subsp. *zoepidemicus* Septisemisi ve Kısırakta Buna Bağlı Oluşan Mastitis Olgusu

Özet: Sunulan raporda Türkiye'de ilk defa olmak üzere 22 günlük dişi bir tayda sistemik *Streptococcus equi* subsp. *zoepidemicus* enfeksiyonu tanımlanmaktadır. Tay klinik olarak zayıf yapıydı ve şiddetli pnömoni bulguları taşıyordu. Karpal ve tarsal eklemlerde ağrılı şişlikler vardı. Annesinin klinik muayenesinde mastitis tespit edildi. Tayın postmortem histopatolojik ve mikrobiyolojik incelemesinde şiddetli *S. equi* subsp. *zoepidemicus* enfeksiyonu tanısı kondu. Etken saf kültür halinde mastitisli kısırığın süt örneğinden de izole edildi.

Anahtar Sözcükler: Septisemi, tay, mastitis, kısırak, *Streptococcus equi* subsp. *zoepidemicus*

Introduction

Mastitis is a rarely encountered condition in equidae (1). Although it may occur at any time, it is more frequently encountered during lactation (2). The disease can be caused by fungi (3) and nematodes (4), but in most cases bacteria are the causal agents, particularly beta-haemolytic streptococci (2).

Septicaemia is an important cause of death in foals (5,6). Foals may be infected in utero, during parturition, or during the early neonatal period (5-7). The most frequently isolated agents from septicemic foals are Gram-negative bacteria (8).

In the present study, *Streptococcus equi* subsp. *zoepidemicus* mastitis in a mare and fatal septicaemia in her foal are reported.

Case History

The body of a 22-day-old, female, Dutch Warmblood foal was brought to the Department of Pathology for postmortem examination. There were limited details available regarding history of the illness of the foal. Prior to the foal's death clinical signs exhibited had included respiratory distress, swelling of carpal and tarsal joints, and inappetence. No treatment had been attempted. A complete necropsy was performed. Tissue samples were collected from the liver, lung, heart, kidney, and mediastinal and hepatic lymph nodes, fixed in formalin, and processed routinely.

Swabs taken of the lung and liver abscesses, and pleural and synovial fluids were submitted for microbiologic examination. Two days after the death of the foal, a milk

* In memory of A. Levent KOCABIYIK

** E-mail: kocakaya@uludag.edu.tr

sample taken from the dam was referred for evaluation. The mare was reported to have normal pulse and respiration rates but an elevated rectal temperature (39.5 °C), and a positive California Mastitis Test (score 2). The left half of the udder was oedematous, hot, and elicited a pain response on palpation. The milk was thick and yellow. No treatment of the mare was reported.

Direct smears for Gram staining were prepared from the tissues from the foal and the milk sample from the mare. For bacteriologic examination, samples were plated onto 7% sheep blood agar (Oxoid® Ltd., Basingstoke, UK) and MacConkey agar and incubated overnight at 37 °C under aerobic conditions. For detection of obligate anaerobic bacteria, blood agar and Wilkins-Chalgren agar (Oxoid®) were incubated for 3 days under anaerobic conditions. Fungal cultures were conducted by plating samples onto Sabouraud dextrose agar (Oxoid) and incubating the plates at 25 °C and 37 °C in the dark for 3 weeks. Bacterial isolates were identified based on colonial and microscopic morphology, Gram stain reaction, and biochemical characteristics using standard procedures (9) and BBL™ Crystal™ Gram-Positive Identification System (BD Diagnostic Systems, Sparks, MD, USA). A Christie, Atkin, Munch-Peterson (CAMP) test was performed using a beta-toxin producing *Staphylococcus aureus* as previously described (9). Antimicrobial susceptibility evaluation was performed using antimicrobial impregnated disks (Oxoid) by the Kirby-Bauer disk diffusion method (10) on Mueller-Hinton agar (Oxoid). Plates were incubated aerobically at 37 °C for a minimum of 18 h.

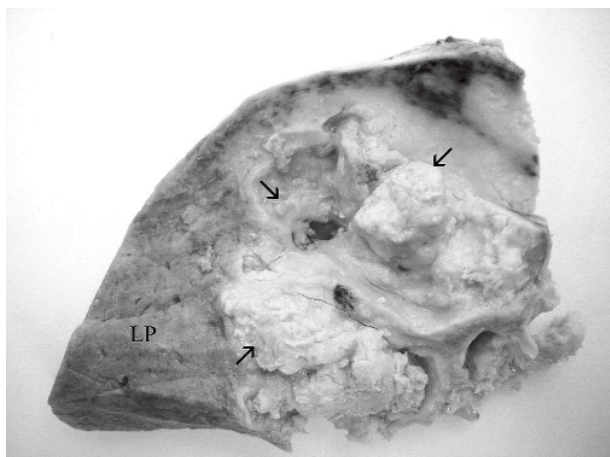


Figure 1. Section of liver containing numerous disseminated, raised, round to oval abscesses (arrows) of various size replacing the liver parenchyma (LP).

Results and Discussion

At necropsy, both carpal and both tarsal joints contained a purulent material. The liver contained disseminated, raised, round to oval coalescing abscesses varying in size from 1 to 7.5 cm in diameter (Figure 1). On the cut surface, the abscesses contained white to tan caseous material. Similar abscesses were found within all lung lobes and mediastinal lymph nodes. Severe pyothorax with adhesions between the parietal pleura and lung lobes was observed.

Haematoxylin-eosin stained sections of the liver and lung contained multiple, variably sized abscesses, characterised by central zones of caseous necrosis and cellular debris, surrounded by degenerate and intact neutrophils, lymphocytes, plasma cells and macrophages (Figure 2). The cytoplasm of macrophages contained abundant lightly eosinophilic foamy material and occasional large, clear vacuoles containing basophilic granular material. Necrotic areas were surrounded by a wide zone of proliferating fibroblasts. In liver sections, the hepatic parenchyma was compressed and displaced by variable sized large abscesses. Similar abscesses were evident in sections of mediastinal and hepatic lymph nodes. No pathology was observed in the heart.

In direct smears, a long chain of Gram-positive cocci appeared after Gram staining. A pure culture of beta-haemolytic colonies was recovered on blood agar inoculated with all samples taken from the foal and the milk sample from the dam. The colonies were translucent and

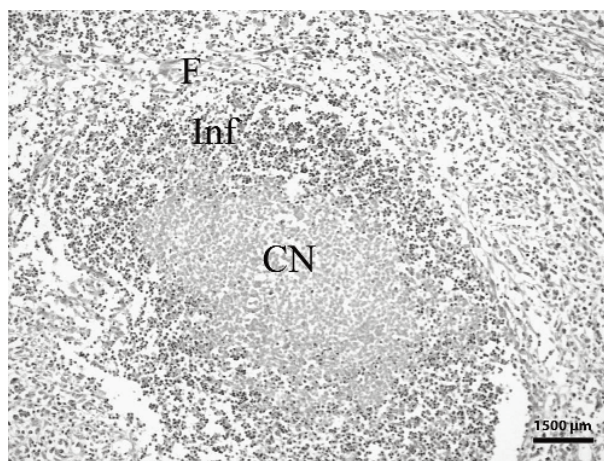


Figure 2. Central caseous necrosis (CN) and cellular debris surrounded by mixed infiltration of inflammatory cells (Inf) and an outer rim of fibroblasts (F) in the liver. Haematoxylin-eosin stain, bar = 1500 µm.

approximately 1 mm in diameter. These Gram-positive, catalase-negative cocci arranged in chains were identified as streptococci. The carbohydrate fermentation results for sorbitol, lactose, salicin, and ribose were positive and for trehalose, inulin, raffinose, and mannitol were negative using BBL™ Crystal™ Gram-Positive Identification System. Isolates were also unable to hydrolyse aesculin or sodium hippurate and gave a negative CAMP reaction. Based on these characteristics, isolates from the foal and milk samples were identified as *S. equi* subsp. *zooepidemicus*. No colonies were observed under different atmospheric conditions. *S. equi* subsp. *zooepidemicus* isolates from the foal and the milk samples were susceptible to amoxicillin/clavulanic acid, ampicillin, bacitracin, chloramphenicol, enrofloxacin, erythromycin, gentamicin, oxytetracycline, penicillin G, and trimethoprim/sulphamethoxazole, but resistant to kanamycin, neomycin, and streptomycin.

Several species of bacteria have been identified as agents of equine mastitis, including *Pseudomonas aeruginosa* (11), *Corynebacterium pseudotuberculosis* (12), haemolytic staphylococci (13), and beta-haemolytic streptococci (13-16). *Streptococcus equi* subsp. *zooepidemicus*, a beta-haemolytic Lancefield group C *Streptococcus*, is a normal resident in the lower genital tract of mares and can cause opportunistic infections such as abortion (17). *Streptococcus equi* subsp. *zooepidemicus* has recently been reported from an aborted equine foetus in Turkey for the first time (18).

Septicaemia is an important cause of mortality in neonatal foals and a common cause of death in critically ill foals, regardless of their primary disease (5,6). It has been estimated that 33% of deaths in thoroughbred foals up to

3 months of age are attributable to septicaemia (19). Affected foals may be ill at birth or they may appear clinically normal initially and then develop signs of illness during the first few hours or days after birth (5-7). The most common causes of foal septicaemia are Gram-negative bacteria, particularly *Escherichia coli*, *Actinobacillus* spp., and *Klebsiella pneumoniae* (8); however, *S. equi* subsp. *zooepidemicus* is also a common aetiologic agent.

Foals can acquire infections in utero or can be infected after birth (5-7). In the present case, the mare had no signs of a genital infection, only mastitis. *Streptococcus equi* subsp. *zooepidemicus* was isolated both from the milk sample of the mare and the tissue samples of her foal in pure culture, indicating it was the primary agent involved in both conditions. It was not possible to obtain detailed information regarding the case history, and so we could not determine the precise time the illnesses began. Therefore, it was difficult to determine whether the foal's illness preceded or followed the mare's mastitis. It is possible that the foal was not infected with the bacterium in utero or around the time of birth, but rather might have acquired the infection from the mastitic mare via the milk. An alternative scenario could be that the foal initially became infected via some other route, and that the mare developed mastitis as a result of the foal's nursing. Contact of the mare's udder with the foal's contaminated respiratory secretions while suckling may have resulted in an ascending infection in the mare's mammary gland.

In conclusion, in this report, we describe a case of a neonatal septicaemia due to *S. equi* subsp. *zooepidemicus* and associated mastitis in the dam.

References

1. Jackson, P.G.: Equine mastitis: comparative lessons. *Equine Vet. J.*, 1986; 18: 88-89.
2. McCue, P.M., Wilson, W.D.: Equine mastitis-a review of 28 cases. *Equine Vet. J.*, 1989; 21: 351-353.
3. Walker, R.L., Johnson, B.J., Jones, K.L., Pappagianis, D., Carlson, G.P.: *Coccidioides immitis* mastitis in a mare. *J. Vet. Diagn. Invest.*, 1993; 5: 446-448.
4. Greiner, E.C., Mays, M.B., Smart, G.C. Jr., Weisbrode, S.E.: Verminous mastitis in a mare caused by a free-living nematode. *J. Parasitol.*, 1991; 77: 320-322.
5. Koterba, A.M., Brewer, B.D., Tarplee, F.A.: Clinical and clinicopathological characteristics of the septicaemic neonatal foal: review of 38 cases. *Equine Vet. J.*, 1984; 16: 376-382.
6. Koterba, A.M., Brewer, B., Drummond, W.H.: Prevention and control of infection. *Vet. Clin. North Am. Equine Pract.*, 1985; 1: 41-50.
7. Platt, H.: Septicaemia in the foal. A review of 61 cases. *Br. Vet. J.*, 1973; 129: 221-229.
8. Wilson, W.D., Madigan, J.E.: Comparison of bacteriologic culture of blood and necropsy specimens for determining the cause of foal septicemia: 47 cases (1978-1987). *J. Am. Vet. Med. Assoc.*, 1989; 195: 1759-1763.
9. Quinn, P.J., Carter, M.E., Markey, B., Carter, G.R.: The streptococci and related cocci. In: Quinn, P.J., Carter, M.E., Markey, B., Carter, G.R., Eds. *Clinical Veterinary Microbiology*. Mosby, Edinburgh, UK, 2000; 127-136.

10. Bauer, A.W., Kirby, W.M., Sherris, J.C., Turck, M.: Antibiotic susceptibility testing by a standardized single disk method. *Am. J. Clin. Pathol.*, 1966; 45: 493-496.
11. Roberts, M.C.: *Pseudomonas aeruginosa* mastitis in a dry non-pregnant pony mare. *Equine Vet. J.*, 1986; 18: 146-147.
12. Addo, P.B., Wilcox, G.E., Taussig, R.: Mastitis in a mare caused by *C. ovis*. *Vet. Rec.*, 1974; 95: 193.
13. Prentice, M.W.M.: Mastitis in the mare. *Vet. Rec.*, 1974; 94: 380.
14. Al-Graibawi, M.A., Sharma, V.K., Ali, S.I.: Mastitis in a mare. *Vet. Rec.*, 1984; 115: 383.
15. Reese, G.L., Lock, T.F.: Streptococcal mastitis in a mare. *J. Am. Vet. Med. Assoc.*, 1978; 173: 83-84.
16. Strong, M.G.: Mastitis in the mare. *Vet. Rec.*, 1974; 94: 526.
17. Giles, R.C., Donahue, J.M., Hong, C.B., Tuttle, P.A., Petrites-Murphy, M.B., Poonacha, K.B., Roberts, A.W., Tramontin, R.R., Smith, B., Swerczek, T.W.: Causes of abortion, stillbirth, and perinatal death in horses: 3,527 cases (1986-1991). *J. Am. Vet. Med. Assoc.*, 1993; 203: 1170-1175.
18. Kocabiyik, A.L., Sönmez, G., Ülgen, M., Özakin, C., Kocakaya, E., Alasonyalilar, A.: Abortion due to *Streptococcus equi* subspecies *zooepidemicus* in a mare. *Turk. J. Vet. Anim. Sci.*, 2005; 29: 937-940.
19. Platt, H.: Etiological aspects of perinatal mortality in the Thoroughbred. *Equine Vet. J.*, 1973; 5: 116-120.