

Pulmonary Aspergillosis and Amyloid Accumulation in an Ostrich (*Struthio camelus*)

Ahmet AKKOÇ, Rağsan YILMAZ, İ. Taci CANGÜL, M. Özgür ÖZYİĞİT*

Department of Pathology, Faculty of Veterinary Medicine, Uludağ University, 16059 Görükle, Bursa - TURKEY

Received: 30.05.2006

Abstract: Fatal pulmonary aspergillosis and AA type amyloid accumulations in the liver and spleen are described in a female ostrich (*Struthio camelus*). The animal had had respiratory problems and long-term inappetence over an 8-week period. Necropsy revealed that several soft, grayish to white nodules ranging from 1 to 3 mm in diameter were scattered throughout the lungs and thoracic air sacs. Prominent enlargement of the liver and spleen was observed. No gross lesions were found in the other organs studied. The microscopic examination showed severe, necrotizing, granulomatous pneumonia, and air sacculitis. *Aspergillus fumigatus* was recovered from the lungs and air sacs as pure culture colonies. Amyloid deposition was demonstrated in the liver and spleen slides by Congo red and immunohistochemistry. To the authors' knowledge, to date no case of amyloid accumulation in ostrich has been reported. We report, for the first time, diffuse AA amyloidosis in the liver and spleen of an ostrich, probably occurring secondary to aspergillosis.

Key Words: Ostrich, *Aspergillus fumigatus*, amyloid

Bir Devekuşunda (*Struthio camelus*) Akciğer Aspergillozisi ve Amiloid Birikimi

Özet: Sunulan bu olguda, dişi bir devekuşunda gözlenen öldürücü akciğer aspergillozisi ile birlikte görülen karaciğer ve dalakta AA tipteki amiloid birikimi rapor edilmiştir. Sekiz haftayı aşan solunum yolu problemleri ve iştahsızlık sonrası ölen hayvanın nekropsisinde, akciğer loblarında ve göğüs boşluğuna ait hava keselerinde, 1-3 mm çapa sahip, çok sayıda, yumuşak kıvamlı ve grimsi-beyaz renkte nodüllere rastlanmıştır. Karaciğer ve dalakta hafif şiddette büyüme ve renkte açılma dikkati çekmiştir. İncelenen diğer organlarda makroskopik lezyona rastlanmamıştır. Mikroskopik incelemede mantar hifaları ile birlikte şiddetli granulomatöz pnömoni ve hava keselerinin yangısı görülmüştür. Dalak ve karaciğerde Kongo red ve immunohistokimyasal boyamalar sonucunda AA tipteki amiloid birikimleri gösterilmiştir. Mikrobiyolojik inceleme sonucunda akciğer ve hava keselerinden saf kültürler halinde *Aspergillus fumigatus* üretilmiştir. Bu çalışma ile, ilk kez, bir devekuşunda, karaciğer ve dalakta AA tipteki amiloid birikimleri gösterilmiştir.

Anahtar Sözcükler: Devekuşu, *Aspergillus fumigatus*, amiloid

Introduction

Pulmonary aspergillosis is the most common mycotic infection in a wide variety of avian species worldwide (1). Cases of aspergillosis have already been reported in chickens (2), turkeys (3), ostriches (4,5), and other wild birds such as robins (6) and penguins (7). The acute form of the disease is characterized by mortality rates of 70% to 90% in young animals. In the subacute and chronic forms of the disease, animals live longer, developing

various clinical and histopathological findings (8).

Amyloidosis can be defined as the deposition of soluble proteins or their fragments extracellularly in various organs. Although a variety of amyloid proteins have been described, AL (primary amyloid) and AA (secondary amyloid) types predominate (9). In birds, AA amyloidosis commonly occurs in association with chronic infectious diseases such as tuberculosis and bumble foot (1,10) and the liver and spleen are usually the organs affected (1).

* E-mail: ozyigit@uludag.edu.tr

Case History

A 27-week-old female ostrich (*Struthio camelus*) from the ostrich farm of the Faculty of Agriculture, University of Uludağ, with respiratory problems and long-term inappetence over an 8-week period was submitted for necropsy after death. In another 20 birds no signs of infection were observed. In the necropsy, the animal was in poor condition and the abdomen was distended with yellowish ascitic fluid (approximately 1 l) accumulation. Prominent enlargement of the liver and fibrin deposition on the surface were observed. The spleen was pale and moderately enlarged. Several soft, grayish to white nodules ranging from 1 to 3 mm in diameter were found to be scattered throughout the lungs and thoracic air sacs. Cut surface of the nodules displayed caseous necrosis. Serous membranes of the air sacs were thickened and the sacs had an opaque appearance due to grayish to yellowish purulent exudation. The right ventricular wall of the heart was dilated and all abdominal veins were congested.

Tissue samples were taken from lungs, air sacs, liver, heart, kidney, spleen, and central nervous system for histopathological and microbiological examination. For histopathology, tissue samples were fixed in neutral

buffered formalin and processed routinely. Slides were stained with hematoxylin and eosin (HE). Some selected slides from the lung, liver, and spleen were also stained with Grocott's methenamine silver (GMS) and Congo red stains. To identify the type of amyloid, a standard streptavidin-biotin-peroxidase complex method was performed using 1:100 diluted monoclonal goat-anti-mouse antibody against AA amyloid (Neomarkers, Fremont, CA, USA); the chromogen was 3,3'-diaminobenzidine tetrahydrochloride (DAB) as described by Sevimli et al. (11). For microbiological examination, tissue samples from various organs were cultured in blood agar and Sabouraud dextrose agar (SDA, Oxoid, Hampshire, UK) and incubated for the isolation of the causative agent. For mycological examination culture plates were incubated at 28 °C for a week.

Results and Discussion

Microscopically, the blood vessels were congested and the normal architecture of the lung and air sacs was replaced by disseminated granulomatous foci. The center of the granulomatous foci contained caseous necrosis and necrotic cellular debris (Figure 1) surrounded by rims of heterophils, lymphocytes, macrophages, and

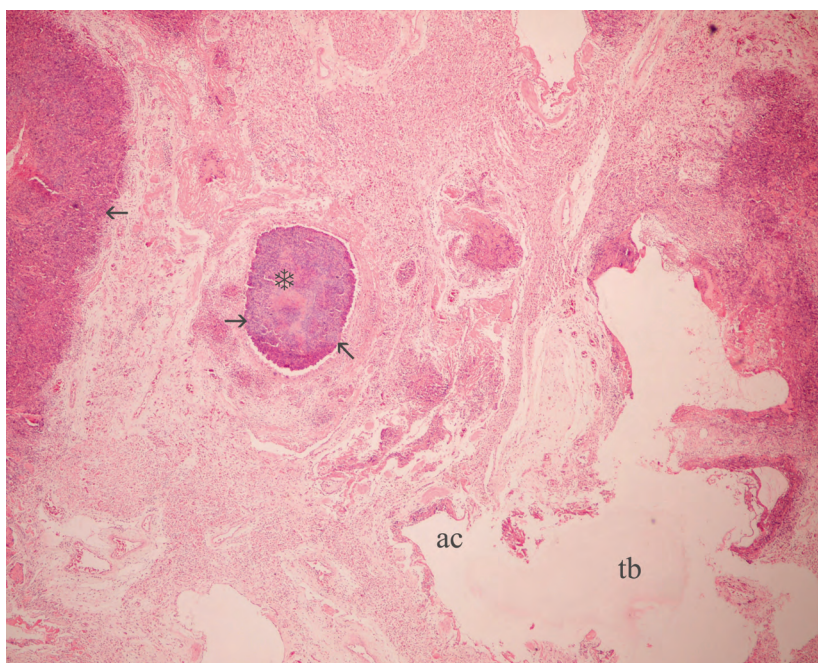


Figure 1. Lung, areas of caseous necrosis (snow flake) and cellular debris (arrows), HE, original magnification $\times 40$.

multinucleated giant cells. Within the peripheral parts of the caseous necrosis, GMS positive hyphae were arranged in a radial pattern (Figure 2). Most of the bronchial lumens were filled with necrotic cellular debris. The walls of thoracic air sacs were thickened due to severe infiltration of inflammatory cells, mainly degenerated heterophils. In liver sections, pinkish amorphous depositions were observed in the spaces between the hepatocytes and sinusoids causing atrophy and degeneration of the hepatocytes. Small periportal necrotic areas of various size and fibrin deposition on the surface were seen in the liver. Marked follicular atrophy and diffuse accumulation of pinkish amorphous material in the media layer of and around the vessels were noted in the

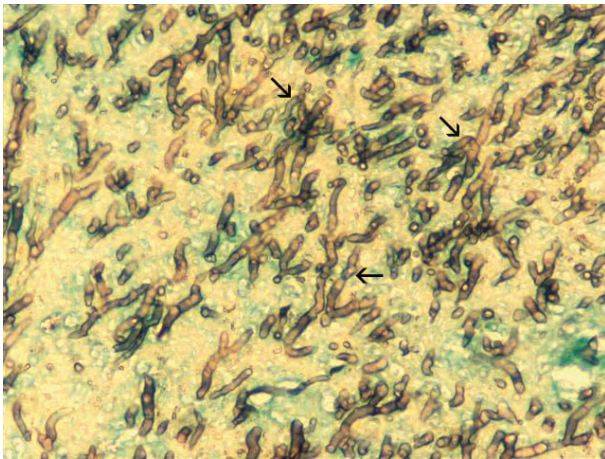


Figure 2. Lung, fungal hyphae arranged in a radial pattern (arrows), GMS, original magnification $\times 400$.

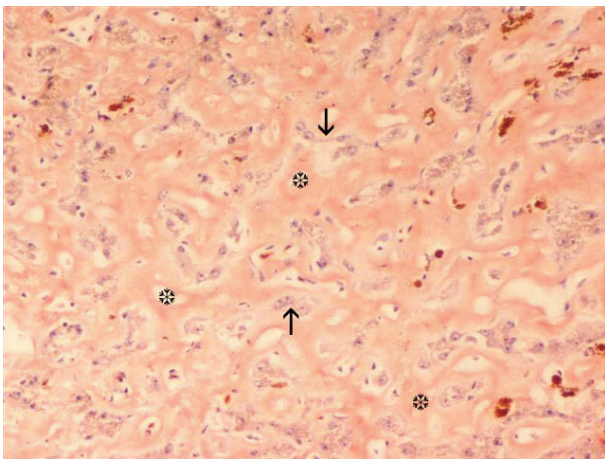


Figure 3. Liver, orange amyloid depositions (snow flakes), atrophic and degenerated hepatocytes (arrows), Congo red, original magnification $\times 400$.

spleen. In other examined organs, no significant lesions or fungal hyphae were observed. The pinkish amorphous material in the liver and spleen was demonstrated to be amyloid with Congo red stain (Figure 3). Immunohistochemically, depositions in the liver and spleen reacted with the antibody that recognized AA type amyloid fibrils (Figure 4). The staining pattern with the antibody was extracellular and diffuse. The colonies isolated in SDA were 1-3 cm in diameter and were velvety white with a bluish-green center. *Aspergillus fumigatus* was recovered from the lungs and air sacs as pure culture colonies and identified according to the shape of the hyphae and conidia light microscopically. The bacteriologic examination gave negative results in all the studied samples.

Congo red stain is commonly used for the demonstration of amyloid and immunohistochemistry is an adjunct tool allowing the identification of the type of deposition. In our study, diffuse amyloid deposition was detected in the liver and spleen by Congo red staining and the type was demonstrated to be AA after immunohistochemistry.

Mycotic infections originating from *Aspergillus fumigatus* are commonly seen in avian species. Sporadic and epidemic cases were also reported in ostriches (1,5). In the present study, a sporadic case of aspergillosis in a 27-day-old ostrich was reported. The histopathology and mycological cultures are the techniques widely used in the diagnoses of mycotic infections in animals (1-6). In our study the same techniques and procedures were followed.

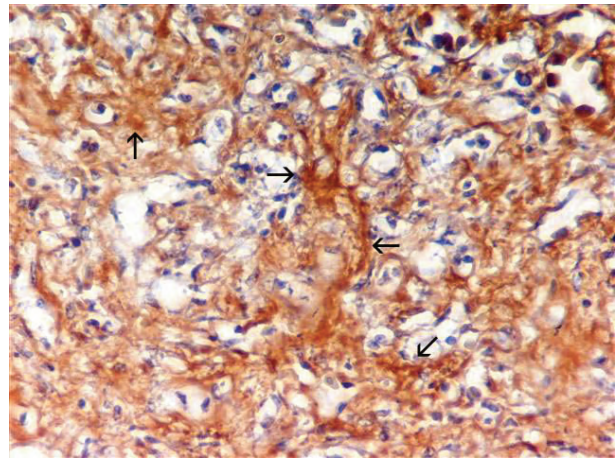


Figure 4. Spleen, positive staining for AA amyloid (arrows), streptavidin-biotin-peroxidase complex method, DAB with hematoxylin counterstain, original magnification $\times 400$.

The histopathological and mycological examination results of the submitted case were harmonious with other studies (2,5,8). The main aim of the present study is to report the occurrence of amyloid accumulation related to mycotic infection in the liver and spleen of an ostrich. The demonstration of amyloid protein in tissues was achieved by immunohistochemistry, and the findings were in accordance with another avian study (11).

The positive reaction with AA amyloid antibody, the negative bacteriological examination results, and the lack of histopathological finding supportive of other chronic

infections suggest that amyloidosis occurred as a result of the mycotic infection. To the authors' knowledge, to date no case of amyloid accumulation in ostrich has been reported. In the present study, for the first time, we report diffuse AA amyloidosis in the liver and spleen of an ostrich, probably occurring secondary to aspergillosis.

Acknowledgment

The authors would like to thank Dr. Arzu Ursen for her kind support during the mycological and bacteriological examinations.

References

1. Kunkle, R.A.: Fungal Infections. In: Saif, Y.M., Barnes, H.J., Glisson, J.R., Fadly, A.M., McDougald, L.R., Swayne, D.E. Eds.: Diseases of Poultry. 11th edn., Iowa State Press, Ames. 2003; 883-893.
2. Akan, M., Hazıroğlu, R., İlhan, Z., Sareyyüpoğlu, B., Tunca, R.: A case of aspergillosis in a broiler breeder flock. *Avian Dis.*, 2002; 46: 497-501.
3. Cortes, P.L., Shivaprasad, H.L., Kiupel, M., Sentíes-Cué, G.: Omphalitis associated with *Aspergillus fumigatus* in poults. *Avian Dis.*, 2005; 49: 304-308.
4. Yokota, T., Shibahara, T., Wada, Y., Hiraki, R., Ishikawa, Y., Kadota, K.: *Aspergillus fumigatus* infection in an ostrich (*Struthio camelus*). *J. Vet. Med. Sci.*, 2004; 66: 201-204.
5. Timurkaan, N., Keskin, O., Yilmaz, F., Cimtay, I.: Aspergillosis outbreak in an ostrich flock. *Med. Wet.*, 2005; 61: 765-766.
6. Low, M., Berggren, A., Morgan, K.J., Alley, M.R.: Aspergillosis in a North Island robin (*Petroica longipes*). *N. Z. Vet. J.*, 2005; 53: 462-464.
7. Carrasco, L., Lima, J.S. Jr., Halfen, D.C., Salguero, F.J., Sánchez-Cordon, P., Becker, G.: Systemic aspergillosis in an oiled magallanic penguin (*Spheniscus magellanicus*). *J. Vet. Med. B. Infect. Dis. Vet. Public Health*, 2001; 48: 551-554.
8. Atasever, A., Gümüşsoy, K.S.: Pathological, clinical and mycological findings in experimental aspergillosis infections of starlings. *J. Vet. Med. A. Physiol. Pathol. Clin. Med.*, 2004; 51: 19-22.
9. Slauson, D.O., Cooper B.J., Suter, M.M.: Disease at the cellular level. In: Slauson, D.O., Cooper, B.J. Eds., Mechanisms of Disease. A Textbook of Comparative General Pathology. 2nd edn., Williams and Wilkins, Maryland, 1990; 83-86.
10. Sanford, S.E., Rehmtulla, A.J., Josephson, G.K.: Tuberculosis in farmed rheas (*Rhea americana*). *Avian Dis.*, 1994; 38: 193-196.
11. Sevimli, A., Mısırlıoğlu, D., Özakın, C.: The enhancing effect of vitamin A on the occurrence of amyloid arthropathy in laying chickens infected with *Enterococcus faecalis*. *Turk. J. Vet. Anim. Sci.*, 2004; 28: 131-138.