

A case study of the clinical form of Johne's disease in a heifer

Agnieszka WISZNIEWSKA-ŁASZCZYCH, Joanna SZTEYN, Aleksandra RUSZCZYŃSKA

Department of Animal Products Hygiene, Chair of Veterinary Protection of Public Health, University of

Warmia and Mazury in Olsztyn, ul. Oczapowskiego 14, 10-718 Olsztyn - POLAND

Received: 01.04.2008

Abstract: Johne's disease–paratuberculosis–affects domesticated and wild ruminants throughout the world. The first symptoms of the disease appear 6 months to 15 years after infection. The clinical stage of paratuberculosis usually occurs in older animals and is rare in those under 2 years of age. While performing analyses on a farm in the northeastern region of Poland a 2-year-old heifer that manifested symptoms of dyspepsia, proceeding with watery diarrhea, was observed. ELISA test (IDEXX) results demonstrated a positive serological reaction for paratuberculosis. Clinical examination, microbiological analysis of feces, autopsy, and histopathological examination confirmed the incidence of Johne's disease in the heifer.

Key words: Paratuberculosis, clinical stage, diagnosis, symptoms, Poland

Introduction

Johne's disease–paratuberculosis–is a chronic, ulcerating enteritis induced by *Mycobacterium paratuberculosis* (MAP). It affects domesticated and wild ruminants throughout the world (1) and causes significant economic losses at an individual level, i.e. to single dairy cows, as well as at the herd level (2,3).

Infection usually occurs during the first months of life via newborn calf contact with colostrum and milk, as well as with feces of infected cows. Cases of intrauterine infection of fetuses have been reported as well (4). The first symptoms of the disease (periodic persistent diarrhea, body weight loss, progressing cachexy) appear 6 months to 15 years after infection. The clinical stage of the disease usually occurs in older animals and is rare in those under 2 years of age (5). Nowadays, it occurs more frequently in the subclinical and latent stage. Periodically, cattle infected with

MAP that do not manifest clinical symptoms shed mycobacteria with their feces, which constitutes a source of infection to other animals in the herd. It poses a high risk because the disease may spread within a herd for a few years before being observed and diagnosed; reports show that the full clinical picture of the disease develops in only 1 per 20-25 infected cows per herd (6).

Most Polish veterinarians and breeders share the opinion that eradication of tuberculosis has resulted in the elimination of MAP-infected animals, and that the disease no longer occurs in Poland. Difficulties in diagnosing the disease, often complicated by other infections, its long development period, and its dubious clinical picture can result in herd infection remaining unrecognized for a number of years. The cost of analysis, consequences of disease notification (it is a disease subject to notification), as well as low-

* E-mail: aga@uwm.edu.pl

level awareness among breeders of the economic losses triggered by infection in a herd (and consequent reluctance to eliminate it) result in a lack of motivation to perform routine tests for bovine paratuberculosis that would enable detecting the infection.

Case History

At the end of 2006 and beginning of 2007 serological tests for paratuberculosis were carried out in a herd of 207 dairy cattle of unknown epizootic status on a farm in northeastern Poland. Based on data in the literature, it was assumed that analytical samples would be collected from cows over 2 years of age. While performing analyses on the farm a heifer that manifested symptoms of dyspepsia, proceeding with watery diarrhea, was observed. As reported by farm staff, the animal had been losing weight despite maintaining a normal appetite and had not been treated. A decision was made to obtain blood samples to test for paratuberculosis. The assay was carried out with the IDEXX ELISA test and demonstrated a positive serological reaction. For full diagnosis of paratuberculosis, the heifer was subjected to clinical examination; its blood and feces were collected for another serological test and for microbiological analyses, respectively.

For 6 months the heifer (Figure 1), aged 2 years and born on the inspected farm, had been manifesting symptoms of dyspepsia, proceeding with periodic watery diarrhea that initially lasted for 2-4 days and disappeared without medical intervention, yet with time became more persistent and led to weight loss despite a normal appetite. At the time of examination the animal was extremely emaciated and a large edema was observed in the submaxillary area. According to information gathered from the farm staff the heifer had not been treated.

Results and discussion

The serological assay was conducted with the IDEXX ELISA test (*Mycobacterium paratuberculosis* antibody ELISA test kit), according to the manufacturer's instructions. Absorbance of the sample was measured with a DANEX MRX microplate reader at a wavelength of 450 nm. The presence of antibodies was calculated based on the ratio of absorbance of the experimental sample to



Figure 1. The study heifer.

absorbance of the control sample (S/P). Samples with an S/P ratio greater than 0.30 are considered seropositive. In the case of samples collected from the examined heifer, the S/P ratio was 0.53, which indicates a high level of antibodies in blood serum.

The heifer's feces were watery, and contained fimbriae of mucus and traces of blood. In order to identify the presence of MAP, a sample of feces was prepared for inoculation as follows: 1 g of feces was dissolved in 35 mL of sterile water, shaken for 30 min, and then left for another 30 min for sedimentation. Next, 5 mL of supernatant were transferred to a sterile test tube supplemented with 25 mL of 0.9% cetylpyridinium chloride (CPC), so as to obtain a final concentration of the solution equal to 0.75% CPC. The sample was incubated overnight at room temperature and then centrifuged at $1700 \times g$ for 20 min. The resultant precipitate was dissolved in 1 mL of sterile water and inoculated onto HEYM (Herrold's egg yolk medium) with the addition of mycobactin. After 6 weeks of incubation at 37 °C bacterial colonies were observed to have the morphology typical of acid-fast mycobacteria. From the grown colonies suspected of belonging to *Mycobacterium paratuberculosis*, DNA was extracted using a Qiagen QIAamp DNA Mini Kit, according to the manufacturer's instructions. The genetic material obtained was analyzed by PCR (7) in order to identify a DNA sequence typical of MAP. The assay, carried out on genetic material extracted from the isolated colonies, confirmed the presence of an insertion fragment IS-900, which indicated that the bacterium examined belonged to *Mycobacterium paratuberculosis*.

Unsuccessful attempts at calving, persistent watery diarrhea, and progressive emaciation prompted the owners to eliminate the animal from the herd. An autopsy performed immediately after euthanizing the animal demonstrated lesions in the gastrointestinal tract, mainly in the area of the ileum and mesenteric lymph nodes, in addition to extreme emaciation and edema in the submaxillary area. Intestinal mucosae (Figure 2) were hypertrophic, softened and folded, and formed a structure typical of paratuberculosis, visually resembling cerebral ganglia. Intestinal digesta were watery, with visible fimbriae of mucus and traces of bleeding into the intestine's lumen. Considerable enlargement and congestion of mesenteric lymph nodes were demonstrated as well. During the examination, sections of the ileum were collected, fixed in a solution of formalin, and transferred to the Division of Forensic Veterinary Medicine and Veterinary Administration, Faculty of Veterinary Medicine in Olsztyn, for histopathological analysis. The histopathological picture (Figure 3) demonstrated cellular infiltration and blurred intestinal villi structure. Those changes caused a reduction in the absorption surface in the intestine, resulting in diarrhea and progressive emaciation, despite a normal appetite. The results obtained confirmed the incidence of Johne's disease in the heifer.

Nowadays, 4 stages of paratuberculosis are recognized (5):

1. Latent: A lack of clinical symptoms, a lack of antibodies in blood serum, and mycobacteria

in feces; occurs usually in young individuals under 2 years of age;

2. Sub-clinical: A lack of clinical symptoms of the disease, with periodic occurrence of antibodies in blood and mycobacteria in feces, which enables serological and microbiological diagnosis;
3. Clinical: First clinical symptoms, including emaciation despite normal or enhanced appetite, periodic diarrhea, and reduced milk production; most animals have a positive serological reaction and excrete mycobacteria with feces. In this stage of disease animals are removed from a herd because they result in economic losses.
4. Clinical, advanced: Characterized by extreme emaciation, permanent diarrhea, with edema observed in the submaxillary area and hypoproteinemia. It occurs extremely rarely because animals are usually removed from a herd during earlier stages of the disease due to chronic diarrhea, emaciation, and diminished milk yield.

The disease develops over a long period of time and the occurrence of clinical symptoms depends, to a great extent, on the epizootic status of a herd (5). As shown by the early works by Hagan (8) and Rankin (9), clinical symptoms of the disease will develop in 50% of calves infected in the perinatal period in herds with a high level of MAP, and 30% will die within 2 years of being infected. Among calves living in a less

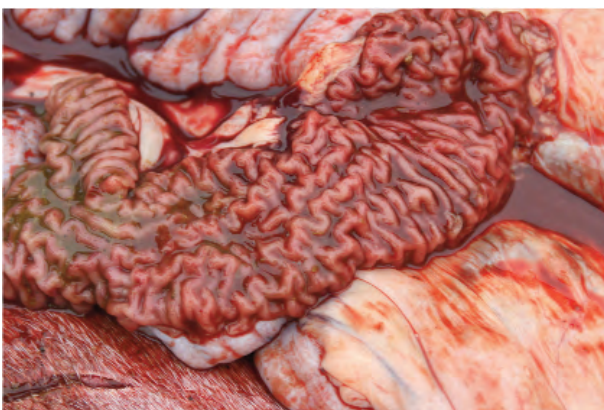


Figure 2. Intestinal mucosa with the characteristic appearance of paratuberculosis.

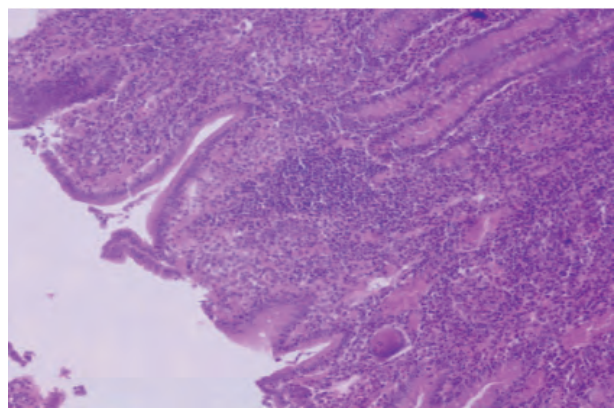


Figure 3. Histopathological examination of the intestine during the clinical stage of paratuberculosis.

infected environment, or among those infected at a later age, manifestation of symptoms will appear less frequently and later. It should be assumed, therefore, that the occurrence of the full clinical picture of Johne's disease in the presented heifer indicates high-level infection in the environment. It is estimated that in any given herd of cattle there is 1 animal with the clinical form of the disease per at least 25 infected animals, and only 30% of them might be identified by means of available diagnostic kits (5).

A lack of pathognomic symptoms poses the greatest difficulty in the diagnosis of paratuberculosis. Incomplete data on the incidence of the disease in Poland and the resulting conviction among veterinarians that it has been completely eradicated in cattle result in its misdiagnosis. Such symptoms as diarrhea, emaciation, and weight loss observed in infected animals suggest the occurrence of dyspepsia. Treatment results in only short-term improvement, yet recurrence of the disease contributes to the elimination of animals without complete diagnosis, especially once symptoms occur in single animals in a herd. Contemporarily, diagnosis of paratuberculosis is based on serological analysis, mainly with the use of ELISA tests, and microbiological analyses that can detect MAP in feces or tissues of infected animals. The isolation of MAP from biological material is reported to be the gold standard. Unfortunately, those methods fail to detect the latent form of infection (5).

Research published in the last 20 years lacks descriptions of the clinical forms of paratuberculosis in naturally infected cattle. In countries with a history of Johne's disease, herds are subjected to routine serological and microbiological assays, which prevent the development of full-symptomatic paratuberculosis. An awareness of economic losses motivates breeders to prevent it. Invaluable is the role of veterinarians that are able to diagnose the disease and plan a program of herd restoration by eliminating animals with clinical symptoms, controlling sub-clinical infections, and rearing calves under conditions that prevent infection (5).

References

1. Kennedy, D., Holmström, A., Forshell, K.P., Vindel, E., Suarez Fernandez, G.: On-farm management of paratuberculosis (Johne's disease) in dairy herds. *Bull. Int. Dairy Fed.*, 2001; 362: 18-31.
2. Ott, S.L., Wells, S.J., Wagner, B.A.: Herd-level economic losses associated with Johne's disease on US dairy operations. *Prev. Vet. Med.*, 1999; 40: 179-192.

Even in countries with vigilant control programs it often remains undiagnosed; thus it spreads uncontrollably on a farm and poses a risk to other herds once infected animals are introduced into turnover. Paratuberculosis is a disease subject to notification. Based on data sent by official veterinary services, the World Organization for Animal Health (OIE) registered its incidence in over 70 countries around the world, including 25 of the 40 European countries. The percentage of paratuberculosis-infected herds in Western Europe ranges from 5% to 55%, and in the region of Mecklenburg it is 84.7%. Similar results were obtained in a study carried out in the United States of America, i.e. from 21% to 54% of herds. Spread of the diseases, as claimed by researchers, may be substantially greater than reported by the authorities (10-12).

In Poland, data on the spread of the disease in herds of dairy cattle are incomplete. In the domestic literature, 1 case of Johne's disease was reported in 1970 (13). Studies on dairy cattle carried out in a few herds in north eastern Poland indicated 1 or more cows with positive serological reactions to paratuberculosis in 25% of the herds. No animals with the clinical form of the disease were identified in any of the herds analyzed during that period (14). The OIE 2006 Report highlighted the case of the clinical form of paratuberculosis in Poland (http://www.oie.int/wahid-prod/public.php?page=disease_status_lists); however, the case was not described nor presented to veterinarians or breeders.

Information provided by veterinary services to the World Organization for Animal Health, as well as the above-described full-symptomatic clinical form of Johne's disease in a herd of dairy cattle from the northeastern Poland, prove the existence of the problem of paratuberculosis in Poland. Considering its pathogenesis and mode of dissemination, as well as the age of the diagnosed animal, it should be assumed that in the farm examined MAP infection has existed for a long period of time and affected a larger number of animals.

3. Power, S.B., Haagsma, J., Smyth, D.P.: Paratuberculosis in farmed red deer (*Cervus elaphus*) in Ireland. *Vet. Rec.*, 1993; 132: 213-216.
4. Whittington, R.J., Windsor, P.A.: In utero infection of cattle with *Mycobacterium avium* subsp. *paratuberculosis*: a critical review and meta-analysis. *Vet. J.*, 2009; 179: 60-69.
5. Whitlock, R.H., Buergelt, C.: Preclinical and clinical manifestations of paratuberculosis (including pathology). *Vet. Clin. North Am. Food Anim. Pract.*, 1996; 12: 345-356.
6. Riemann, H.P., Abbas, B.: Diagnosis and control of bovine paratuberculosis (Johne's disease). *Adv. Vet. Sci. Comp. Med.*, 1983; 27: 481-506.
7. Szteyn, J., Wiszniewska-Łaszczych, A., Ruszczyńska, A.: PCR w wykrywaniu *Mycobacterium paratuberculosis* w mleku surowym. *Medycyna Weter.*, 2007; 63: 1106-1107. (article in Polish)
8. Hagan, W.A.: Age as a factor in susceptibility to Johne's disease. *Cornell Vet.*, 1938; 28: 34-40.
9. Rankin, J.D.: The experimental infection of cattle with *Mycobacterium johnei*. III. Calves maintained in an infectious environment. *J. Comp. Pathol.*, 1961; 71: 10-15.
10. Gasteiner, J., Wenzl, H., Fuchs, K., Jark, U., Baumgartner, W.: Serological cross-sectional study of paratuberculosis in cattle in Austria. *Zentralbl. Veterinarmed. B.*, 1999; 46: 457-466.
11. Hacker, U., Hüttner, K., Konow, M.: Investigation of serological prevalence and risk factors of paratuberculosis in dairy farms in the state of Mecklenburg-Westpomerania, Germany. *Berl. Münch. Tierärztl. Wochenschr.*, 2004; 117: 140-144. (article in German with an abstract in English)
12. Muskens, J., Barkema, H.W., Russchen, E., van Maanen, K., Schukken, Y.H., Bakker, D.: Prevalence and regional distribution of paratuberculosis in dairy herds in The Netherlands. *Vet. Microbiol.*, 2000; 77: 253-261.
13. Ramisz, A., Cąkała, S., Szańkowska, Z., Hoffman, H., Damm, A., Zahaczewski, J., Danilczuk, K., Jaremski, A.: Przypadek choroby Johnego u bydła na terenie województwa krakowskiego. *Medycyna Weter.*, 1970; 26: 203-205. (article in Polish)
14. Szteyn, J., Wiszniewska, A., Fus-Szewczyk, M.: Przeciwciała swoiste dla *Mycobacterium avium* subsp. *paratuberculosis* u bydła mlecznego północno-wschodniej Polski. *Medycyna Weter.*, 2005; 61: 884-886. (article in Polish).