

## Clinical evaluation of the pocket technique for replacement of prolapsed gland of the third eyelid in dogs

Mohammad Mehdi DEHGHAN<sup>1\*</sup>, Mir Sepehr PEDRAM<sup>1</sup>, Omid AZARI<sup>2</sup>,  
Hossein Kazemi MEHRJERDI<sup>3</sup>, Elnaz AZAD<sup>1</sup>

<sup>1</sup>Department of Clinical Sciences, Faculty of Veterinary Medicine, University of Tehran, Tehran - IRAN

<sup>2</sup>Department of Clinical Sciences, Faculty of Veterinary Medicine, Shahid Bahonar University of Kerman, Kerman - IRAN

<sup>3</sup>Department of Clinical Sciences, Faculty of Veterinary Medicine, Ferdowsi University of Mashhad, Mashhad - IRAN

Received: 15.02.2011 • Accepted: 05.10.2011

**Abstract:** The purpose of this study was to evaluate the clinical outcome and complications of the pocket technique in the repositioning of the prolapsed third eyelid gland in dogs. From 28 dogs, 38 eyes with protrusion of the third eyelid gland were treated using the pocket technique. Of the dogs, 22 (79%) were less than 1 year of age when the prolapse was first noted by the owner. Protrusion of the glands in both eyes was found in 10 of the dogs (36%). The success rate of surgical replacement was 97% (37 eyes). The complication rate was 13.15%. The pocket technique does not alter tear production or the morphology of the third eyelid gland ducts; therefore, this procedure can be used on the prolapse of the third eyelid gland without damaging the gland's duct system. Based on the results of this study, it was concluded that the pocket technique can be considered as a reliable procedure for the repositioning of a prolapsed gland of the third eyelid.

**Key words:** Third eyelid gland, prolapse, pocket technique, dog

### Introduction

Prolapse or protrusion of the gland of the third eyelid, referred to as "haws" or "cherry eye," has been reported in dogs for over 30 years (1-3). This condition occurs more commonly in dogs than cats (4,5), usually before they reach the age of 2 years (1,6). The underlying cause of the glandular prolapse is unclear (3,7). However, it is believed that a prolapse of the gland may occur secondary to inflammation and a weakness in the connective tissue attaching the gland to its normal position posterior and ventral to the nictitans, allowing the gland to migrate dorsally and flip up to protrude above the leading margin of the membrane (1,3). Although this weakness may

be a heritable condition, the inheritance pattern is unknown. Moreover, a genetic anatomical defect is suspected; however, a specific abnormality has not been demonstrated (2).

Prolapse of the gland is the most common disease of the canine third eyelid and the treatment of this condition continues to be the subject of considerable discussion (8,9).

Certain breeds such as Beagle, American Cocker spaniel, Boston terrier, Poodle, and brachycephalic breeds are more prone to develop the condition (1-3,7). Clinical problems associated with prolapsed gland include epiphora, conjunctivitis, and sudden development of a red mass at the medial canthus (2,7).

\* E-mail: mdehghan@ut.ac.ir

Before the 1980s, veterinarians widely treat this condition by removing the entire gland (6,10,11). However, the third eyelid gland produces 40% of tears and the excision of this prolapsed gland can cause a significant decrease in tear production, which was determined by the Schirmer tear test (12). Therefore, it is now recommended that prolapsed glands be surgically repositioned (3,10,12), and the definitive treatment for this problem is surgery (2). On the whole, excision of a prolapse of the third eyelid gland predisposes a dog to develop keratoconjunctivitis sicca (KCS) later in its life, and replacement of the gland in its proper location, rather than excision, is the preferred method of treatment (1,10,12,13). In this procedure, the gland is gently sewn back into place where it can resume tear production (7,9,14). Some surgical repositioning procedures performed to preserve the gland include orbital rim anchoring, scleral anchoring, and, most recently, the pocket method (7,9,14).

In the pocket technique, 2 parallel incisions into the bulbar conjunctival surface are made on either side of the prolapsed gland, and the bases of these incisions are joined with a simple continuous suture. When the suture is tightened, the gland is forced ventrally. Anchoring on the external side of the eyelid is necessary to avoid abrasion of the cornea by the suture ends (1,7).

The purpose of this study was to evaluate the clinical aspects, probable complications, and rate of recurrence of the pocket technique for treating prolapse of the third eyelid gland.

## Materials and methods

Surgical correction using the pocket technique was performed for replacement of the prolapsed gland of the third eyelid in 38 eyes (28 dogs) to evaluate different aspects of this surgical procedure. Aside from analysis of the data including breed, age, sex, and the affected eyes, the duration of prolapse, final outcome of the utilized pocket technique, and the occurrence of postoperative complications were also studied. The evaluated postoperative complications were recurrence of prolapse, induction of a corneal ulcer within the surgery, and occurrence of KCS.

All of the operations were performed under general anesthesia. Anesthesia was induced with

intravenous injection of a mixture of ketamine-HCl (10 mg/kg) and diazepam (0.5 mg/kg) after endotracheal intubation, which was maintained with halothane (1%-1.5%) in oxygen. The dogs were positioned in lateral recumbency with the affected eye facing upward. The surgical area was draped carefully to expose only the palpebral fissure. The third eyelid was grasped and exteriorized with 2 mosquito forceps. The pocket technique in these patients was performed according to the procedure of Morgan et al. (1), as follows. There were 2 superficial curvilinear incisions made parallel to the free margin on the bulbar side of the third eyelid; 1 was applied on each side of the prolapsed gland. The gland was then easily tucked into the pocket and the conjunctival edges were closed using 6/0-7/0 polydioxanone (PDS) or Vicryl sutures, using a simple continuous suture pattern. The knots were tied on the outside surface by taking a preliminary bite at the beginning and the end of the suture pattern on the outside surface. The 2 incisions were not connected to avoid formation of a retention cyst. The second layer of inverting continuous Cushing pattern was used to oversew the simple continuous layer (1,2).

In the bilateral cases, the procedure was repeated in the same manner in the second eye. After the surgical procedure, all of the patients were treated topically with ophthalmic antibiotic drop (ciprofloxacin 0.3%, 4 times a day; Ciplex, Sina Darou, Tehran, Iran) for 3 days preoperatively and for 10 days postoperatively. Due to possibility of interaction with healing of the suture line, local corticosteroid administration was not used after the operations.

All of the dogs were monitored for clinical signs of KCS, which include mucopurulent discharge, corneal vascularization, or pigmentation, for at least 6 months postoperatively. On the first postoperative day, all of the patients were inspected for corneal ulcer using fluorescent staining.

## Results

Throughout the study period, 38 eyes affected by prolapse of the third eyelid gland (28 dogs) were treated with the pocket technique (Figures 1-3). The most commonly affected breeds were terriers (12 cases). The other affected dog breeds were Pekingese

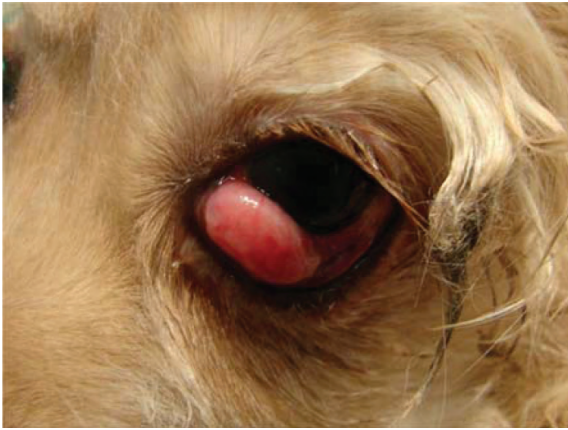

Figure 1. Unilateral prolapse of the third eyelid gland in an American Cocker spaniel dog.



Figure 2. Bilateral prolapse of the third eyelid gland in a mixed-breed dog.

(5 cases), spitz (2 cases), Pointer (1 case), American Cocker spaniel (1 case), English bulldog (1 case), French bulldog (1 case), and mixed-breed (5 cases) (Table 1). Seventeen of the dogs were male and 11 were female. The ages of the dogs at the time of the diagnosis ranged from 2.5 months to 4 years, with a median of 11.08 months (Table 2).

Twenty-two dogs (79%) were less than 1 year of age when the prolapse was first noted by the owner.

A total of 38 eyes were affected. Ten dogs (36%) had protrusion of the glands in both eyes. Of the dogs with unilateral disease, the left eye was affected in 10 (36%) dogs and the right eye was affected in 8 (28%) dogs. The duration of prolapse until the time of presentation for treatment varied from 3 days to 6.5 months (median time: 39 days). One dog had simultaneous bilateral prolapse. The success rate of

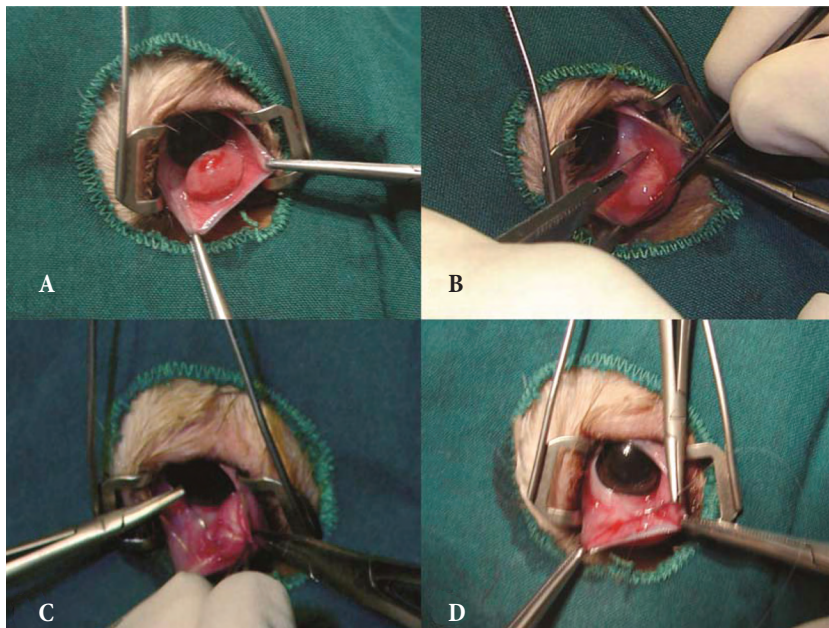


Figure 3. The intraoperative appearance of the pocket technique: A) exteriorizing the third eyelid with forceps, B) making parallel incisions through the bulbar conjunctiva anterior and posterior to the prolapsed gland, C-D) returning the gland to a normal position by apposing the incisions over the gland using a 2-layer simple continuous and inverting continuous Cushing suture pattern.

Table 1. Breeds of dogs with prolapse of the third eyelid gland.

Breeds	N = 28 dogs	Percent (%)
Terrier	12	42.86
Pekingese	5	17.86
Spitz	2	7.14
Pointer	1	3.57
American Cocker spaniel	1	3.57
French bulldog	1	3.57
English bulldog	1	3.57
Mixed-breed	5	17.86
<b>Total</b>	<b>28</b>	<b>100</b>

surgical replacement was 97% (37 eyes). One gland prolapsed again at a later date. Recurrence of the prolapsed gland was treated with a second surgery, again using the pocket technique. Superficial corneal ulcers were seen in 1 eye of 2 dogs, which were treated for 1 week. Epiphora was observed in 1 case. After surgery, mucopurulent discharge was observed in 1 dog (Table 3).

## Discussion

Because of inflammation, resulting irritation, and cosmetic appearance, the protruding third eyelid gland should be replaced (1,4,7,9). Removing the gland of the third eyelid lowers tear values by 15%-26% in cats and up to 40% in dogs. Therefore, the third eyelid gland plays an essential role in maintaining the aqueous tear film that protects the cornea (5,7,12,15). Removing this gland places the dog at increased risk of developing KCS, also known as dry eye, a condition in which the eye does not produce enough tears to effectively lubricate and protect the cornea from scratches, irritation, and desiccation (2,4,16).

Table 2. Age distribution of dogs with prolapse gland of the third eyelid.

Age	Number of dogs	Percent (%)
Under 1 year	22	78.6
1-2 years	3	10.7
2-4 years	3	10.7
<b>Total</b>	<b>28</b>	<b>100</b>

Table 3. Postoperative complications.

Breeds	N = 38 eyes	Percent (%)
Recurrence of prolapsed gland	1	2.63
Superficial corneal ulcers	2	5.26
Epiphora	1	2.63
Mucopurulent discharge	1	2.63
<b>Total</b>	<b>5</b>	<b>13.15</b>

This concern is made all the more serious because many breeds that are most susceptible to a prolapse of the third eyelid gland are also more susceptible to KCS (4,7).

The technique of surgical repositioning is simple to perform and carries a greater success rate with fewer complications than other treatment options such as conservative treatment and excision of a prolapse of the third eyelid gland (3). Furthermore, nonspecific therapy with antibiotic steroid combination could not be attained in resolution of the protrusion (4). No side effects have been encountered with the pocket technique, but mobility of the third eyelid is reduced in some dogs, similar to that which resulted with excision of the gland (1). Only one patient had recurrence of the prolapsed gland in the present study. One of the probable causes of this may be absorbable suture breaks (9). There were very few other complications. The induction of superficial corneal ulcers in 2 eyes was related to a technical problem. The rate of mucopurulent discharge and epiphora was less than 5.5% in all of the cases.

It is critical to mention that the longer the gland is exposed (months to years), the less likely it is that the surgical procedure will work. The use of PDS absorbable sutures limited the postsurgical inflammation in this study. The surgical results were excellent with very few recurrences.

Although terriers were the most common breeds diagnosed with prolapse of the third eyelid gland in this study, this may have been because terriers are the most common breeds in Iran. It is important to mention that most studies reported American Cocker spaniel, English bulldog, and Lhasa apso as the most common breeds with this condition (7,9,17). In breeds with a predisposition to prolapse

of the third eyelid gland, KCS occurs frequently, but the causal relationship between the 2 conditions remains unclear (18).

Excision of the third eyelid gland results in a reduction in aqueous tear production (19). The pocket technique does not alter tear production or the morphology of the third eyelid gland ducts. Therefore, this procedure can be used instead of replacement of the third eyelid gland without damaging the gland's duct system (7,8).

Of the dogs in this study, 11 were female and 17 were male, failing to support a sex predilection. The mean age of the dogs at the time of the diagnosis (11.08 months) in this study corroborated the results of other studies, which suggested that prolapse of the third eyelid gland is most common in dogs <2 years old (1,2,6,20).

On the whole, the success rate of gland replacement and client satisfaction make the pocket technique a reliable procedure for the repositioning of the prolapsed gland of the third eyelid.

## References

1. Morgan, R.V., Duddy, J.M., McClurg, K.: Prolapse of the gland of the third eyelid in dogs: a retrospective study of 89 cases (1980 to 1990). *J. Am. Anim. Hosp. Assoc.*, 1993; 29: 56-60.
2. Peiffer, R.L., Harling, D.E.: Third eyelid. In: Slatter, D.H., Ed. *Textbook of Small Animal Surgery*. Lea & Febiger, Philadelphia. 2002; 1501-1509.
3. Dugan, S.J., Severin, G.A., Hungerford, L.L., Whiteley, H.E., Roberts, S.M.: Clinical and histological evaluation of the prolapsed third eyelid gland in dogs. *J. Am. Vet. Med. Assoc.*, 1992; 201: 1861-1867.
4. Slatter, D.: Third eyelid. In: Slatter, D., Ed. *Fundamentals of Veterinary Ophthalmology*. 3rd ed., Saunders, Philadelphia. 2001; 229-232.
5. Chahory, S., Crasta, M., Trio, S., Clerc, B.: Three cases of prolapse of the nictitans gland in cats. *Vet. Ophthalmol.*, 2004; 7: 417-419.
6. Severin, G.A.: *Veterinary Ophthalmology Notes*. 2nd edn., Colorado State University Publications Service, Fort Collins, Colorado, USA. 1976; 107-116.
7. Martin, C.L.: Conjunctiva and third eyelid. In: Martin, C.L., Ed. *Ophthalmic Disease in Veterinary Medicine*. Manson Publishing Ltd., London. 2009; 183-214.
8. Moore, C.P., Frappier, B.L., Linton, L.L.: Distribution and course of ducts of the canine third eyelid gland: effects of two surgical replacement techniques. *Vet. Comp. Ophthalmol.*, 1996; 6: 258-264.
9. Plummer, C.E., Källberg, M.E., Gelatt, K.N., Gelatt, J.P., Barrie, K.P., Brooks, D.E.: Intracnictitans tacking for replacement of prolapsed gland of the third eyelid in dogs. *Vet. Ophthalmol.*, 2008; 11: 228-233.
10. Helper, L.C.: The canine nictitating membrane and conjunctiva. In: Gelatt, K.N., Ed. *Textbook of Veterinary Ophthalmology*. Lea & Febiger, Philadelphia. 1982; 330-331.
11. Howard, D.R.: Hypertrophy of the nictitans gland. *VM/SAG*, 1969; 64: 304-305.
12. Saito, A., Izumisawa, Y., Yamashita, K., Kotani, T.: The effect of third eyelid gland removal on the ocular surface of dogs. *Vet. Ophthalmol.*, 2001; 4: 13-18.
13. Stanley, R.G., Kaswan, R.L.: Modification of the orbital rim anchorage method for surgical replacement of the gland of the third eyelid in dogs. *J. Am. Vet. Med. Assoc.*, 1994; 205: 1412-1414.
14. Hendrix, D.V.H.: Canine conjunctiva and nictitating membrane. In: Gelatt, K.N., Ed. *Veterinary Ophthalmology*. 4th edn., Blackwell Publishing, Ames, Iowa, USA. 2007; 662-689.
15. Gelatt, K.N., Peiffer, R.L., Erickson J.L., Gum, G.: Evaluation of tear formation in the dog, using a modification of the Schirmer tear test. *J. Am. Vet. Med. Assoc.*, 1975; 166: 368-370.
16. Wyman, M.: *Manual of Small Animal Ophthalmology*. Churchill Livingstone Inc., New York. 1986; 125-133.
17. Bromberg, N.M.: The nictitating membrane. *Compend. Contin. Educ. Vet.*, 1980; 2: 627-632.
18. Aguirre, G.D., Rubin, L.F., Harvey, C.E.: Keratoconjunctivitis sicca in dogs. *J. Am. Vet. Med. Assoc.*, 1971; 158: 1566-1579.
19. McLaughlin, S.A., Brightman A.H., Helper L.C., Primm N.D., Brown M.G., Greeley S.H.: Effect of removal of lacrimal and third eyelid glands on Schirmer tear test results in cats. *J. Am. Vet. Med. Assoc.*, 1988; 193: 820-822.
20. Gross, S.L.: Effectiveness of a modification of the Blogg technique for replacing the prolapsed gland of the canine third eyelid. *Proc. Am. Coll. Vet. Ophthalmol.*, 1983; 14: 38-42.