

Urinary diversion via preputial urethrostomy with bilateral pubic-ischial osteotomy in a dog

Masaaki KATAYAMA^{1*}, Yasuhiko OKAMURA¹, Hiroaki KAMISHINA², Yuji UZUKA¹

¹Division of Small Animal Surgery, Department of Veterinary Medicine, Faculty of Agriculture, Iwate University, 3-18-8 Ueda, Morioka, Iwate 020-8550 – JAPAN

²Division of Veterinary Clinical Radiology, Department of Veterinary Medicine, Faculty of Applied Biological Sciences, Gifu University, 1-1 Yanagido, Gifu, Gifu 501-1193 – JAPAN

Received: 25.05.2011 • Accepted: 23.12.2011

Abstract: A 4-year-old, 8.7-kg intact male Pekingese dog was presented with stricture of the urethral opening after a perineal urethrostomy revision surgery. Total penile amputation and preputial urethrostomy with bilateral pubic-ischial osteotomy were performed. After surgery, the dog was able to urinate through the natural preputial orifice, avoiding urine scalding associated with urethral anastomosis to the adjacent skin. Nine months after surgery, no major complications were noted with the exception of a small amount of urine dribbling after urination.

Key words: Preputial urethrostomy, bilateral pubic-ischial osteotomy, dog

Introduction

Perineal urethrostomy in dogs is indicated for severe damage, stricture, or loss of the urethra at or proximal to the site of scrotal urethrostomy. However, complications are common during and after this surgical procedure, including severe hemorrhage of the urethral opening site and unacceptable urine scald dermatitis (1). Furthermore, postoperative stricture formation could occur when undue tension develops on the suture line of the urethrostomy site. In case of urethral stricture, prepubic or transpelvic urethrostomy may be considered as salvage procedures (2–4). However, complications such as urinary obstruction, urine scalding, urinary incontinence, and urinary tract infections are also common with these procedures. In addition, the appearance of the external stoma after this type

of urethrostomy is obviously different from the appearance of the normal anatomic structures.

In the present report preputial urethrostomy was performed in a male Pekingese dog as a salvage procedure for urethral stricture of the perineal urethrostomy site. This procedure resulted in a more acceptable cosmetic appearance. In addition, pubic-ischial osteotomy was simultaneously performed to obtain an adequate pelvic urethral length, preventing undue tension at the urethral opening site.

Case history

A 4-year-old, 8.7-kg intact male Pekingese dog was examined by the referring veterinarian for a sudden onset of vomiting and dysuria. A blood examination revealed azotemia. On abdominal ultrasonography, urinary calculi were lodged in the bladder and pelvic

* E-mail: masaaki@iwate-u.ac.jp

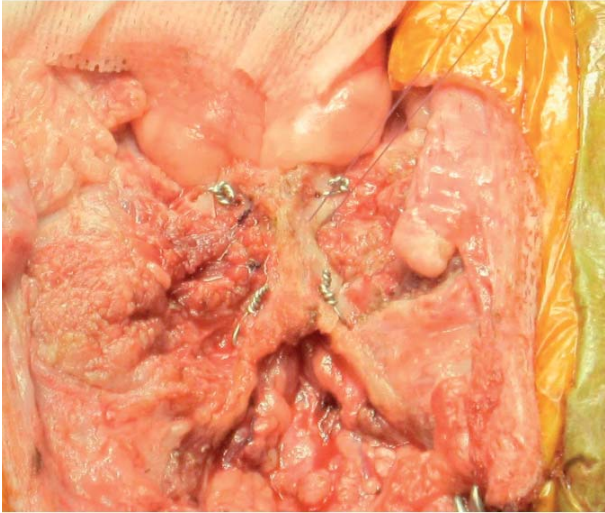


Figure 1. Stabilization of the bone plate with an 18-gauge orthopedic wire at 4 points.

urethra. In order to remove the calculi, cystotomy and perineal urethrotomy were performed, followed by perineal urethrostomy. At that time, a new urethral opening was made at the perineal urethrotomy site after removal of the calculi. Stone analysis revealed struvite uroliths, and a special prescription diet (c/d dry, Hill's) was fed to dissolve the crystals after surgery. One and a half months later, stricture formation of the urethral opening was confirmed and revision surgery was performed. However, complete resolution was not achieved.

The dog was referred to the Veterinary Teaching Hospital of Iwate University for salvage urinary diversion surgery 2 months after the second surgery. Introduction of a <4-Fr catheter was possible, indicating severe stricture of urethral stoma. The results of the complete blood count were within normal limits. Serum biochemistry panels revealed only slight elevation of alkaline phosphatase. No crystals were found by urinalysis.

Total penile amputation and preputial urethrostomy with bilateral pubic-ischial osteotomy were performed to create a permanent urinary diversion. The dog was premedicated with butorphanol (0.2 mg/kg intravenously [IV]) and midazolam (0.3 mg/kg IV). Anesthesia was induced with propofol (4 mg/kg IV to effect) and maintained with sevoflurane in 100% oxygen. A balanced electrolyte solution (lactated Ringer's solution at

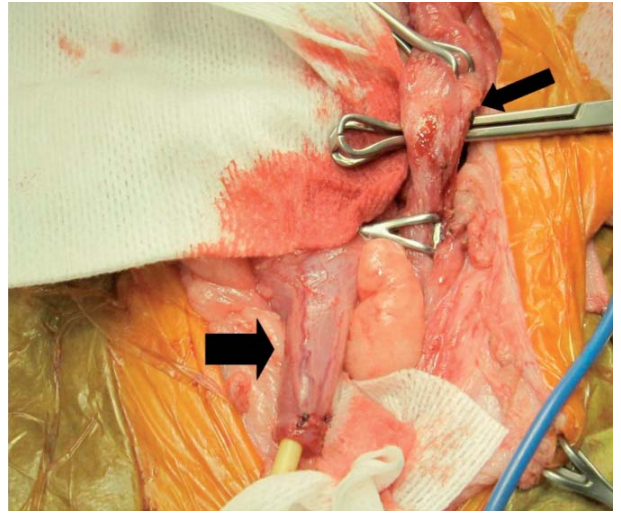


Figure 2. Preservation of the pelvic urethral length after total penile amputation. Babcock forceps were passed through the small incision made by a biopsy punch (small arrow). The length of the pelvic urethra was preserved (large arrow).

an hourly rate of 10 mL/kg) was administered. Antibiotics (cefmetazole sodium, 25 mg/kg IV) were administered at anesthetic induction and 2 h later, and then continued twice a day for 7 days.

With the animal in dorsal recumbency, a caudal ventral midline abdominal incision was performed followed by scrotal ablation and castration. A ventral midline preputiotomy incision was performed to access the penis and preputial cavity. After releasing the penis from the prepuce, the penis was reflected caudally and the ischiocavernosus and ischiourethralis muscles were transected close to their origins at the ischial arch. The pubic symphysis was exposed by subperiosteally elevating the adductor muscles until half of the obturator foramen was exposed. The prepubic tendon was transected along the pubis to the proposed osteotomy site. Holes (diameter: 1.7 mm) were drilled in the pubis and ischium on both sides of the 4 proposed osteotomy sites. The pubic and ischial osteotomies were performed with an electronic sagittal saw (Colibri, Synthes Vet, Switzerland), and the central bone plate was removed. The pelvic urethra was separated from the surrounding tissues and reflected cranially. The bony plate was placed back to its original location and stabilized with 18-gauge orthopedic wire, passing through the previously drilled holes (Figure 1). The penis was

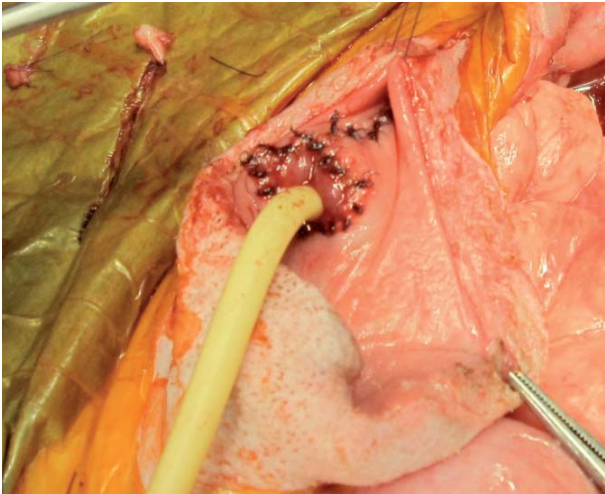


Figure 3. The urethral opening was sutured to the preputial mucosa in a simple interrupted pattern with 5-0 monofilament suture material.

completely removed by transecting the pelvic urethra immediately proximal to the bulbospongiosus muscles. The distal aspect of the pelvic urethra was exteriorized through a small incision, made by a disposable biopsy punch (BP-40F, Kai Industries, Japan) lateral to the linea alba, within the prepuce (Figure 2). The urethra was spatulated and sutured to the preputial mucosa using simple interrupted 5-0 monofilament absorbable sutures (Figure 3). In order to prevent stricture formation of the urethral opening, a 10-Fr balloon catheter was kept in place for 2 weeks after surgery. The mucosa and skin were reapposed separately using a simple interrupted pattern with 5-0 monofilament absorbable suture and staples, respectively. The adductor muscles and prepubic tendon were reapposed using a simple interrupted pattern with 2-0 monofilament absorbable suture before closing the linea alba. The remaining wound was closed in a routine fashion.

The dog recovered uneventfully from anesthesia and surgery. Buprenorphine (0.02 mg/kg) was administered subcutaneously to control pain. On the 14th postoperative day, a retrograde contrast study of the urethra and bladder revealed that they were positioned almost perpendicular to the abdominal wall (Figure 4). After removal of the urinary catheter, the dog could urinate without difficulty with urine passing out of the preputial orifice. Nine months after surgery, the owner noticed a small amount of urine

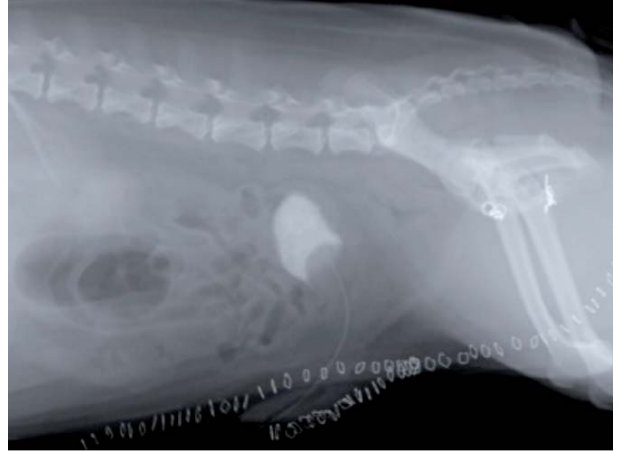


Figure 4. Retrograde contrast study of the bladder and urethra showing their perpendicular position to the abdominal wall.

dribbling from the preputial orifice immediately after urination. However, he was very satisfied with the functional and cosmetic outcome.

Discussion

Preputial urethrostomy was reported to be effective as a salvage procedure in dogs that required a prepubic urethrostomy secondary to intrapelvic urethral trauma with subsequent stricture formation (2). Pavletic and O'Bell applied preputial urethrostomy to a dog with penile necrosis (5). To our knowledge, these are the only published reports of the use of preputial urethrostomy in dogs. This technique uses the preputial cavity as a site for urethral anastomosis. Therefore, the dog can urinate through the natural orifice, avoiding the potential for urine scalding associated with urethral anastomosis to the adjacent skin. In our case, urine dribbling immediately after urination was observed. This likely resulted from the temporal accumulation of small amounts of urine in the preputial cavity. This may be prevented by reconstruction of a smaller cavity when the prepuce is sutured.

In Bradley's study (2), a caudal abdominal ventral midline incision to access the bladder and proximal urethra was made. However, the size of the prostate gland limited the amount of urethra that was brought through the abdominal incision. Pelvic symphysiotomy and bilateral pubic-ischial

osteotomy have been reported in order to gain access to, evaluate, and treat intrapelvic urethral disorders and neoplasms such as rectal, prostatic, vaginal, and urethral tumors (6,7). By combining these procedures with urethrostomies, a sufficient urethral length can be preserved. This may maintain urinary continence and reduce tension at the urethrostomy site, avoiding postoperative stricture formation. Pelvic symphysiotomy can expose the intrapelvic structures in a less invasive manner than bilateral pubic-ischial osteotomy. Bilateral pubic-ischial osteotomy may be more appropriate for lesions that require greater exposure compared to pelvic symphysiotomy. In our case, pubic-ischial osteotomy was simultaneously performed. The reluctance to use these procedures is attributed to postoperative complications, including inability to ambulate, prolonged recovery period, and degree of difficulty of the approach. Allen et al. (7) reported that 5 experimental dogs did not

show lameness postoperatively, even on the first postoperative day. In addition, Yoon et al. (8) reported that 7 dogs that underwent bilateral pubic-ischial osteotomy could ambulate normally within 3 days after surgery. In our case, the dog was ambulatory the day after surgery. These results may suggest that protracted disability should not be anticipated in most animals undergoing bilateral pubic-ischial osteotomy.

In conclusion, urinary diversion via preputial urethrostomy and total penile amputation could provide a normal anatomical appearance and prevent postoperative urine scalding. Bilateral pubic-ischial osteotomy facilitates the use of the entire length of the pelvic urethra. This series of procedures may be considered to be a surgical option for urethral disorders proximal to the scrotal lesion. Future studies with a larger number of cases are warranted to further evaluate postoperative complications.

References

1. Smeak, D.D.: Urethrotomy and urethrostomy in the dog. *Clin. Techn. Small Anim. Pract.*, 2000; 15: 25–34.
2. Bradley, R.L.: Prepubic urethrostomy. An acceptable urinary diversion technique. *Probl. Vet. Med.*, 1989; 1: 120–127.
3. Boothe, H.W.: Managing traumatic urethral injuries. *Clin. Techn. Small Anim. Pract.*, 2000; 15: 35–39.
4. Liehmann, L.M., Doyle, R.S., Powell, R.M.: Transpelvic urethrostomy in a Staffordshire bull terrier: a new technique in the dog. *J. Small Anim. Pract.*, 2010; 51: 325–329.
5. Pavletic, M.M., O'Bell, S.A.: Subtotal penile amputation and preputial urethrostomy in a dog. *J. Am. Vet. Med. Assoc.*, 2007; 230: 375–377.
6. Davies, J.V., Read, H.M.: Sagittal pubic osteotomy in the investigation and treatment of intrapelvic neoplasia in the dog. *J. Small Anim. Pract.*, 1990; 31: 123–130.
7. Allen, S.W., Crowell, W.A.: Ventral approach to the pelvic canal in the female dog. *Vet. Surg.* 1991; 20: 118–121.
8. Yoon, H.Y., Mann, F.A.: Bilateral pubic and ischial osteotomy for surgical management of caudal colonic and rectal masses in six dogs and a cat. *J. Am. Vet. Med. Assoc.* 2008; 232: 1016–1020.