

Successful management of uroperitoneum in a neonatal pony foal by tube cystotomy using infusion set tubing

Mujeeb ur Rehman FAZILI*, Shahid Hussain DAR, Hiranya Kumar BHATTACHARYYA, Abdul HAFIZ

Teaching Veterinary Clinical Complex, Faculty of Veterinary Sciences and Animal Husbandry,
Sher-e-Kashmir University of Agricultural Sciences and Technology of Kashmir, Srinagar, Kashmir, India

Received: 04.12.2011 • Accepted: 26.04.2012 • Published Online: 15.03.2013 • Printed: 15.04.2013

Abstract: A male pony foal aged 2 days, reportedly not passing urine since birth and showing moderate signs of colic, was presented for treatment. The clinical examination revealed moderate tachycardia, tachypnea, and mild abdominal distension. Uroperitoneum was confirmed by peritoneocentesis and abdominal fluid-to-serum creatinine ratio (>2:1). After stabilization of the patient, tube cystotomy was performed using infusion set tubing to bypass the urine, allowing the tear on the caudodorsal wall of the bladder to heal itself without suturing. The foal resumed normal urination on day 6 and the catheter was removed 3 days later. Complications were not detected during the 3-month observation period.

Key words: Foal, cystorrhesis, uroperitoneum, tube cystotomy, infusion set tubing

1. Introduction

Uroperitoneum subsequent to the rupture of the urinary bladder has frequently been recognized in newborn male foals (1). Clinical signs associated with uroperitoneum in the neonatal foal typically include straining to urinate, dribbling urine, and a stretched-out stance. Abdominocentesis often reveals a large volume of dilute yellow fluid with a creatinine value at least 2 times that of the serum value and is used to definitively diagnose the condition (2). Surgical repair of the urinary bladder tear is undertaken to save such foals (3). Tube cystotomy, an alternative to surgical repair of the bladder rupture, is now routinely used for the management of a ruptured urinary bladder subsequent to obstructive urolithiasis in ruminants (4,5). It results in the continuous evacuation of urine from the urinary bladder and therefore allows the tear to heal itself without suturing. Perusal of the available literature indicates that this technique has been used in just one equine case by Lavoie and Harnagel (6), using an indwelling Foley catheter. In this communication, we wish to report the successful management of a ruptured bladder in another neonatal male pony foal by tube cystotomy using a sterile infusion set tubing.

2. Case history

A male foal, aged 2 days and weighing 21 kg, was presented at the Teaching Veterinary Clinical Service Complex

with the complaint of not passing urine since birth along with occasional stretching of the body and kicking of the abdomen.

On clinical examination, the foal was active and had developed mild abdominal distension. Abdominal ballottement revealed a fluid thrill. The rectal temperature was 38.33 °C, the heart rate was 95 beats/min, and the respiratory rate was 23 breaths/min. A sample of blood (3.0 mL) was collected in a sterile serum separation tube and another 2.0 mL in a test tube with ethylenediaminetetraacetic acid (10 mg/mL). Abdominocentesis was performed using an 18-G hypodermic needle on the right side of the midline along the ventral abdomen, 5 cm caudal to xiphoid. It yielded a clear, yellow, odorless fluid that was allowed to drain freely after collecting a 10-mL sample in a sterile tube for biochemical evaluation and bacterial culture.

The animal was infused with normal saline (1.5 L), ampicillin–cloxacillin [at 15 mg/kg, intramuscularly (IM)], and meloxicam (at 0.2 mg/kg, IM) intravenously (IV), preoperatively. The foal was premedicated with xylazine at 1.0 mg/kg IV and anesthesia was induced with ketamine at 2.0 mg/kg IV 5 min later. The anesthesia was maintained by giving additional doses of xylazine–ketamine IV as a mixture. The foal was positioned in dorsal recumbency, the ventral abdomen was shaved, and the skin was

* Corresponding author: fazili_mr@yahoo.co.in

aseptically prepared. The abdominal cavity was entered via a left paramedian incision 10.16 cm long, avoiding the prepuce. The residual urine in the abdominal cavity was evacuated slowly and the partially collapsed urinary bladder located on the pelvic floor was retracted out of the abdominal incision. Umbilical remnant structures were then resected. Sterile infusion set tubing (with an angled tip and fenestrated up to 2.5 cm) was passed into the urinary bladder via a small stab incision in its dorsal wall. The extra length of the catheter was pushed up to the bladder neck, beyond the rupture site. The rent (1.3 cm long) located on the caudodorsal wall of the urinary bladder (close to its neck) was inaccessible, and was therefore left unsutured. The bladder was replaced and the abdominal incision was routinely sutured. Using braided silk (No. 1), the external end of the catheter coming out of the abdominal incision (Figure 1) was fixed to the skin with 2 stay sutures, the first at the exit point and another 7.62 cm anterior to it (Figure 2).

Antiseptic dressing of the wound was done using povidone iodine (5%). Ampicillin–cloxacillin (at 10 mg/kg, IM, twice daily) and meloxicam (at 0.2 mg/kg, IM, once daily) were prescribed for 7 and 3 days, respectively. The animal was discharged on the day of the surgery. The owner was advised to keep the surgical site clean with antiseptic dressing (twice daily). He was also directed to block the catheter externally for 3 h daily from day 4 to encourage normal urination. Follow-up was assigned to a field veterinarian who was contacted telephonically on each alternate day until suture removal and fortnightly thereafter for a period of 3 months.

3. Results and discussion

Hematobiochemical values were obtained for the packed cell volume at 49%, hemoglobin at 16.5 g/dL, total protein at 7.4 g/dL, creatinine at 2.3 mg/dL, and blood urea nitrogen at 28 mg/dL. The creatinine and blood urea nitrogen concentrations in the abdominal fluid were 5.8 mg/L and 39 mg/dL, respectively. Bacterial growth was not noticed in the culture medium up to an incubation period of 72 h.

The animal resumed normal urination on day 6 and the catheter tubing was removed 3 days later. The incision site healed uneventfully and the cutaneous sutures were removed on the day of catheter withdrawal. During the follow-up period of 3 months, no complication was reported.

Rupture of the foal's bladder occurs because of congenital defects in the bladder wall (3,7) and in the urachus (1) or compressive forces associated with parturition (8). Mendoza et al. (1) showed an association

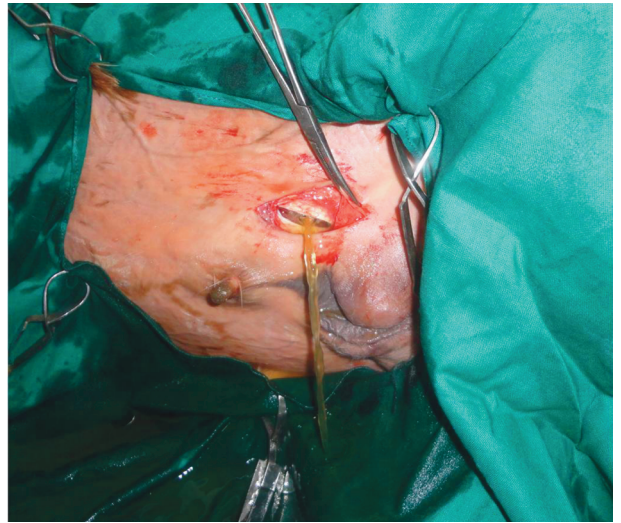


Figure 1. Catheterized urinary bladder with infusion set tubing via a pararepreputial laparotomy in a foal.



Figure 2. Foal after tube cystotomy with a catheter fixed to the skin by 2 stay sutures.

between septicemia, urinary tract infections, and rupture of the urinary tract/urachus. Colts are more at risk because of their long, narrow, high-resistance urethra, which is less likely to allow bladder emptying, resulting in cystorrhesis during parturition when high pressures are applied focally or circumferentially around the bladder (9). However, the condition does also occur in females (10).

The foal in the present case exhibited symptoms of abdominal discomfort, tachycardia, tachypnea, and fluid thrill on abdominal ballottement. Clinical signs associated with uroperitoneum in the neonatal foal appear beyond 24 to 36 h after birth and typically include straining to

urinate, dribbling urine, and a stretched-out stance (2,11). Weakness, tachycardia, tachypnea, and not sucking well are also common. A distended abdomen may be evident, and one may feel a fluid wave on ballottement of the abdomen. Occasionally, urine accumulates in the scrotum and should not be confused with a hernia (9,12). Foals may also show signs of sepsis, including fever, injected mucous membranes, diarrhea, and diseases of other body systems (9). Our foal was presented at only 48 h after birth, due to which comparatively mild changes in the various parameters were noticed, and was clinically free of infection.

Diagnosis is based on clinical findings and examination of the peritoneal fluid (12). Classic findings include hyperkalemia, hyponatremia, and hypochloremia (13), and an abdominal fluid creatinine concentration at least 2 times greater than the serum value is generally used for a definitive diagnosis (3,11). Although serum electrolyte estimation could not be conducted in our case, the typical symptoms, detection of urine in the abdomen, and a creatinine level of more than twice the value in the blood confirmed uroperitoneum. Confirmation of the diagnosis of uroperitoneum in foals of all ages can also be achieved through dye studies, contrast radiography, electrocardiography, ultrasonography, and cystoscopy (14).

Uroperitoneum is a medical emergency (6). Initial treatment aims to stabilize the patient, correct any electrolyte and acid–base abnormalities, and provide fluid volume replacement with 0.9% or 0.45% saline with 5% dextrose. In our case, 1.1 L of urine was drained from the abdomen using an 18-G hypodermic needle and an additional 0.3 L was drained upon opening the abdomen. Foals with moderate to severe abdominal distention may require peritoneal drainage to improve their cardiovascular and ventilation status. Peritoneal drainage may be performed by using teat cannulas, Foley catheters, large-gauge (16 or 14) intravenous catheters, or human peritoneal dialysis catheters.

Alternatively, calcium gluconate, glucose, sodium bicarbonate, or insulin may be administered intravenously to decrease the serum potassium concentrations. Broad-spectrum antibiotics are recommended until culture results become available (9,11). Antiinflammatory agents should be administered before the induction of general anesthesia (13).

The caudodorsal wall of the bladder was disrupted in the foal treated in the present case. When perinatal cystorrhaxis occurs, the bladder commonly ruptures in the dorsal cranial region (14), where unlike in the rest of the

bladder, the circular muscle layer is external (8). However, rupture in the ventral wall has also been reported (10).

The majority of equine neonates with uroabdomen require surgical reparation of the tear (2,10). We used a paramedian approach in our case. An elliptical skin incision at the umbilicus is also used in cases of uroabdomen in neonatal foals (14). In our case, the residual urine in the abdominal cavity was allowed to flow out slowly to avoid vascular pooling in the large capacitance vessels and cardiac arrest (15).

Cystorrhaphy is indicated for disruption of the bladder (10). The location of the tear being close to the neck of the bladder in our foal was the reason for it not being sutured. According to Bain (10), ventral tears also run longitudinally along the ventral bladder to the neck, making surgical access difficult.

The tube cystotomy technique used in our foal offers an alternative to surgical repair of the bladder rupture (6). It results in continuous evacuation of the urine from the urinary bladder and therefore allows the tear to heal itself without suturing. Tissues, such as the neonatal bladder, may be weak or friable (2). The bladder is considered to be one of the weakest tissues in the human body; nevertheless, the bladder has a high regenerative capacity and heals readily (16).

One foal was managed earlier by tube cystotomy using an indwelling Foley catheter (6). We have routinely used the easily available (in sterile pack) and cheap infusion set tubing used in the present case in small ruminants (5). The extra length of the tubing placed inside the bladder and the stay suture at the exit reduces the chances of premature falling. The tip of the catheter was angled and fenestrated up to 2.5 cm to prevent its blockage in the urinary bladder. The catheter is removed only after giving sufficient time for healing of the urinary rupture site.

The foal did not show recurrence or any other complication during the 3-month postoperative observation period. Uncomplicated uroperitoneum from a defect in the bladder has a good prognosis with appropriate care (11). However, foals with septicemia have a much poorer prognosis (3).

Tube cystotomy using infusion set tubing was found to be a useful, easy, quick, cheap, and field-applicable technique for managing cystorrhaxis in the neonatal pony foal. Such cheap techniques are particularly advantageous in developing countries where ponies are reared for draft purposes by economically weak sections of the human population. However, the technique needs evaluation in a sufficient number of cases before recommending its adoption.

References

1. Mendoza, F.J., Lopez, M., Diez, E., Perez-Ecija, A., Estepa, J.C.: Uroperitoneum secondary to rupture of the urachus associated with *Clostridium* spp. infection in a foal: a case report. *Vet. Medicina*, 2010; 55: 399–404.
2. Lillich, J.D., Fischer, A.T. Jr, DeBowes, R.M.: Bladder. In: Auer, J.A., Stick, J.A., Eds. *Equine Surgery*. 3rd edn., W.B. Saunders, Philadelphia. 2006; 877–878.
3. Butters, A.: Medical and surgical management of uroperitoneum in a foal. *Can. Vet. J.*, 2008; 49: 401–403.
4. Rakestraw, P.C., Fubini, S.L., Gilbert, R.O., Ward, J.O.: Tube cystotomy for treatment of obstructive urolithiasis in small ruminants. *Vet. Surg.*, 1995; 24: 498–505.
5. Fazili, M.R., Malik, H.U., Bhattacharyya, H.K., Buchoo, B.A., Moulvi, B.A., Makhdoomi, D.M.: Minimally invasive tube cystotomy for treatment of obstructive urolithiasis in small ruminants with intact bladder. *Vet. Rec.*, 2010; 166: 528–531.
6. Lavoie, J.P., Harnagel, S.H.: Nonsurgical management of ruptured urinary bladder in a critically ill foal. *J. Am. Vet. Med. Assoc.*, 1988; 192: 1577–1580.
7. Kablack, K.A., Embertson, R.M., Bernard, W.V., Bramlage, L.R., Hance, S., Reimer, J.M., Barton, M.H.: Uroperitoneum in the hospitalised equine neonate: retrospective study of 31 cases, 1988-1997. *Equine Vet. J.*, 2000; 32: 505–508.
8. Radostits, O.M., Gay, C.C., Hinchcliff, K.W., Constable, P.D.: Diseases of the urinary system: diseases of the bladder, ureters and urethra. In: Radostits, O.M., Gay, C.C., Hinchcliff, K.W., Constable, P.D., Eds. *A Textbook of the Diseases of Cattle, Horses, Sheep, Pigs and Goats*. 10th edn., Saunders, St. Louis, Missouri. 2006; 543–571.
9. Wilkins, P.A.: Disorders of foals. In: Reed, S.M., Bayly, W.M., Sellon, D.C., Eds. *Equine Internal Medicine*. 2nd ed., Saunders, St. Louis, Missouri. 2004; 1411–1412.
10. Bain, A.M.: Disease of foals. *Aust. Vet. J.*, 1954; 30: 9–12.
11. Robertson, J.T., Embertson, R.M.: Surgical management of congenital and perinatal abnormalities of the urogenital tract. *Vet. Clin. North Am. Equine Pract.*, 1988; 4: 359–379.
12. Rooney, J.R.: Rupture of the urinary bladder in the foal. *Vet. Pathol.*, 1971; 8: 445–451.
13. Behr, M.J., Hackett, R.P., Bentinck-Smith, J., Hillman, R.B., King, J.M., Tenant, B.C.: Metabolic abnormalities associated with rupture of the urinary bladder in neonatal foals. *J. Am. Vet. Med. Assoc.*, 1981; 178: 263–266.
14. Fischer, A.T., Yarbrough, T.Y.: Retrograde contrast radiography of the distal portions of the intestinal tract in foals. *J. Am. Vet. Med. Assoc.*, 1995; 207: 734–737.
15. Hackett, R.P.: Rupture of the urinary bladder in neonatal foals. *Compen. Cont. Educ. Pract. Vet.*, 1984; 6: S488–S492.
16. Rasmussen, F.: Biochemical analysis of wound healing in the urinary bladder. *Surg. Gynecol. Obstet.*, 1967; 124: 553–561.