

Tongue necrosis in a dog associated with the pine processionary caterpillar and its treatment

Esma YILDAR, Özlem GÜZEL*

Department of Surgery, Faculty of Veterinary Medicine, İstanbul University, 34320, Avcılar, İstanbul, Turkey

Received: 27.12.2011 • Accepted: 15.02.2012 • Published Online: 15.03.2013 • Printed: 15.04.2013

Abstract: The patient was a 3-year-old English Setter that had been in contact with *Thaumetopoea wilkinsoni* larvae. Clinical examination revealed protrusion of the tongue outside of the mouth, edematous and swollen frenulum linguae and tongue, as well as a high amount of salivation. Necrotic and ulcerated areas were determined, particularly on the apex of the tongue. Treatment was carried out using systemic antihistamines, corticosteroids, antibiotics, vitamin C, and dexpanthenol, and the patient returned to good health.

Key words: Pine processionary caterpillar, tongue necrosis, dog

1. Introduction

The pine processionary is a pest belonging to the order Lepidoptera. Members of this species form white cotton caterpillar cocoons and live in pine trees. The caterpillars damage the trees by feeding on the needles and also cause health problems in humans and animals due to their allergen structure (1–4).

There are around 200 pests belonging to the order Lepidoptera. The most common of these is the subfamily *Thaumetopoea*. This subfamily contains 2 subspecies called *Thaumetopoea pityocampa* and *Thaumetopoea wilkinsoni* Tams (2,3,5). *Th. pityocampa* is seen mostly in central and western Mediterranean countries, while *Th. wilkinsoni* is seen in the Near East and Turkey (1–4,6).

The pine processionary undergoes a total transformation (holometabolous). Its life cycle consists of 4 stages: egg, larva (caterpillar), pupa, and adult (3,5).

The egg stage begins with the deposition of eggs by adult moths on pine needles. After hatching, the larvae form a pouch with the white net secreted from the mouth, which transforms into silk thread. They spend the entire winter inside of this protective silk case, which resembles a corn cob (3).

The larvae have 5 different stages of development called L₁, L₂, L₃, L₄, and L₅. From the point of view of causing illness, the L₄ and L₅ stages are important. The reason for this is that, in their last 2 stages, the larvae have a thick covering of hairs (urticating hairs) (2,3,5).

The caterpillars reach maturity at the end of stage L₅, and, depending on the climatic properties of the region, between the end of February and the beginning of May, particularly in the early hours of the morning, they enter

the ground all together and begin the pupa stage. This mass movement of the caterpillars is called the bandwagon effect. Inspired by the bandwagon-forming behavior of the larvae, the pine processionary insect has been named the pine processionary moth (3).

The hairs on the larvae penetrate the epidermis in humans and animals and lead to the skin disease called erucism. This is caused by the fact that the hairs contain a kind of irritant and toxic protein called thaumetopoein. This protein causes urticaria by forming immunoglobulin E (IgE)-independent degranulation directly upon mast cells, as well as causing anaphylaxis by forming hypersensitivity via IgE (2,3,6–10).

The symptoms observed vary according to the exposure to the causative agent. Direct contact with the larvae causes edema, contact urticaria, conjunctivitis, temporary blindness, hypertension, and anaphylaxis. Ingestion of the larvae causes edema of the tongue and frenulum, vesicles, abdominal pain, vomiting, and gastrointestinal reactions such as gastritis and enteritis. Inhaling the toxic and irritant substance leads to breathing difficulties, rhinopharyngitis, and bronchitis (2–4,7–9,11).

Supportive treatment is administered to patients with allergic reactions. Urticating hairs embedded in the skin are removed. The affected area is cleaned with soap and water and cooling icepacks are applied. Topical or systemic antihistamines and corticosteroids are administered. In the event of airways being affected, parenteral bronchodilators are administered and, if needed, the patient is intubated and the airways kept open (2,7,9).

Tongue necrosis caused by a pine processionary in a dog, encountered for the first time in this country, along

* Correspondence: drozlemguzel@gmail.com

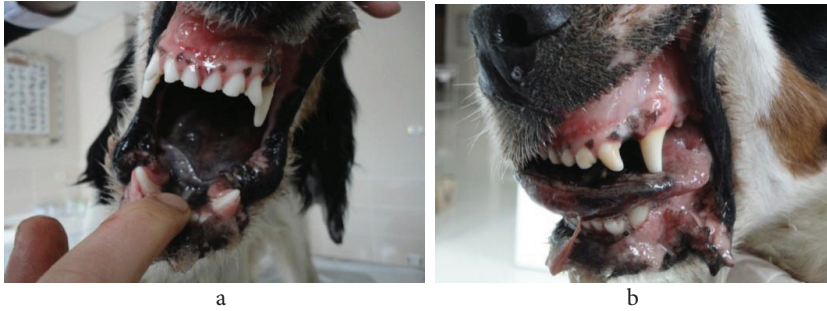

Figure 1. Protective silk case of the pine processionary caterpillar (a) and appearance of the caterpillars in the L5 stage (b).

with its treatment, was evaluated and the results obtained are presented.

2. Case history

The material of the study consisted of a 3-year-old English Setter brought to the İstanbul University Veterinary Faculty Surgery Department in April 2011, with a complaint of inability to eat, excessive salivating, and lethargy.

In the history obtained from the patient owner, it was discovered that the dog lived in a garden containing pine trees and that larvae were seen on the ground (Figures 1a and 1b).

Clinical examination revealed that the tongue protruded from the mouth, the frenulum lingua and tongue were edematous, and there was a high degree of salivation. Necrotic and ulcerated areas were determined, especially on the tongue apex (Figures 2a and 2b). Another interesting finding was the lethargy caused by the patient having been unable to eat for 2 days due to these clinical findings. Following hemogram and biochemical blood analyses, blood values were seen to be within the normal limits.

The clinical examination findings led the authors to conclude that the patient had made physical contact orally with *Th. wilkinsoni* larvae and that the clinical presentation was due to allergic reactions.

For the treatment, mechanical cleansing of the tongue was performed using 0.9% saline solution. Systemic antihistamines (Pheniramine hydrogen maleate, 0.5 mg/kg, intramuscularly (IM), Avil®, Sandoz, Turkey) and corticosteroids (methylprednisolone sodium succinate, 2 mg/kg, intravenously (IV), Prednol-L 250 mg, Mustafa Nevzat, Turkey) were administered for 3 days.

To prevent the risk of infection, ceftriaxone sodium (25 mg/kg, IM, Novosef®, Eczacıbaşı, Turkey) was given. In order to accelerate the healing of the necrotic areas on the tongue, vitamin C (Redoxon ampoule®, Bayer, Turkey) and dexpanthenol (11 mg/kg, IM, Bepanthene ampoule®, Bayer, Turkey) was administered. Due to absence of oral feeding, 5% dextrose lactated Ringer's solution was given IV. This treatment procedure was continued for 1 week.

3. Results and discussion

The follow-up clinical examination carried out a week later revealed regression of the edema in the frenulum lingua and tongue, and the return of the tongue to its normal position inside the mouth.

In the follow-up examination 10 days later, the focal points of necrosis were seen to have regressed. At this stage, the dog was able to eat on its own (Figure 3).

Routine follow-ups of the patient were continued at weekly intervals. In the examination carried out 28 days



Figures 2a and 2b. Tongue edema and necrosis in a 3-year-old English Setter due to contact with pine processionary caterpillars.

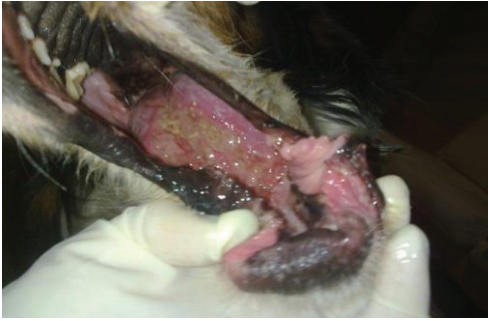

Figure 3. Appearance of the patient 10 days after treatment.

later, despite a tissue loss of approximately 1.5 cm at the tongue apex, the function of the tongue itself was seen to be entirely normal (Figures 4a and 4b).

The pine processionary caterpillar is encountered very frequently in Turkey, which is both a Mediterranean and European country. However, there is insufficient information on the allergic reactions the larvae cause in humans and animals.

For the pupa period, the pine processionary stage L_5 larvae reach the ground between the months of February and May, depending on the climatic conditions of the region (2,3,5). The case in this study involved a 3-year-old bitch that had been in contact with these larvae. April, the month in which the patient was brought to the clinic, was compatible with the life cycle of the larvae.

Especially in the L_4 and L_5 stages, larvae are covered with hairs containing a protein with a toxic effect. The exposure of humans and animals to these hairs leads to various clinical findings, depending on the affected area (2,7–9). The study patient had been in contact with these larvae via its mouth.


On entering the mouth, these larvae cause edema, necrosis, and ulcerations in the tongue and frenulum

lingua. Ingestion of the larvae leads to digestive system disorders such as abdominal pain, vomiting, and gastroenteritis (2,7). In the case presented, contact with the larvae was observed to have been via the mouth. The associated edema in the frenulum lingua and tongue, alongside the necrotic and ulcerated appearance of the tongue, was found to be compatible with sources (2,7). However, the fact that the patient exhibited no signs of abdominal pain or gastroenteritis, suggested that contact had been only by mouth and that the agent had not been swallowed.

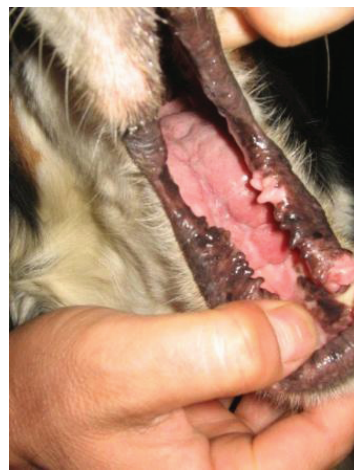In the treatment of the allergic reactions occurring following contact with larvae, it is advised to wash the area with soap and water and to administer topical and systemic antihistamines and corticosteroids (2,7,9). In the case presented, the mechanical cleansing of the oral cavity was done using saline, followed by the administration of systemic antihistamines and corticosteroids stated in literary sources (2,7,9). Antibiotic treatment was started in order to prevent the risk of infection. At the same time, to accelerate the healing of the necrotic areas on the tongue, vitamin C and dexpanthenol were added to the treatment. Hence, it was aimed to return the patient to its normal life as soon as possible.

The patient responded to the treatment positively and the necrotic area on the tongue apex healed with loss of tissue. Moreover, the tongue preserved its ability to carry out its normal functions.

In this study, a case of necrotic glossostomatitis caused by *Th. wilkinsoni* larvae in a dog was discussed for the first time in Turkey. The aim of this study was to share with colleagues the clinical picture that occurs following contact with this parasite, on which there is insufficient information, despite it being extremely widespread in Turkey.



a



b

Figures 4a and 4b. Appearance of the patient 28 days after treatment.

References

1. Salvato, P., Battisti, A., Concato, S., Masutti, L., Patarnello, T., Zane, L.: Genetic differentiation in the winter pine processionary moth (*Thaumetopoea pityocampa-wilkinsoni* complex), inferred by AFLP and mitochondrial DNA markers. *Mol. Ecol.*, 2002; 11: 2435–2444.
2. Bruchim, Y., Ranen, E., Saragusty, J., Aroch, I.: Severe tongue necrosis associated with pine processionary moth (*Thaumetopoea wilkinsoni*) ingestion in three dogs. *Toxicon*, 2005; 443–447.
3. Ipekdal, K.: Studies on bio-ecology and control of pine processionary moth *Thaumetopoea pityocampa* (Denis & Schiffermüller, 1775) (Lepidoptera: thaumetopoeidae). Hacettepe Üniversitesi, Fen Bilimleri Enstitüsü, Yüksek Lisans Tezi, 2005 (in Turkish with an abstract in English).
4. Cetin, H., Erler, F., Yanikoglu, A.: Toxicity of essential oils extracted from *Origanum onites* L. and *Citrus aurentium* L. against the pine processionary moth, *Thaumetopoea wilkinsoni* Tams. *Folia Biol. (Krakow)*, 2006; 153–157.
5. Hódar, J.A., Castro, J., Zamora, R.: Pine processionary caterpillar *Thaumetopoea pityocampa* as a new threat for relict Mediterranean Scots pine forests under climatic warming. *Biol. Conserv.*, 2003; 110: 123–129.
6. Cetin, H., Erler, F., Yanikoglu, A.: A comparative evaluation of *Origanum onites* essential oil and its four major components as larvicides against the pine processionary moth, *Thaumetopoea wilkinsoni* Tams. *Pest. Manag. Sci.*, 2007; 63: 830–833.
7. Inal, A., Altıntaş, D.U., Güvenmez, H.K., Yilmaz, M., Kendirli, S.G.: Life-threatening facial edema due to pine caterpillar mimicking an allergic event. *Allergol Immunopathol. (Madr)*, 2006; 34(4): 171–173.
8. Vega, J., Vega, J.M., Moneo, I.: [Skin reactions on exposure to the pine processionary caterpillar (*Thaumetopoea pityocampa*)]. *Actas Dermosifiliogr.*, 2011; 102(9): 658–667 (article in Spanish).
9. Diaz, J.H.: The evolving global epidemiology, syndromic classification, management, and prevention of caterpillar envenoming. *Am. J. Trop. Med. Hyg.*, 2005; 72(3): 347–357.
10. Hossler, E.W.: Caterpillars and moths: Part I. Dermatologic of encounters with Lepidoptera. *J. Am. Acad. Dermatol.*, 2010; 62: 1–10.
11. Vega, J., Vega, J.M., Moneo, I., Armentia, A., Caballero, M.L., Miranda, A.: Occupational immunologic contact urticaria from pine processionary caterpillar (*Thaumetopoea pityocampa*): experience in 30 cases. *Contact Dermatitis*, 2004; 50(2): 60–64.