

Functional anatomy and biomechanics of the equine thoracolumbar spine: a review

Hafsa ZANEB^{1*}, Christian PEHAM², Christian STANEK²

¹Department of Anatomy and Histology, University of Veterinary and Animal Sciences, Lahore, Pakistan

²Clinic for Orthopedics in Ungulates, University of Veterinary Medicine Vienna, Vienna, Austria

Received: 28.05.2012 • Accepted: 14.08.2012 • Published Online: 29.07.2013 • Printed: 26.08.2013

Abstract: Growing interest in the underlying mechanisms of an equine spine in motion has yielded very informative data. In the beginning most of the knowledge on functional anatomy of the back was provided by dissections on cadavers. With time, the approach to the subject changed and new techniques like the use of high speed cameras for collection of kinematic and kinetic data and electromyography techniques were employed. Gaits such as walk, trot, and canter are studied in more detail for the magnitude of movements of different segments of the spine during a stride, and for the temporal pattern of the muscular activity. Use of these modern techniques has added tremendously to our understanding of the functional peculiarities of the equine spine, but still there are many unanswered questions. This article reviews not only the current information on this topic, but also hints at the required future developments that can help us better understand structural peculiarities of the equine spine and their functional implications.

Key words: Equine, thoracolumbar, kinematics, functional anatomy, electromyography

1. Introduction

To date, the thoracolumbar spine is one of the lesser explored segments of the equine locomotion apparatus. The reasons are multifarious. It consists of multiple spinal articulations with little individual range of motion and thick epaxial spinal musculature (1), which make it relatively difficult to obtain clinically applicable information. With the development of more sensitive techniques, and escalating interest to explore the mechanisms underlying the equine locomotion, the volume of data available has considerably increased. These data cover varying aspects of locomotion science like the pattern and magnitude of movement of individual intervertebral joints and vertebral segments, activity patterns of various spinal and limb muscles, intrinsic stiffness of the spine, etc. Initial studies were carried out on dissected cadavers (1). They verified the ability of the isolated equine back to undergo different movements that were not modified by the appendicular musculature. Later on, studies were carried out on live horses to explore the nature and extent of these movements while standing and during different gaits. When the work of these researchers is put together, it gives a clearer picture of our present understanding of equine thoracolumbar biomechanics. In the first part of this review, the functional anatomy of the equine thoracolumbar spine is discussed, whereas the second part is a metastudy of the motion pattern of various regions of the back during various gaits.

2. Functional anatomy of the thoracolumbar spine

The spine comprises vertebrae and associated structures. The associated structures include long and short spinal ligaments, intrinsic and extrinsic spinal muscles, and structures related with articulations between bodies (intercentral) and articular processes (zygapophyseal) of the vertebrae. The thoracolumbar vertebral region of the horse consists of an average of 24 vertebrae (vertebral formula = C7, T18, L6, S5, Cd15–21). The number of thoracic or lumbar vertebrae may vary, which is compensated by a change in the number of vertebrae in an adjacent region (2). The structural and functional unit of this assembly is termed as a vertebral motion segment, which consists of 2 consecutive vertebrae and interposed soft tissue structures. The vertebral motion segment provides segmental flexibility as well as protection to the spinal cord and associated nerve roots, and it supports weight-bearing and soft tissue attachment (2).

2.1 Anatomical features of vertebrae and their functional significance

A typical vertebra consists of a vertebral body, vertebral arch, and vertebral processes.

The vertebral body is the ventrally lying cylindrical mass having a cranially convex head and a caudally concave glenoid cavity. It becomes increasingly flattened horizontally from the thoracic to the lumbar vertebrae,

* Correspondence: hafsa.zaneb@uvas.edu.pk

a feature that limits the lateral intersegmental movement without compromising the dorsoventral flexion.

The vertebral arch covers the spinal cord dorsally. It consists of 2 pedicles ventrally and a pair of laminae dorsally. The laminae provide attachment to the ligamentum flava. Cranial and caudal margins of the vertebral arch form the intervertebral foramina ventrally, which give passage to the corresponding spinal nerve and its associated structures (3).

The spinous processes project dorsally from the vertebral arch and vary in size, shape, and orientation throughout the vertebral column. They act as attachment points for ligaments and muscles that furnish support and movement to the back. The summits of T2–T9 are expanded for muscular and ligamentous (nuchal and supraspinous ligament) attachments. The summits of S2–S5 provide attachment to gluteal muscles, gluteal fascia, and the dorsal sacroiliac ligaments (2).

The direction of the spinous processes changes from dorsocaudal to dorsocranial at the anticlinal vertebra, T16 (3). This change in direction seems to be part of the mechanism that aids in resisting the forces produced by fore (together with the head and neck) and hind limbs during locomotion. Their direction again goes caudodorsal in the sacral region, thus producing a divergent interspinous space at the lumbosacral joint allowing for an increased range of movement there.

Paired cranial and caudal articular processes arise dorsolaterally from the vertebral arch. They carry articular surfaces adapted to those of the adjacent vertebrae to form zygapophyseal joints. Their size, shape, and orientation vary in different vertebral regions (2). They are directed horizontally in the thoracic vertebrae, undergo a transition at T16, and assume vertical orientation in the lumbar segment (4). Resultantly, the movement in the thoracic region is limited mostly to rotation and lateral flexion, and in the lumbar region to dorsoventral flexion.

Transverse processes project laterally and provide attachment to the spinal ligaments, rotator, and lateral flexor muscles. In the thoracic region, their size decreases from cranial to caudal members of the series. The lumbar region has elongated, horizontally flattened transverse processes that provide attachment to the large paraspinal and psoas muscles (2). Intertransverse joints are found between the last 2–3 lumbar vertebrae and at the lumbosacral joint (3,5). The size of these joints increases from the cranial to caudal direction. They help in the transfer of propulsive forces from the hind limb to the vertebral column, and together with the bodies, they resist the lateral bending and the axial rotation of the spine (2).

Mammillary processes are usually distinct from T14–T17 only. They provide additional paraspinal muscle attachment sites (3).

3. Associated spinal structures

3.1. Spinal ligaments

The longer spinal ligaments provide regional stability. They include the nuchal ligament, the supraspinous ligament, and dorsal and ventral longitudinal ligaments (2). The nuchal ligament supports the head when it is held high, thus partially relieving the load from head and neck musculature. Powerful development of this ligament has induced an enlargement of the spinous processes of the thoracic vertebrae in the region of the withers (6). At its occipital attachment it is 3 cm in height but quickly changes to a rounded shape about half as high. The supraspinous ligament is the caudal continuation of the nuchal ligament. It is strongest in the cranial thoracic region, becoming thicker and denser again in the lumbar region. It is absent between the last lumbar and the first sacral vertebrae, resulting in a greater range of flexion and extension movements. The dorsal and ventral longitudinal ligaments reinforce the intervertebral disc dorsally and ventrally and extend from the axis to the sacrum and from the eighth thoracic vertebra to the sacrum, respectively (6).

The short spinal ligaments connect the individual vertebral structures, provide segmental vertebral stability, and protect the spinal cord. They include the ligamentum flavum and interspinous and intertransverse ligaments. The ligamentum flavum supports the weight of epaxial musculature (6). The interspinous ligaments are elastic in the cranial part of the equine spine, particularly at the first thoracic joint, allowing a greater range of motion there. They prevent dorsal sliding of the vertebrae and limit ventral flexion of the spine (6). The ventral fibers of the supraspinous ligament descend to blend with the fibers of the interspinous ligament, which connects the adjacent spinous processes. The ventral fibers of the interspinous ligament, in turn, descend to blend with those of the ligamentum flavum, which connects the adjacent vertebral laminae. The thoracic spine receives additional stability through costovertebral and costotransverse ligaments, which span between the ribs and vertebral bodies and transverse processes, respectively. The intertransverse ligaments connect the transverse processes of the adjacent lumbar vertebrae and limit lateral flexion (2).

3.2. Spinal musculature

Spinal muscles can be described as intrinsic and extrinsic. Muscles that are limited to the axial skeleton only are regarded as intrinsic, whereas those having attachment on both the axial and the appendicular skeletons are termed as extrinsic spinal muscles (2).

3.3. Intrinsic spinal muscles

Epaxial intrinsic spinal muscles produce spinal extension and lateral flexion when contracting bilaterally and unilaterally, respectively. They are made up of 3 main systems: the iliocostalis and longissimus in the back

and loins; and the spinal and semispinal parts of the transversospinal components in the back and neck (3). Of these, the superficial ones are predominantly longer and more dynamic, whereas the deep short spinal muscles have more of a stabilizing function. Hypaxial muscles produce ventral and lateral flexion when contracting bilaterally and unilaterally, respectively (2).

3.4. Extrinsic spinal muscles

Extrinsic spinal muscles can also be termed as extrinsic appendicular muscles. They serve dual purpose. When the limb is fixed, they assist vertebral mobility, and when the spine is fixed, they induce limb movement.

In the thoracic limb, the dorsal muscles of the extrinsic group (brachiocephalicus, omotransversarius, trapezius, rhomboideus, and latissimus dorsi muscles) suspend the limb from the neck and trunk. The ventral extrinsic muscles (superficial and deep pectorals and serratus ventralis muscles) suspend the neck and trunk from the limbs (2).

Among the muscles of the pelvic girdle, hind limb protractors and hip flexors (sartorius, iliopsoas, tensor fascia lata, and rectus femoris muscles) are positioned cranially. Hind limb retractors and hip extensors (biceps femoris, semitendinosus, and semimembranosus muscles) lie caudally. Hind limb abductors (superficial, middle, and deep gluteal muscles) lie laterally, whereas hind limb adductors (gracilis, pectineus, and adductor muscles) are situated medially (2,3).

The hypaxial or sublumbar muscles include the psoas minor, psoas major, and iliacus. The psoas major and iliacus together form the iliopsoas, the largest flexor of the coxofemoral joint. When the limb is fixed, it induces spinal and pelvic flexion (2).

3.5. Spinal articulations

Spinal articulations in the thoracolumbar region include intercentral, zygapophyseal, and intertransverse (in the lumbar region only) articulations. Sacroiliac joints, though not part of the thoracolumbar spine, contribute to its biomechanics by transferring the propulsive movements from the hind limbs to the spine.

3.6. Intercentral articulations: vertebral motion segment

The structural and functional unit in spinal kinematics is the "intervertebral joint complex" or "motion segment", which is composed of 2 contiguous vertebrae and their associated tissues (1). The intervertebral discs occupy the spaces between adjacent vertebral bodies. The discs are thinnest in the middle thoracic region, become thicker in the lumbar and cervical regions, and are thickest in the caudal region (3). Thinner discs allow less mobility than thicker discs. The range of motion at any vertebral motion segment is small; nevertheless, the cumulative vertebral movement is magnified owing to the number of individual articulations.

3.7. Possible movements of the thoracolumbar spine

There are 6 types of movements possible at any intervertebral joint (7):

a) Dorsoventral flexion (dorsally convex curvature of the back/arching) and extension (dorsally concave curvature of the back/dipping).

b) Lateral bending (a right lateral bending presents a right concavity and a left convexity, and vice versa for the left lateral bending).

c) Axial rotation (a right rotation is the right shifting of the mid-ventral aspect of the vertebral body of one vertebra with reference to the following vertebra, and vice versa for the left rotation).

d) Transverse shearing.

e) Longitudinal compression or tension of the axial skeleton.

f) Vertical shearing.

The first 3 movements predominantly take place in each joint complex of the equine thoracolumbar spine, except in the case of intervertebral fusion (7). In the thoracic region rotation is always coupled with lateroflexion and vice versa. It is not so in the lumbar spine due to limited rotation (1).

3.8. Magnitude of movements in different spinal segments and regions

The greatest amount of dorsoventral movement takes place at the lumbosacral and the first thoracic intervertebral joints. The greatest amount of axial rotation and lateral bending occurs in the mid-thoracolumbar spine between T9 and T14. These 2 movements are always coupled together in this segment. The caudal thoracic and the lumbar spine are the least mobile regions of the equine back. The magnitude of these movements was initially determined in cadaver specimens (1,4,5,7). A comparison of these studies is presented in Table 1.

In these studies, one can compare the trends only, as the methodology and way of interpreting the results varied among researchers. Another factor to be considered is the number of specimens included in the study. The conclusions of Jeffcot and Dalin (4) are based on visual observations only, whereas in 2 later studies (1,7), photographic images were used to determine the range of movements in different segments. This could be a reason why Jeffcot and Dalin (4) did not report any detectable lateral bending and axial rotation caudal to T13. In these studies, force was applied manually but the magnitude of the applied force and its comparison with the forces in a live horse are not mentioned. One can thus find some disagreement between the results of in vitro and in vivo studies. Flexion extension movements were significantly higher in the T10–T11 segment in the study by Jeffcott and Dalin (4). They suspended weight at T13 to produce dorsiflexion, which could have magnified the movements

Table 1. Range of movements of different spinal segments (in vitro studies).

Author	Range of movements														
	T1–2/Cranial thoracic			T10–11/Mid-thoracic			T17–18/Caudal thoracic			Thoracolumbar joint/Lumbar spine			Lumbosacral joint/Sacral vertebra		
	*F/E	LB	AR	F/E	LB	AR	F/E	LB	AR	F/E	LB	AR	F/E	LB	AR
Jeffcot and Dalin (4)	NS		9.8 mm	+	±	4.0 mm	-	-	3.5 mm	-	-	NS			
Townsend et al. (7)**	8°	5°	5.5°	3.5°	11°	6.5°	4°	4.5°	1.3°	3°	4.3°	1.2°	23°	0.5°	0.5°
Denoix (1)***	1°/0.8°	25°	13°	1.3°/1°	45°	20°	2°/1.1°	30°	13°	2°/1.1°	12.3° 13° 10°				

*: F/E = Flexion/extension, LB = lateral bending, AR = axial rotation, NS = not studied. **: Values are derived from graphs (for specimens without rib cage) and may represent close approximations only. ***: Values are for left lateral bending and right rotation only.

of the close-by joints as compared to those of the caudal thoracic region. The results of these studies would have been more realistic if the forces were parallel to the vertebral column and the effect of the flexion/extension status of one region on another was also considered. These issues were addressed in the study by Denoix (1). The results of this study, particularly regarding the effect of the intact rib cage on dorsoventral movements, differ from that of Townsend et al. (7), which seems more because of a difference of methodologies in induction of movements than the way of interpretation of the results.

Flexibility of the thoracolumbar spine is also determined in terms of range of movement of its angles. In a trot, it is recorded to be highest for the thoracic angle, followed closely by the lumbosacral angle, and least for the thoracolumbar angle (8).

In another in vitro study (9), the effect of position of the spine and direction of applied force was studied on stiffness of the equine back. Positive and negative loads were applied on the spine at T12 in dorsoventral, rotated dorsoventral (30°), and laterolateral positions until an excursion of 4 cm was reached above and below the neutral position, respectively. Magnitude of the causative loads was recorded at that instant. The spines were found to be more flexible in a laterolateral direction than in dorsoventral or rotated dorsoventral directions.

3.9. Factors modifying the segmental and regional spinal movements

The overall mobility of the equine thoracolumbar spine is related to the height and width of the bodies of the vertebrae, the size and shape of the articular facets, the articulations between lumbar transverse processes, and the height and orientation of the dorsal spinous processes (5).

The size, shape, and orientation of the spinous processes together with the structure and elasticity of the supraspinous ligament determine the dorsoventral movements (1). Flexion/extension seems to be facilitated

by radially oriented flat articular facets, low spinous processes, thick intervertebral discs, and weak interspinous attachments. Contrarily, tangentially oriented articular facets, high spinous processes, thin intervertebral discs, and strong interspinous attachments appear to limit the dorsoventral movements.

Lateral bending and axial rotation are coupled together in most parts of the spine, particularly in the mid-thoracic region. In this region, the short spinous processes, asternal ribs, tangentially oriented articular facets, and thin ventral longitudinal ligament seem to support these movements (5,7). Presence of sternal ribs has an inhibitory influence on axial rotation but its effect on lateral bending has yet to be determined. Interlocking facets in the lumbar region have a limiting effect on these movements (5).

Depending upon the contribution of these morphological features towards different movements, the thoracolumbar spine can be divided into various regions.

Movements in the first thoracic joint complex (T1–2) consist principally of dorsoventral movements (5) supported by flat, oval, radially oriented facets and thickness of intervertebral discs. Axial rotation or lateral bending is limited by the sternal ribs, particularly rotation that is also limited by the height of the spinous processes attached by a strong supraspinous ligament (5).

High spinous processes and small, flat, and tangentially oriented articular facets limit dorsoventral movements of the rest of cranial thoracic region, whereas sternal ribs limit the axial rotation cranial to T9 (5).

Axial rotation and lateral bending are greatest in the segment extending from T9 to T14 due to the shortness of the spinous processes, the presence of asternal ribs, the tangentially oriented articular facets, and presence of a thin ventral longitudinal ligament.

Relatively little movement occurs in the joint complexes of T16–L6. Caudal to T14 the gradual development of radially oriented, interlocking facets appears to account for the decreased amount of axial rotation and lateral bending. In the lumbar spine decreased dorsoventral mobility could

be attributed to the width of spinous processes leading to a narrow interspinous ligament and low extensibility of the supraspinous ligament, fusion of lateral joints, and a strong ventral longitudinal ligament (7). These joints are important in the stability of the lumbar spine.

A great amount of dorsoventral flexion and extension in combination with a very small amount of axial rotation and lateral bending is found in the lumbosacral joint. Increased dorsoventral movement is contributed by diverging spinous processes, absence of a well-structured supraspinous ligament between L6 and S1 (4), small vertically oriented facets, and decreased height and increased thickness of the intervertebral disc (5).

A summary of anatomical features modifying the movements of various segments of the equine back is presented in Table 2.

4. Motion pattern of various regions of the back and lumbosacral junction in various gaits – a metastudy

The 3-D kinematic analysis of the equine thoracolumbar spine has improved our knowledge of spinal biomechanics.

In vivo studies also include electromyography (EMG) studies exploring the nature and magnitude of the trunk muscle activity during locomotion, thus providing the preliminary reference data for future research (1).

Early biomechanical studies were carried out on standing horses. Spinal movements in maximum arching, dipping, and left/right lateral flexions were measured (10). Mean dorsoventral flexibility at T16 was larger than in the previously reported in vitro studies, which could be due to contribution by motion of the lumbosacral joint. The fact that the back in a living horse is interconnected to powerful appendicular musculature whose force can potentially modify the magnitude of its movements also makes the study less comparable to in vitro studies on isolated thoracolumbar spines.

Kinematic studies were then performed on horses in different gaits. In the beginning, data were collected from skin-fixated markers only (11,12). In addition to collecting data from skin-fixated markers, dorsoventral displacements of vertebral interpolated points were determined using a third-order polynomial developed

Table 2. Movements of various segments of the equine back and the modifying anatomical features.

Vertebral region	Movements	Supporting factors (SF) / Inhibitory factors (IF)
First thoracic joint	F/E >> LB, AR*	Supporting for F/E: Flat, oval articular facets, low spinous process (T1), thick intervertebral disc, weak interspinous ligament. Inhibitory for LB and AR: Sternal ribs, strong supraspinous ligament, radially oriented large articular facets.
Cranial thoracic region	F/E < LB, AR	Inhibitory for F/E: High spinous process, small, flat, and tangentially oriented articular facets. Inhibitory for AR: Sternal ribs.
Mid-thoracic region	F/E << LB, AR	Supporting for LB and AR: Short spinous process, asternal ribs, shape of articular process, thin ventral longitudinal ligament. Inhibitory for F/E: Tangentially oriented articular facets.
Caudal thoracic region and thoracolumbar joint	F/E ≤ LB, AR	Inhibitory for F/E: A transition from tangential to radially oriented facets leads to an overall decreased magnitude of movements. Inhibitory for LB and AR: Radially oriented, interlocking facets.
Lumbar region	F/E ≥ LB, AR	Inhibitory for F/E: Width and height of spinous processes, narrow interspinous ligament, low extensibility of supraspinous ligament, strong ventral ligament. Inhibitory for AR and LB: Radially oriented interlocking facets; presence and fusion of lateral joints.
Lumbosacral joint	F/E >>> LB, AR	Supporting for F/E: A joint cavity is present, wide divergence of spinous processes, poorly developed interspinous ligament, small vertically oriented facets, decreased height and increased thickness of intervertebral disc. Inhibitory for LB and AR: Small, flat, and almost vertically oriented articular facets with a degree of interlocking.

*: F/E = Flexion/extension, LB = lateral bending, AR = axial rotation.

with the help of positions of skin-fixated markers from a horse in a trot (12). The experimental and interpolated values did not present any statistical difference except in the lumbar region. In this region, the general shape of the interpolated vertical displacement curve was conserved, but magnified by 17%. It is important to mention that one horse was used to develop this curve. In a later study (13) comprising 5 horses, it was reported that skin-fixated markers could be used for obtaining reliable data for:

- a) Flexion-extension of the thoracolumbar vertebrae and axial rotation of the sacrum at both a walk and trot.
- b) Lateral bending at walk in the mid-thoracic and lower lumbar portion only.
- c) Lateral bending for all the thoracolumbar segments during a trot.

Unreliability of the data recorded from the skin-fixated markers for lateral bending in the lower thoracic and upper lumbar region during walk could be due to coupled axial rotation, as axial rotation is greater during walk than during trot (13).

By this time, there was an active debate about the repeatability and reliability of 3-D thoracolumbar kinematic analysis carried out on a treadmill. To reach some conclusion, repeatability of a standardized protocol for quantifying back kinematics was evaluated (14) and it was concluded that analysis of back kinematics in horses can provide highly repeatable data using a treadmill. The repeatability was evaluated between strides, days, horses, and laboratories.

The results of *in vitro* and *in vivo* studies are not always in agreement with each other. Quintessentially, they ought not to be compared as such because the vertebral column is isolated during *in vitro* experiments, thus ignoring the effects of soft tissues, preloads, and muscle action. The end-range mobility determined during *in vitro* studies is also difficult to attain in real life.

4.1. Equine gaits

The more commonly studied equine gaits are walk, trot, and canter. Different regions of the equine back move with different magnitudes and frequencies during these gait patterns (Figure). As a general understanding, these movements are more pronounced and dramatic in asymmetrical gaits and restrained in symmetrical ones.

4.1.1. Walk

A walk is a symmetrical 4-beat gait. The footfall sequence is right hind, right fore, left hind, and left fore (15). At almost all times 3 legs are in contact with the ground. During the stance phase of a limb and just before the lift off, the corresponding hip or shoulder dips down because of the backward stretching of the limb. During the swing phase of a limb, the ipsilateral shoulder or hip moves up.

Flexion and extension have a bimodal pattern while lateral bending and axial rotation are unimodal during one

stride (16). The magnitude of these movements is larger at the lumbosacral joint than at the cranial vertebral segments, being minimum in the lumbar segment (Table 3).

During a stride, maximum flexion occurs earlier in the lumbosacral (LS) joint, just before and during the early ground contact of the fore limbs, followed by the thoracolumbar and thoracic angles, respectively (17). Similarly extension peaks of the LS joint occur just before and during the early stance phase of both the hind limbs. Extension of thoracolumbar and thoracic angles follows that of the lumbosacral joint successively (16,17).

Lateral bending and axial rotation follow similar patterns to segmental spinal movements. Lateral bending is maximum in the mid-thoracic region followed by the pelvic region. Just before and during the early ground contact of a hind limb, the spine undergoes lateral bending in the contralateral direction starting from the pelvic region forwards. During a stride, at any moment, the mid-thoracic and sacral segments show lateral bending in opposite directions, with its peak and direction defined by that of the thoracic region. Collectively, axial rotation on one side is maximum near the time of ground contact of the contralateral fore limb (16).

Rhodin et al. (18) studied the effect of head and neck position on the kinematics of the back at walk. Flexion/extension movements of the back with the head and neck in a high position were found to be significantly smaller than in the free and low positions for caudal thoracic and lumbar regions only. Relevance can be identified with a previous *in vitro* study by Denoix (1), in which cervical flexion induced flexion in the thoracolumbar spine. The lateral bending showed a similar trend but with the thoracic region having a larger lateral bending movement. Axial rotation was significantly smaller with the head in a high position than in free and low positions.

4.1.2. Trot

A trot is an even 2-beat diagonal symmetrical gait with 2 support and suspension phases in each stride. The right hind and left fore limbs move together, and the left hind and right fore limbs move together (15). With the diagonal pair moving together, the caudal part of the back dips down on one side while the shoulder moves up on that side. The same happens on the other side during the other half of the stride.

At trot, flexion extension movements are bimodal but less pronounced than lateral bending and axial rotation (16). Maximum flexion occurs during the late diagonal stance phase or early suspension phase, whereas maximum extension coincides with the early diagonal stance phase (16,21,22). The maximum flexion/extension is first reached by the thoracic angle followed by the thoracolumbar and lumbosacral angles, respectively. All the 3 back angles decrease during the first part of each diagonal stance

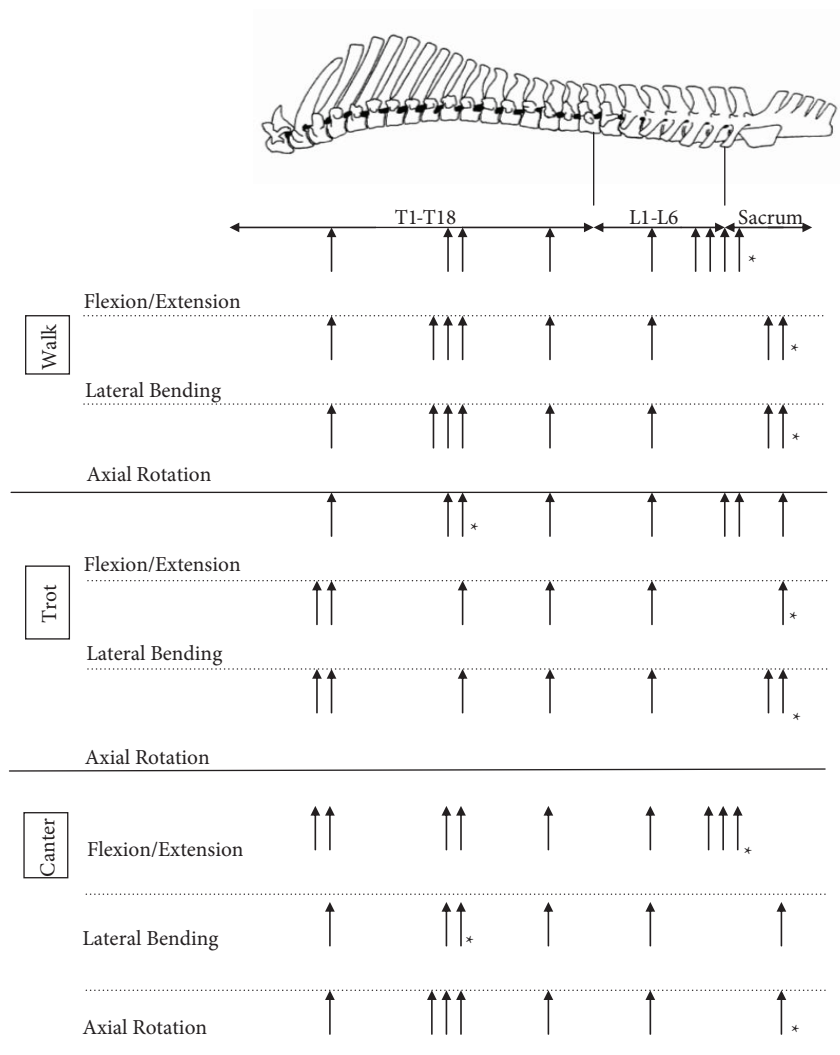


Figure. Range of movements along the equine back during walk, trot, and canter. *: The region where a particular movement is first observed during a stride cycle.

phase (extension) and increase during the second half of the stance phase (flexion). The magnitude of movement is greatest for the thoracic angle, followed by lumbosacral and thoracolumbar, respectively (21). The range of motion is less in the lumbosacral joint during trot as both the hind limbs are moving in opposite directions at any time frame. Their cumulative effect on the movements of this joint is thus not as reported in the *in vitro* studies.

Lateral bending is unimodal during one stride of trot. The thoracic and the sacral segments rotate in opposite directions at all times, producing a curvature towards the nonsupportive fore limb. Thoracic and sacral segments show greater lateral bending than the lumbar segment (22).

Axial rotation is bimodal during one stride cycle but a few vertebrae show a trimodal motion pattern (22). The rotation in one direction is led by the sacral segment,

followed by the lumbar and thoracic segments, respectively. Range of movement is greater for the sacral segment than for the mid-thoracic segment (16,22).

4.1.3. Canter

A canter is an uneven asymmetrical 3-beat gait. Like a trot, it has a diagonal pair, but has only a single suspension phase during one stride. On a left lead the foot fall sequence is right hind, left hind and right fore together, and left fore, followed by suspension. During canter the back maintains its level from right to left and just moves up and down in the front and rear. The canter and gallop are closely associated gaits, the difference being that in gallop the horse breaks the landing of the diagonal pair so that it becomes an asymmetrical 4-beat uneven gait (15).

The magnitude of movement is predominantly greater in the lumbosacral joint, particularly for flexion/

Table 3. Magnitude of movement of various regions of the thoracolumbar spine at walk, trot, and canter.

Author	Range of movements														
	T1-2/ Cranial thoracic			T10-11/ Mid-thoracic			T17-18/ Caudal thoracic			Thoracolumbar joint/ Lumbar spine			Lumbosacral joint/ Sacral vertebra		
	F/E	LB	AR	F/E	LB	AR	F/E	LB	AR	F/E	LB	AR	F/E	LB	AR
	Walk														
Faber et al. (17)	4.2 T6	4.1	4.3	8.1	5.3	5.3	7.1	2.6	11.0	7.0 L1	3.3	11.3	6.8 S3	4.9	12.6
Haussler et al. (16)		NS			NS				T14 to T16		L1 to L3		1.9	3.8	3.8
Faber et al. (14)		NS		5.7	10.4		8.6	3.7		8.0 L1	4.0 L1				12.3 S3
Licka et al. (19)	3.7 cm	3.7 cm	NS	2.9 cm	4.9 cm	NS	3.2 cm	5.5 cm	NS	5.0 cm	5.6 cm	NS	6.5 cm	4.4 cm	NS
Johnston et al. (20)*		NS		6.4	10.0		8.5	4.2		8 L1	3.6			NS	
Rhodin et al. (18)		Not mentioned		5.5			8.7			8.1 L1				Not mentioned	
	Trot														
Audigié et al. (21)**				3.9						2.9			3.8		
Faber et al. (22)	2.8 T6	4.9	5.5	4.9	4.4	3.3	3.5	3.6	4.6	3.4 L1	4.5	4.6	2.8 S3	4.0	5.7
Licka et al. (23)***	3.93 T5	3.15	NS	4.46	1.99		4.94 T16	1.85		4.91	1.89		4.55	1.89	
Haussler et al. (16)		NS			NS				T14 to T16		L1 to L3		2.4	3.7	4.4
Faber et al. (14)		NS		3.5	7.8		2.4	3.2		3.1 L1	2.5 L1				5.7 S3
Johnston et al. (20)*		NS		4.7	8.4		3.0	4.5		3.0 L1	3.5			NS	
Rhodin et al. (18)		Not mentioned		5.1			3.0			3.5 L1				Not mentioned	
	Canter														
Faber et al. (24)	12.0 T6	3.0	7.0	11.9	5.5	8.0	7.5	3.0	7.0	6.5	3.5	6.5	16.0	2.8	6.0
Haussler et al. (16)****		NS			NS				T 14 to T16		L1 to L3		5.2	4.6	5.0
							1.3	1.6	1.3	1.0	0.7	0.8			

The values by different authors may be for different vertebrae of a particular region and are tabulated here for a cursory comparison only. For details, please see the relevant study. All the movements are in degrees unless otherwise specified. *: Values are derived from graphs and may represent close approximations only. **: Values taken for thoracic, thoracolumbar, and lumbosacral angles. ***: Values are in terms of percentage of height at withers. ****: Only 2 horses were used to gather data for LS segment.

extension, followed by the thoracic and lumbar segments, respectively (16,24). Flexion/extension is unimodal for all the 3 segments. Collectively, lateral bending and axial rotation are also unimodal, but the sacral and lumbar segments also show additional rotations.

The back undergoes extension from the last part of the suspension phase until mid-stance of the diagonal limbs

and flexes during the rest of the stride cycle. The counter-clockwise rotation occurs during the stance phase of the trailing hind limb, whereas the clockwise rotation of the spine coincides with the later half of the diagonal stance phase (24). The lumbosacral joint is the first to undergo flexion/extension, followed by the lumbar and thoracic segments, respectively.

Maximum left lateral bending occurs earlier in the stride cycle in the thoracic region, followed by the lumbar and sacral segments, respectively. The range of motion is greatest in the thoracic segment, followed by the lumbar and sacral segments, respectively (24).

In the beginning of the stride cycle, all the 3 vertebral segments undergo axial rotation towards the trailing hind limb. They then rotate in the opposite direction until just before the mid-stride, where they go out of phase. This is the time when the thoracic segment shows maximal axial rotation towards the leading hind limb. After mid-stride all the 3 segments again start rotating in the direction of the trailing hind limb until they reach a maximal rotation during its stance phase.

4.2. Electromyogram studies

Information presented in the following segment of this article is extracted largely from the works of Denoix (1) and Denoix and Audigié (25).

4.2.1. Walk

During a walk, the longissimus dorsi muscle has a weak activity in the mid-stance of both hind limbs to facilitate propulsion. The rectus abdominis is silent electrically, which is correlated to the limited vertical acceleration of the abdominal visceral mass.

4.2.2. Trot

The longissimus dorsi is active during the second part of each diagonal stance phase and the first part of the swing phase. It seems to play a role in preventing the lateral bending of the trunk while inducing lumbosacral extension. It also propels and stabilizes the vertebral column by preventing passive flexion. The rectus abdominis muscle acts during the stance phase of each diagonal to limit passive vertebral extension and support visceral mass acceleration. Muscles of both sides are active twice in a stride because of the symmetric nature of the gait.

4.2.3. Canter

The longissimus dorsi muscle is active once per stride from after the end of the diagonal stance phase to the beginning

of the following one to prepare the landing of both hind limbs and to induce spinal extension before fore limb landing.

The rectus abdominis muscle is active during the support phase of the nonleading diagonal. It acts to support the visceral mass and to initiate thoracolumbar flexion during the leading fore limb stance phase and suspension phase. Bursts of activity can be observed simultaneously in the longissimus and rectus abdominis muscles on the side opposite to the leading fore limb during the stance phase of the trailing hind limb.

The obliquus internus abdominis muscle is active during the diagonal stance phase to prepare for the spinal flexion that occurs during the last part of the stance phase, contributing to the visceral mass support and trunk lateroflexion. Muscle of the side opposite to the leading fore limb shows additional bursts of activity at the end of the support phase and beginning of the swing phase (1,25).

5. Conclusion

Our knowledge of the equine back biomechanics can help develop a realistic model while keeping in consideration its intrinsic abilities, the interplay of forces, and the factors modifying its movements. It could be a computer-based program where input in the form of speed, inclination of the ground surface, and magnitude of the propulsive forces can provide an output in the form of predicted spinal movements. Before such a model can be developed, there is a need to carry out in-depth studies on:

1. Kinematics of canter and gallop incorporating the whole thoracolumbar spine.
2. Functional co-relation of extrinsic spinal musculature (ESM) with various gaits.
3. Compensatory mechanisms of ESM during various degrees and types of lameness.
4. The exact role of hind limb musculature in propulsion by studying its pattern of activity during various phases of gaits.

References

1. Denoix, J.M.: Spinal biomechanics and functional anatomy. *Vet. Clin. North Am. Equine Pract.*, 1999; 15: 27–60.
2. Haussler, K.K.: Anatomy of the thoracolumbar vertebral region. *Vet. Clin. North Am. Equine Pract.*, 1999; 15: 13–26.
3. Getty, R., Sisson, S., Grossman, J.D.: *Sisson and Grossman's The Anatomy of the Domestic Animals*. 5th edn., W.B. Saunders Co., Philadelphia. 1975.
4. Jeffcott, L.B., Dalin, G.: Natural rigidity of the horse's backbone. *Equine Vet. J.*, 1980; 12: 101–108.
5. Townsend, H.G.G., Leach, D.H.: Relationship between intervertebral joint morphology and mobility in the equine thoracolumbar spine. *Equine Vet. J.*, 1984; 16: 461–465.
6. König, H.E.: Axial skeleton. In: König, H.E., Liebich, H.G., Constantinescu, G.M., Bowen, M., Dickomeit, M., Shook, K., Weller, R., Eds. *Veterinary Anatomy of Domestic Mammals*. Schattauer, Stuttgart. 2009; 49–112.
7. Townsend, H.G.G., Leach, D.H., Fretz, P.B.: Kinematics of the equine thoracolumbar spine. *Equine Vet. J.*, 1983; 15: 117–122.
8. Audigié, F., Pourcelot, P., Degueurce, C., Denoix, J.M., Geiger, D.: Kinematics of the equine back: flexion-extension movements in sound trotting horses. *Equine Vet. J., Suppl.*, 1999; 31: 210–213.
9. Schlacher, C., Peham, C., Licka, T., Schobesberger, H.: Determination of the stiffness of the equine spine. *Equine Vet. J.*, 2004; 36: 699–702.

10. Licka, T., Peham, C.: An objective method for evaluating the flexibility of the back of standing horses. *Equine Vet. J.*, 1998; 30: 412–415.
11. Degueurce, C., Dietrich, G., Pourcelot, P., Denoix, J.M., Geiger, D.: Three-dimensional kinematic technique for evaluation of horse locomotion in outdoor conditions. *Med. Biol. Eng. Comput.*, 1996; 34: 249–252.
12. Pourcelot, P., Audigié, F., Degueurce, C., Denoix, J.M., Geiger, D.: Kinematics of the equine back: a method to study the thoracolumbar flexion-extension movements at the trot. *Vet. Res.*, 1998; 29: 519–525.
13. Faber, M., Schamhardt, H., van Weeren, R., Barneveld, A.: Methodology and validity of assessing kinematics of the thoracolumbar vertebral column in horses on the basis of skin-fixed markers. *Am. J. Vet. Res.*, 2001; 62: 301–306.
14. Faber, M., Johnston, C., van Weeren, P., Barneveld, A.: Repeatability of back kinematics in horses during treadmill locomotion. *Equine Vet. J.*, 2002; 34: 235–241.
15. Barrey, E.: Inter-limb coordination. In: Back, W., Clayton, H.M., Eds. *Equine Locomotion*. Saunders Ltd., London. 2001; 77–94.
16. Haussler, K.K., Bertram, J.E., Gellman, K., Hermanson, J.W.: Segmental in vivo vertebral kinematics at the walk, trot and canter: a preliminary study. *Equine Vet. J. Suppl.*, 2001; 33: 160–164.
17. Faber, M., Schamhardt, H., van Weeren, R., Johnston, C., Roepstorff, L., Barneveld, A.: Basic three-dimensional kinematics of the vertebral column of horses walking on a treadmill. *Am. J. Vet. Res.*, 2000; 61: 399–406.
18. Rhodin, M., Johnston, C., Holm, K.R., Wennerstrand, J., Drevemo, S.: The influence of head and neck position on kinematics of the back in riding horses at the walk and trot. *Equine Vet. J.*, 2005; 37: 7–11.
19. Licka, T.F., Peham, C., Zohmann, E.: Treadmill study of the range of back movement at the walk in horses without back pain. *Am. J. Vet. Res.*, 2001; 62: 1173–1179.
20. Johnston, C., Holm, K.R., Erichsen, C., Eksell, P., Drevemo, S.: Kinematic evaluation of the back in fully functioning riding horses. *Equine Vet. J.*, 2004; 36: 495–498.
21. Audigié, F., Pourcelot, P., Degueurce, C., Denoix, J.M., Geiger, D.: Kinematics of the equine back: flexion-extension movements in sound trotting horses. *Equine Vet. J.*, 1999; 31: 210–213.
22. Faber, M., Johnston, C., Schamhardt, H., van Weeren, R., Roepstorff, L., Barneveld, A.: Basic three-dimensional kinematics of the vertebral column of horses trotting on a treadmill. *Am. J. Vet. Res.*, 2001; 62: 757–764.
23. Licka, T., Peham, C., Zohmann, E.: Range of back movement at trot in horses without back pain. *Equine Vet. J.*, 2001; 33: 150–153.
24. Faber, M., Johnston, C., Schamhardt, H.C., van Weeren, P., Roepstorff, L., Barneveld, A.: Three-dimensional kinematics of the equine spine during canter. *Equine Vet. J.*, 2001; 33: 145–149.
25. Denoix, J.M., Audigié, F.: The neck and back. In: Back, W., Clayton, H.M., Eds. *Equine Locomotion*. Saunders Ltd., London. 2001; 167–191.