

## Caspase-1, -2, and -3 gene expression is enhanced in the heart and lung of chickens with pulmonary hypertension (ascites)

Hossein HASSANPOUR<sup>1\*</sup>, Masood TESHFAM<sup>2</sup>, Hassan MOMTAZ<sup>3</sup>, Hamed ZAREI<sup>4</sup>, Shahab BAHADORAN<sup>5</sup>

<sup>1</sup>Department of Basic Sciences, Faculty of Veterinary Medicine, Shahrekord University, Shahrekord, Iran

<sup>2</sup>Department of Physiology, Faculty of Specialized Veterinary Sciences, Science and Research Branch, Islamic Azad University, Tehran, Iran

<sup>3</sup>Department of Microbiology, Faculty of Veterinary Medicine, Shahrekord Branch, Islamic Azad University, Shahrekord, Iran

<sup>4</sup>Department of Basic Science, Faculty of Veterinary Medicine, Garmsar Branch, Islamic Azad University, Garmsar, Iran

<sup>5</sup>Department of Clinical Sciences, Faculty of Veterinary Medicine, Shahrekord University, Iran

Received: 18.02.2013 • Accepted: 04.07.2013 • Published Online: 28.02.2014 • Printed: 28.03.2014

**Abstract:** To investigate the involvement of apoptosis in the pathogenesis of T3-induced pulmonary hypertension in broiler chickens, caspase-1, -2, and -3 gene expressions were evaluated by semiquantitative RT-PCR in the lungs and left and right heart ventricles. One-day-old fast-growing chickens were randomly divided into 2 equal groups with 3 replicates per group. Chicks were reared for 7 weeks under standard conditions. T3 as a thyroid hormone was added to the ration after week 1 of rearing. Pulmonary hypertension was induced at 49 days based on RV/TV ratio index. The caspase genes were constitutively expressed in the lung and right and left ventricles of intact and pulmonary hypertensive broiler chickens. The relative amount of caspase-1, -2, and -3 mRNA in the lung and right and left ventricles of the heart was higher in pulmonary hypertensive broilers than in control broilers ( $P < 0.05$ ). It is speculated that increased mRNA levels of caspase in the lungs and hearts of pulmonary hypertensive broilers could be evidence of upregulated apoptosis, which is involved in the pathophysiology of broiler chickens with pulmonary hypertension.

**Key words:** Caspase, apoptosis, broiler, pulmonary hypertension, ascites

### 1. Introduction

Pulmonary hypertension syndrome (as ascites in the clinical aspect) is a metabolic impairment characterized by hypoxemia, overload of the cardiopulmonary system, venous and heart congestion, right ventricular hypertrophy, and a flaccid heart (1). Broilers are more sensitive to heart failure in comparison with other strains of chickens. Factors such as body performance, oxygen demands, hematological parameters, and cellular interactions may all be involved in the resistance or susceptibility of broilers to heart failure and pulmonary hypertension syndrome (PHS) (2). This syndrome is the most important cardiomyopathy in industrial broilers (3,4). It is

estimated that 5% of broilers die of this syndrome; considering that an estimated 40 billion broilers are produced annually around the world, it is evident that the economic losses due to PHS are significant (1).

Many studies have reported that different causes such as altitude, cold stress, lighting, air quality, ventilation, high nutrient density rations, and incubator environment have all been implicated in the development of pulmonary hypertension (5,6). The pathogenesis of pulmonary

hypertension is a complicated, multifactorial process in which the combined effects of pulmonary artery vasoconstriction, vascular remodeling, and thrombosis are involved in a continuous high pulmonary vascular resistance (7–9). Vascular remodeling is associated with low-grade inflammation, vascular fibrosis, and apoptosis (10).

Apoptosis, or programmed cell death, is a multipathway biological process that contributes in many physiological and pathological phenomena. Multicellular organisms regularly eliminate and renew cells to maintain their homeostasis. Abnormal function of this process has been implicated in atherosclerosis, cancer, heart failure, and pulmonary hypertension (10,11).

At the cellular and molecular levels, apoptosis is identified by morphological and biochemical changes such as cell shrinkage, formation of apoptotic bodies, caspase activation, chromatin condensation, and DNA fragmentation (10,12). Many molecular processes of apoptosis are mainly mediated by particular cysteine proteases named caspase. Caspases are enzymes with a crucial cysteine residue and proteolytic function. They

\* Correspondence: hassanpour-h@vet.sku.ac.ir

cleave other cytoplasmic proteins containing aspartic acid residues. The name of caspase derives from its specialized function: cysteine-aspartic acid-proteases (13). Ten major caspases have been determined as follows: initiators (caspase-2, -8, -9, and -10), effectors or executioners (caspase-3, -6, and -7), and inflammatory caspases (caspase-1, -4, and -5). Other caspases have been reported such as caspase-11, a regulator of apoptosis and cytokine maturation in septic shock; caspase-12, a mediator of endoplasmic reticulum-specific apoptosis and cytotoxicity due to amyloid- $\beta$ ; caspase-13, a cysteine protease identified in cattle; and caspase-14, a highly expressed caspase in embryonic tissues (14).

The objective of this study was to determine levels of caspase-1, -2, and -3 mRNA expression as candidates of inflammatory, initiator, and effector caspases in the lung and right and left ventricles of the heart in pulmonary hypertensive broiler chickens induced experimentally by 3,5,3'-L-triiodothyronine ( $T_3$ ). Thyroid hormones increase metabolism, oxygen consumption, and cardiovascular derangements. It is well established that hyperthyroidism induces a hyperdynamic cardiovascular state (high cardiac output with low systemic vascular resistance), which is associated with a faster heart rate, enhanced ventricular systolic and diastolic function, cardiac hypertrophy, and pulmonary hypertension (1,15). Caspase-1 (stimulated by inflammatory agents) and caspase-2 could be evidence of activation in the initial levels of apoptotic processes, while caspase-3 could show the activation of the execution pathway in apoptosis. The execution pathway results in characteristic cytomorphological features including cell shrinkage, chromatin condensation, formation of cytoplasmic blebs and apoptotic bodies, and finally cell death (16).

## 2. Materials and methods

### 2.1. Animals

Forty-two fast-growing chickens (Ross 308) of 1 day old were randomly assigned to 2 equal groups (1 control and 1 treatment) with 3 replicate pens per group and 7 chickens per pen. Chicks were reared in the floor pens (wood shaving litter) for 7 weeks under standard conditions, provided with ad libitum access to water and a standard basal diet. The basal diets were in mash form and formulated for starter (1 to 11 days), grower (12 to 25 days), and finisher (26 to 49 days) growth periods. The metabolizable energy (ME/kg of diet) and crude protein of the diet in each period were respectively as follows: starter, 13 MJ and 230 g/kg; grower, 13 MJ and 200 g/kg; finisher, 13 MJ and 180 g/kg. In the treatment group, thyroid hormone, i.e.  $T_3$  (Sigma Chemical Co.), was added to the diet (1.5 mg  $T_3$ /kg) after week 1 of rearing (17).

### 2.2. Assessment of right ventricular hypertrophy

At 49 days of age, 12 chicks from each group were randomly selected and then killed by decapitation. Right ventricular hypertrophy was determined as described by Hassanpour et al. (17). The heart was resected, the atria were removed to the plane of the atrial-ventricular valves, and then the total ventricles (TV) were weighed. The right ventricle (RV) was then dissected free of the left ventricle and septum. The RV was weighed and the RV/TV ratio was calculated. PHS was defined as having a RV/TV ratio of greater than 0.29 (18). The right and left ventricles and lungs were immediately frozen in the liquid nitrogen and stored at  $-70^\circ\text{C}$  for subsequent RNA analysis.

### 2.3. RNA extraction of lung and heart tissues

Total RNA was extracted from lungs and right and left ventricular tissues using TRIzol reagent (Invitrogen, Karlsruhe, Germany). Homogenized lung tissue (100 mg) was prepared in digestion buffer. The homogenate was mixed with chloroform. After centrifuging the mixture, total RNA settled in the upper aqueous phase. Following precipitation with isopropanol, the RNA pellet was rinsed with ethanol. The samples of RNA were resuspended in DEPC-treated water. To remove eventual residual DNA, the RNA was treated by DNase; the RNA was then measured and qualified by spectrophotometry. Only RNA with an absorbance ratio ( $A_{260}/A_{280}$ ) of  $>1.9$  was used for synthesis of cDNA. To analyze RNA, electrophoresis was done on 2% agarose gel, which was then stained with ethidium bromide.

### 2.4. Semiquantitative RT-PCR

Expression of caspases-1, -2, and -3 along with the  $\beta$ -actin gene as housekeeping control was studied by reverse-transcribed polymerase chain reaction (RT-PCR) using the SuperScript One-Step RT-PCR kit with Platinum Taq (Invitrogen, Karlsruhe, Germany). The primer sequences are listed in the Table. Caspase primers were designed based on their nucleotide sequences in GenBank (accession numbers are given in the Table). For  $\beta$ -actin, used as a housekeeping gene, previously described primer pairs (17) were used. Reverse transcription was performed at  $50^\circ\text{C}$  for 30 min. The amplification step consisted of 24–27 cycles (leading to linear range of amplification): denaturation at  $94^\circ\text{C}$  for 40 s, annealing for 50 s at  $60$ – $64^\circ\text{C}$ , and extension of primers for 50 s at  $72^\circ\text{C}$ . The products were then held at  $72^\circ\text{C}$  for 5 min for DNA extensions to occur. Gel electrophoresis and then staining with ethidium bromide were done for PCR products of caspases and  $\beta$ -actin to visualize the bands. By Photo-Capt V.99 Image Software, density of bands was calculated and

**Table.** Primers used for RT-PCR analysis of chicken mRNAs.

Gene	5'-primer	3'-primer	Cycles, annealing temperature	Size of PCR product	Accession no.
$\beta$ -Actin	ACTGGATTTTCGAGCAGGAGAT	TTAGAAGCATTTGCGGTGGACAA	24, 60 °C	468 bp	L08165
Caspase-1	CGGCCAGCGCCATCTTCATT	AGGGAGCTGTACAGTGCGT	25, 64 °C	347 bp	AF031351.1
Caspase-2	TGGCACTGATGGCAAACCTCC	ATCGGAGCGTGTAGGCAAAC	27, 64 °C	238 bp	U64963.1
Caspase-3	TTCAGGCACGGATGCAGATG	TTCCTGGCGTGTTCCTTCAG	25, 64 °C	426 bp	GU230786.1

Sense (5'-primer) and antisense (3'-primer) primer sequences.

relative densities were expressed as caspase (-1, -2, and -3) /  $\beta$ -actin density.

### 2.5. Statistical analysis

All results are represented as mean  $\pm$  SEM. The statistical analysis was carried out using SPSS 14.0 (SPSS Inc., Chicago, IL, USA). Comparisons were made between control and pulmonary hypertensive chickens using the Student t-test. Differences were considered significant at  $P < 0.05$ .

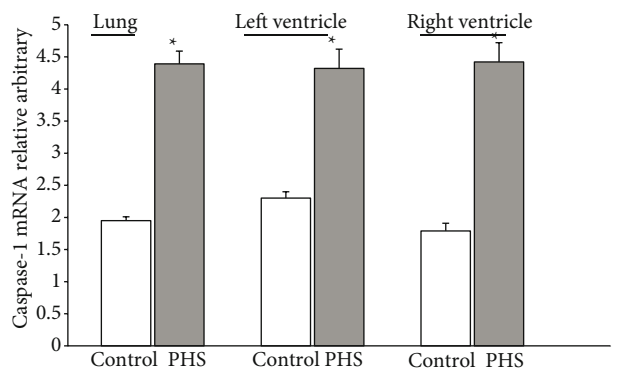
## 3. Results

### 3.1. Right ventricular hypertrophy

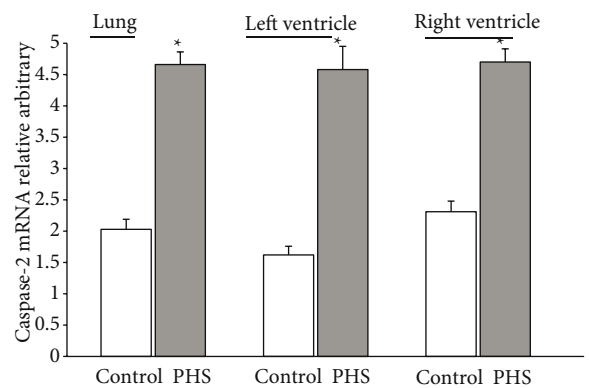
The RV/TV ratio was measured as an index of right ventricular hypertrophy and pulmonary hypertension (18). The values of this index in treated and control groups at 49 days were  $0.242 \pm 0.013$  and  $0.30 \pm 0.010$ , respectively. As noticed, the increasing of the RV/TV ratio was significant ( $P < 0.05$ ) in the treated group (25%).

### 3.2. Caspase-1, -2, and -3 mRNA expression in the lung and heart

Caspase-1, -2, and -3 gene expression was determined by semiquantitative RT-PCR in the lung and right and left heart ventricles of broiler chickens with PHS. RT-PCR results are shown in Figures 1–4. The expression of  $\beta$ -actin was detected, which was consistent for all groups. The caspase-1, -2, and -3 genes were expressed in the lungs and the right and left ventricles of control and  $T_3$ -treated broilers. The relative amount of caspase-1, -2, and -3 mRNA expression in the lungs and right and left ventricles of hearts was significantly ( $P < 0.05$ ) higher in  $T_3$ -treated broilers than in control broilers at 49 days of age. The increasing amounts of caspase-1 were 125% in the lungs, 88% in the left ventricle, and 147% in the right ventricle of the respective control at 49 days of age (Figure 1). The increasing amounts of caspase-2 were 130% in the lungs, 183% in the left ventricle, and 104% in the right ventricle at 49 days of age (Figure 2). The increasing

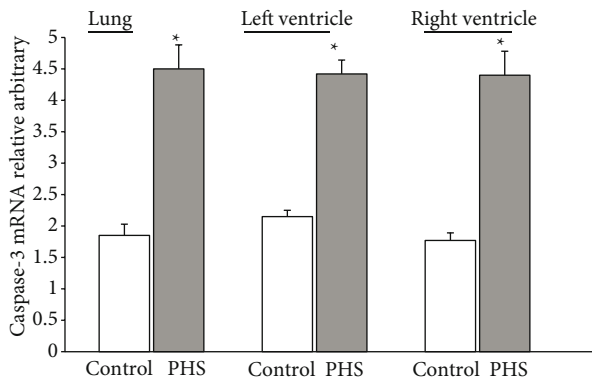


**Figure 1.** Comparison of relative density of caspase-1/ $\beta$ -actin PCR products in the lungs and left and right ventricles of hearts between control and pulmonary hypertensive chickens (PHS). Values are means  $\pm$  SEM. \*:  $P < 0.05$  from corresponding control.

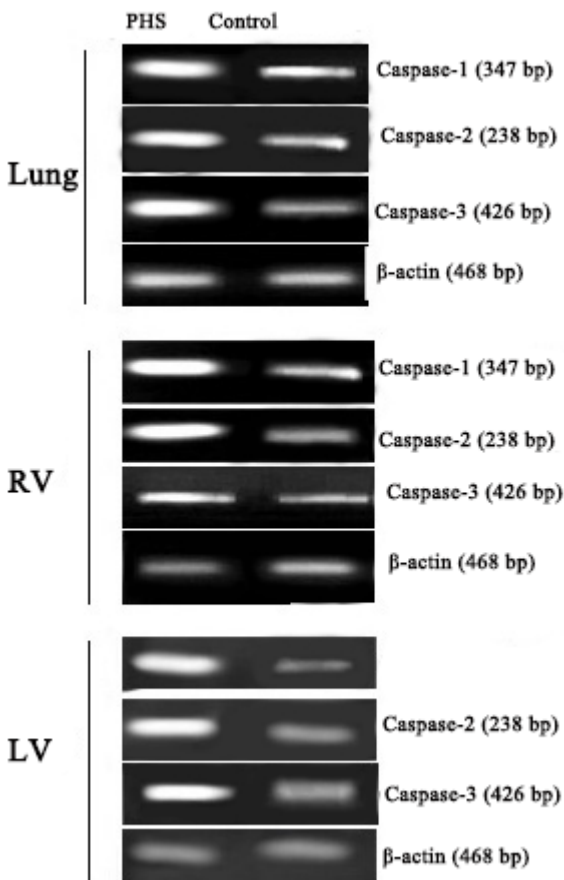


**Figure 2.** Comparison of relative density of caspase-2/ $\beta$ -actin PCR products in the lungs and left and right ventricles of hearts between control and pulmonary hypertensive chickens (PHS). Values are means  $\pm$  SEM. \*:  $P < 0.05$  from corresponding control.

amounts of caspase-3 were 143% in the lungs, 106% in the left ventricle, and 149% in the right ventricle at 49 days of age (Figure 3).



**Figure 3.** Comparison of relative density of caspase-3/ $\beta$ -actin PCR products in the lungs and left and right ventricles of hearts between control and pulmonary hypertensive chickens (PHS). Values are means  $\pm$  SEM. \*:  $P < 0.05$  from corresponding control.



**Figure 4.** Gel electrophoresis of semiquantitative RT-PCR for determination of caspase-1, -2, and -3 mRNA levels of lung and left (LV) and right (RV) heart ventricles in control and pulmonary hypertensive chickens (PHS).  $\beta$ -Actin was the housekeeping gene.

#### 4. Discussion

This research evaluated mRNA levels of 3 types of caspase (i.e. caspase-1, -2, and -3) in the lungs and left and right heart ventricles of pulmonary hypertensive broilers. According to Wideman (18), there is a positive correlation between right ventricular hypertrophy and pulmonary arterial pressure, and increasing of the RV/TV ratio could be evidence of PHS. Accordingly, in 49 days of rearing, this index (RV/TV ratio) confirmed  $T_3$ -induced PHS.

It is clear that apoptosis occurs under both physiological and pathological conditions. Detection of caspase mRNA in the hearts and lungs of intact and pulmonary hypertensive chickens was thus predictable. During the past few years, there has been accumulating evidence in both human and animal models suggesting that apoptosis may be an important mode of cell death during cardiomyopathies (19,20). Evidence of cardiomyocyte apoptosis has been noted across different species (mouse, rat, rabbit, dog, sheep, pig) and observed in different experimental models (21). Initiation of apoptosis is associated with activation of the upstream cascade, including the release of cytochrome C from mitochondria to cytoplasm and the processing of proteolytic caspases (21). The activation of caspases leads to fragmentation of various cytoplasmic proteins, including contractile proteins, which result in systolic dysfunction (21). Cytochrome C release leads to processing of caspase-3. In cardiomyopathic hearts, caspase-3 is upregulated, and cleavage of caspase-3 to split-active protease is also observed. The activation of caspase-3 usually leads to cleavage of cytoplasmic and nuclear substrates for manifestation of apoptosis (21).

Merkle et al. indicated an important role for caspase-1 in the development of heart failure. Caspase-1 is upregulated in experimental and in human heart failure and acts as a potent proapoptotic caspase both in isolated cardiomyocytes and in vivo. They also confirmed that caspase-1 protein is upregulated in murine heart failure, which corroborates earlier data obtained on the mRNA level (22). The early and parallel occurrence of caspase-1 expression and cardiomyocyte apoptosis supports the notion that these 2 events are causally related. This is followed by myocardial remodeling and development of overt heart failure (22). Heinke et al. found that the expression of both caspase-2 and -3 elevates in the left ventricle of dogs with heart failure and over-expression of caspase-2 results in apoptosis (23).

It has been reported that apoptosis is involved in pathophysiology and pathogenesis of mammal pulmonary hypertension and free radicals are an important factor in activation of caspases and induction of apoptosis (10). Progressive hypoxia developing in chickens with pulmonary hypertension can cause increased free radicals that influence the metabolic systems, including cardiac systems, in pulmonary hypertensive birds (1,24,25).

The present study revealed higher expression of apoptosis-related genes, i.e. caspase-1, -2, and -3, in the hearts and lungs of pulmonary hypertensive chickens, which could support high apoptosis in those tissues as according to the mentioned studies.

In conclusion, our data show that caspase-1, -2, and -3 genes are normally expressed in the lungs and heart ventricles of broilers. It is probable that increased mRNA levels of caspases in the lungs and hearts of pulmonary hypertensive broilers could be evidence of upregulated

apoptosis, which is involved in the pathophysiology of broiler chickens with pulmonary hypertension. However, this study is the first step for future studies; and other methods such as immunohistochemistry would be helpful to confirm enhanced apoptosis in pulmonary hypertension.

### Acknowledgments

This work was supported by funds granted by the Applied Research Center, Vice Chancellor for Research of Islamic Azad University, Science and Research Branch.

### References

1. Baghbazadeh A, Decuyper E. Ascites syndrome in broilers: physiological and nutritional perspectives. *Avian Pathol* 2008; 37: 117–126.
2. Teshfam DM, Nikbakht Brujeni G, Hassanpour H. Evaluation of endothelial and inducible nitric oxide synthase mRNA expression in the lung of broiler chickens with developmental pulmonary hypertension due to cold stress. *Br Poult Sci* 2006; 47: 223–229.
3. Olkowski AA. Pathophysiology of heart failure in broiler chickens: structural, biochemical, and molecular characteristics. *Poult Sci* 2007; 86: 999–1005.
4. Wideman RF, Rhoads DD, Erf GF, Anthony NB. Pulmonary arterial hypertension (ascites syndrome) in broilers: a review. *Poult Sci* 2013; 92: 64–83.
5. Balog JM. Ascites syndrome (pulmonary hypertension syndrome) in broiler chickens: are we seeing the light at the end of the tunnel? *Avian Poult Biol Rev* 2003; 14: 99–126.
6. Ipek A, Sahar U. Effects of cold stress on broiler performance and ascites susceptibility. *Asian Austral J Anim Sci* 2006; 19: 734–738.
7. Yuan JXJ, Rubin LJ. Pathogenesis of pulmonary arterial hypertension. *Circulation* 2005; 111: 534–538.
8. Rabinovitch M. Molecular pathogenesis of pulmonary arterial hypertension. *J Clin Invest* 2008; 118: 2372–2379.
9. Humbert M, Morrell NW, Archer SL, Stenmark KR, MacLean MR, Lang IM, Christman BW, Weir EK, Eickelberg O, Voelkel NF. Cellular and molecular pathobiology of pulmonary arterial hypertension. *J Am Coll Cardiol* 2004; 43: S13–S24.
10. Gurbanov E, Shiliang X. The key role of apoptosis in the pathogenesis and treatment of pulmonary hypertension. *Eur J Cardio-Thoracic Surg* 2006; 30: 499–507.
11. Riley DJ, Thakker-Varia S, Wilson FJ, Poiani GJ, Tozzi CA. Role of proteolysis and apoptosis in regression of pulmonary vascular remodeling. *Physiol Res* 2000; 49: 577–585.
12. Zimmermann KC, Bonzon C, Green DR. The machinery of programmed cell death. *Pharmacol Ther* 2001; 92: 57–70.
13. Nicholson DW, Thornberry NA. Caspases: killer proteases. *Trends Biochem Sci* 1997; 22: 299–306.
14. Elmore S. Apoptosis: a review of programmed cell death. *Toxicol Pathol* 2007; 35: 495–516.
15. Fazio S, Palmieri EA, Lombardi G, Biondi B. Effects of thyroid hormone on the cardiovascular system. *Recent Prog Horm Res* 2004; 59: 31–50.
16. Igney FH, Krammer PH. Death and anti-death: tumour resistance to apoptosis. *Nat Rev Cancer*, 2002; 2: 277–288.
17. Hassanpour H, Momtaz H, Shahgholian L, Bagheri R, Sarfaraz S, Heydaripoor B. Gene expression of endothelin-1 and its receptors in the heart of broiler chickens with T3-induced pulmonary hypertension. *Res Vet Sci* 2011; 91: 370–375.
18. Wideman RF. Pathophysiology of heart/lung disorders: pulmonary hypertension syndrome in broiler chickens. *World's Poult Sci J* 2001; 57: 289–307.
19. Bernecker OY, Huq F, Heist EK, Podesser BK, Hajjar RJ. Apoptosis in heart failure and the senescent heart. *Cardiovasc Toxicol* 2003; 3: 183–190.
20. Kumar D, Sudha T, Singal PK. Can apoptosis explain heart failure? *Kuwait Med J* 2003; 35: 86–90.
21. Kang PM, Izumo S. Apoptosis and heart failure: a critical review of the literature. *Circ Res* 2000; 86: 1107–1113.
22. Merkle S, Frantz S, Schon MP, Bauersachs J, Buitrago M, Frost RJA, Schmitteckert EM, Lohse MJ, Engelhardt S. A role for caspase-1 in heart failure. *Circ Res* 2007; 100: 645–653.
23. Heinke MY, Yao M, Chang D, Einstein R, dos Remedios CG. Apoptosis of ventricular and atrial myocytes from pacing-induced canine heart failure. *Cardiovasc Res* 2001; 49: 127–134.
24. Moghaddam AKZ, Hassanpour DH, Mokhtari A. Oral supplementation with vitamin C improves intestinal mucosa morphology in the pulmonary hypertensive broiler chicken. *Br Poult Sci* 2009; 50: 175–180.
25. Arab HA, Jamshidi R, Rassouli A, Shams G, Hassanzadeh MH. Generation of hydroxyl radicals during ascites experimentally induced in broilers. *Br Poult Sci* 2006; 47: 216–222.