

Effects of acetic acid supplementation in broiler chickens orally challenged with *Salmonella* Pullorum

Gulbeena SALEEM^{1*}, Rukhshanda RAMZAAN¹, Farina KHATTAK², Raheela AKHTAR¹

¹Department of Pathology, Faculty of Veterinary Sciences, University of Veterinary and Animal Sciences, Lahore, Pakistan

²Monogastric Science Research Centre, Scotland's Rural College, Ayr, UK

Received: 30.05.2015 • Accepted/Published Online: 25.11.2015 • Final Version: 27.06.2016

Abstract: This study was conducted to investigate the comparative efficacy of three different concentrations of acetic acid on broiler chickens experimentally challenged with *Salmonella enterica* serovar Pullorum (*S. Pullorum*). A total of 360 birds were divided into five groups (A-E). Group A served as the unchallenged, untreated control. All the birds in groups B-E were challenged with 4×10^4 cfu/mL of *S. Pullorum*. Birds in groups C, D, and E were respectively treated with three different concentrations, 0.5%, 1%, and 1.5%, of acetic acid. Pathological examination revealed congested and hemorrhagic liver, hepatitis and necrotic areas in the liver, hydropericardium, focal necrosis in the spleen, epithelial desquamation of the intestinal mucosa, and congested lungs and hazy appearance of air sacs in birds challenged with *S. Pullorum*. Acetic acid supplementation (1%) helped to reduce the number and severity of these gross and histopathological changes. Counts of *S. Pullorum* in cecal digesta were significantly reduced with increasing concentrations of acetic acid ($P < 0.05$). However, acetic acid supplementation at a higher rate (1.5%) also showed adverse effects in terms of higher percentage of diarrhea and bad growth performance in birds challenged with *S. Pullorum*. Among the three different concentrations, 1% acetic acid supplementation showed partially protective effects by showing better growth performance, lower feed conversion ratios ($P < 0.05$), and lower rates of gross and histopathological changes.

Key words: Acetic acid, growth performance, histopathology, *Salmonella* Pullorum

1. Introduction

Broiler chickens have a major share in the poultry production of Pakistan. Due to intensive farming, semivertical integration systems, and lack of adequate biosecurity measures, Pakistan is more susceptible to bacterial diseases (1). Pullorum disease (salmonellosis, caused by *Salmonella enterica* serovar Pullorum), is a worldwide problem of great economic importance mainly affecting countries with rapidly developing poultry industries. Salmonellosis is an acute systemic infection causing high mortality rate in young birds. Although adult birds are rarely affected by severe clinical disease, it can result in weight loss, diarrhea, and deformities of the reproductive tract, along with reduced egg production in layers (2,3). In the past, low doses of antibiotics (antibiotic growth promoters, AGPs) were used to control colonization of salmonella and other pathogens in broilers. However, a ban on use of in-feed AGPs due to threat of microbial resistance and the potential dangerous effects on human health has resulted in frequent outbreaks

of Pullorum disease (4). Now attention is being diverted to safe and potent alternatives like probiotics, prebiotics, and organic acids to control microbial populations in the gastrointestinal tract of poultry (5,6). Organic acids, including ethanoic acid, which is a weak organic acid, have been used in feed for having disinfecting effects (7). Very limited research is available regarding the effect of acetic acid on the health of birds and during infection. However, there are a few reports on the effect of organic acid (8,9). There are only a few studies regarding the effect of organic acid in *Salmonella*-challenged birds (10). Therefore, the present study was conducted with the aim of analyzing the ameliorating effects of acetic acid in broiler chickens experimentally challenged with *S. Pullorum*. A further objective of the study was to analyze the comparative efficacy of three different concentrations of acetic acid (0.5%, 1%, and 1.5%) against *S. Pullorum* infection. The results from the current study will give insight into how to control *S. Pullorum* under field conditions in Pakistan with acetic acid application.

* Correspondence: gulbeena.saleem@uvas.edu.pk

2. Materials and methods

2.1. Experimental birds and management

A total of 360 male Hubbard broiler chicks, 1 day old and free from *Salmonella*, were obtained from a commercial hatchery. Chicks were given ad libitum access to feed and water and 24 h of light was provided throughout the experimental period. The study was conducted in an environmentally controlled poultry house where temperature, ventilation, and other requirements were managed as per standard good husbandry practices. Birds were vaccinated against Newcastle disease and Gumboro according to the strict vaccination schedule practiced in commercial Pakistani operations.

2.2. Preparation of challenge inoculum

An isolate of *S. Pullorum* was obtained from the Quality Operations Laboratory, University of Veterinary and Animal Sciences, Lahore, Pakistan. Broth culture of *S. Pullorum* was prepared in Selenite F broth (Oxoid) incubated at 37 °C for 24 h. The concentration of *S. Pullorum* was confirmed by colony counts on Brilliant Green Agar (CM0263; Oxoid). The final culture contained 4×10^4 cfu/mL of viable *S. Pullorum*. All the birds in challenge treatment groups were gavaged at 3 days of age with 1 mL of broth containing 10^4 cfu of *S. Pullorum*, whereas the birds in the unchallenged treatment received sterile broth orally.

2.3. Diet and experimental design

A basal starter corn/soybean-based diet formulated to meet all the nutrient and energy requirements of broilers was manufactured at the local feed mill without antibiotics. In the case of diets with acetic acids (diets C, D, and E), known concentrations of acetic acid (Sigma Aldrich) were first dissolved in sterilized distilled water and then thoroughly mixed into the basal diet. For control groups, only sterilized distilled water was added to 2 kg of feed that was mixed with the required amount of basal feed.

The 1-day-old chicks were weighed and distributed into 30 pens containing equal numbers of chicks ($n = 12$) per pen. Six experimental pens were randomly allocated to each treatment. Treatments were as follows: Group A served as the unchallenged, untreated control. All the birds in groups B–E were challenged with 4×10^4 cfu/mL of *S. Pullorum* at 3 days of age. Birds in groups C, D, and E were respectively treated with three different concentrations, 0.5%, 1%, and 1.5%, of acetic acid in addition to the challenge. The negative control, Group A, received 1 mL of sterile normal saline directly into the crop.

2.4. Data collection

Following the experimental challenge, the birds were monitored daily for clinical signs and symptoms of Pullorum disease until birds were 21 days of age (when the trial was terminated).

2.5. Growth performance

At days 3, 7, 14, and 21 all the birds were weighed individually to calculate weight gain during the experimental periods of days 3–7, 7–14, and 14–21. Feed intakes were calculated by weighing the initial feed inputs against the uneaten food over the experimental period. Feed conversion ratio (FCR) was calculated for the periods of days 3–7, 7–14, and 14–21.

2.6. Postmortem examination

On days 7, 14, and 21 of age, six birds from each treatment group were randomly selected and humanely killed by an intravenous administration of overdose of barbiturates for postmortem examination. The spleen, liver, and heart were removed and weighed. The relative organ weight, which is weight of organ/100 g live body weight, was calculated for these organs to see the effect of *S. Pullorum* challenge.

2.7. Histopathological examination

Following postmortem examination on days 7, 14, and 21, samples from the liver, spleen, and intestines were collected and stored in 10% neutral phosphate-buffered formalin to be used to prepare histological slides according to method explained by Bancroft et al. (11). The prepared tissue sections were later examined using a binocular stereomicroscope (Olympus) connected by a camera to computer software using different modifications.

2.8. Quantification of *S. Pullorum* in cecal digesta

On days 7, 14, and 21 following postmortem examination, cecal contents were collected from 6 randomly selected birds into sterile screw-capped bottles and immediately transferred to the laboratory for quantification of *S. Pullorum*. Decimal dilutions were made and 0.1 mL was streaked on Brilliant Green Agar. Plates were incubated at 37 °C for 24 h. *Salmonella* colonies were counted to calculate the number of colony-forming units per gram of original sample.

2.9. Statistical analysis

The data obtained were analyzed statistically using a completely randomized design with the statistical package Statistix (copyright 1985–2005; Analytical Software, USA). Values were considered significant for $P < 0.05$. In the case of significant differences, Duncan's multiple range tests were used to compare differences among treatment means.

3. Results

The experiment was conducted mainly to investigate the effect of concentrations of acetic acid (0.5%, 1%, and 1.5%) on broiler chickens challenged with *S. Pullorum*.

Following the experimental challenge on day 3, birds were examined at least twice daily for any clinical abnormalities. Birds appeared dull and depressed subsequent to *S. Pullorum* challenge in the challenged treatment groups (groups B–E). Diarrhea was the most

prominent clinical sign, which was observed and compared among all five groups. On the basis of severity, diarrhea was scored as mild, intermediate, and severe (Figure 1).

Birds in group E (challenged and supplemented with 1.5% acetic acid) had a higher percentage of diarrhea as well as more severe form of diarrhea compared to birds in all other treatment groups. Birds of the control group remained healthy throughout the experiment and did not show any clinical signs, including diarrhea.

3.1. Growth performance

Overall results of the present experiment demonstrated the lowest weight gain in birds challenged with *S. Pullorum* (group B) compared to unchallenged birds and birds supplemented with 0.5% and 1% acetic acid. Following the experimental challenge, during days 3–7 and 7–14 feed intake was reduced ($P < 0.05$) in all challenged birds compared to birds in the unchallenged control group. However, during days 14–21, feed intake was not affected by challenge and/or acetic acid supplementation in any of treatment groups (Table 1).

The improvement in weight gain was also reflected in the lower FCR values for birds in unchallenged and all acetic acid-supplemented groups compared to those challenged with *S. Pullorum* (Table 1). *Salmonella*-challenged birds with acetic acid supplementation (groups C–E) showed better FCR ($P < 0.05$) compared to challenged birds without supplementation (group B).

3.2. Mortality

The mortality percentage was higher in broiler chickens challenged with *S. Pullorum* (15.3%) compared to all other treatment groups (Table 2). Among the acetic acid supplementation group, mortality was numerically lower in birds fed the diet with 1% acetic acid supplementation. In the unchallenged, untreated group (group A), only one bird was found dead on day 18.

3.3. Postmortem changes

Table 3 shows cumulative postmortem findings of all experimental groups on days 7, 14, and 21. The prominent gross postmortem findings in *S. Pullorum*-challenged birds (group B, Figures 2A–2C) were congested and

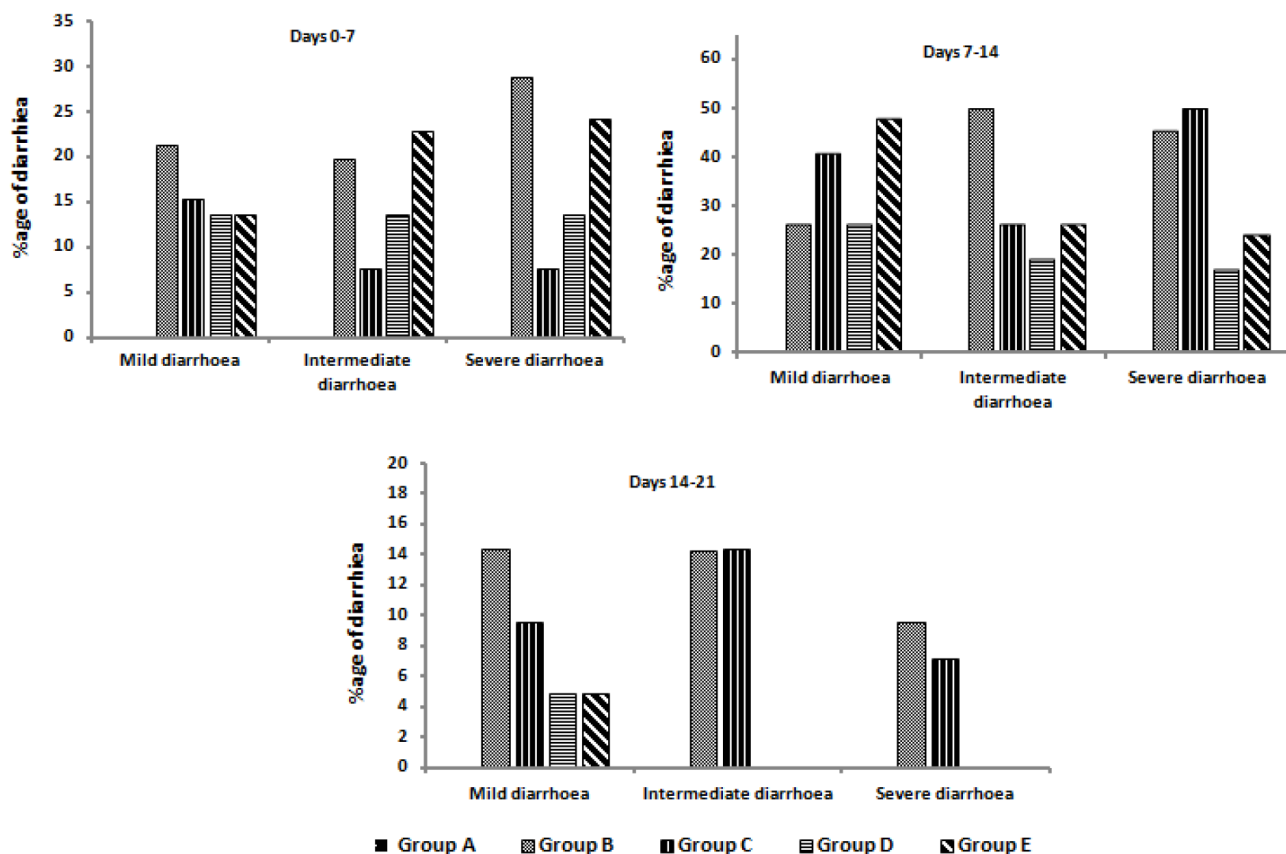


Figure 1. Diarrhea (percentage) of broiler chickens in different treatment groups fed on diets supplemented with acetic acid during days 3–7, 7–14, and 14–21 after challenge. Group A = unchallenged, untreated control; group B = challenged with *S. Pullorum*; group C = challenged + 0.5% acetic acid; group D= challenged + 1% acetic acid; group E= challenged + 1.5% acetic acid.

Table 1. Growth performance of broiler chickens in challenge and control treatment groups with supplementation of acetic acid.

Parameter	Days	Group A	Group B	Group C	Group D	Group E	SEM ¹	P-value
Weight gain (g/bird)	3-7	75 ^a	50 ^b	64 ^a	65 ^a	61 ^{ab}	7	0.031
	7-14	243 ^a	192 ^b	225 ^a	232 ^a	201 ^{ab}	7.60	0.042
	14-21	274 ^a	241 ^b	260 ^a	269 ^a	252 ^{ab}	12.58	0.024
Feed intake (g/bird)	3-7	278 ^a	200 ^b	225 ^b	231 ^b	218 ^{bc}	6.35	0.036
	7-14	370 ^a	298 ^b	351 ^b	361 ^{ab}	345 ^b	7.02	0.05
	14-21	300	251	287	325	305	16.68	0.715
Feed conversion ratio (FCR)	3-7	1.54 ^a	2.0 ^b	1.68 ^a	1.60 ^a	1.70 ^a	0.12	<0.001
	7-14	1.41	1.56	1.41	1.41	1.52	0.02	0.456
	14-21	1.27 ^a	1.68 ^b	1.45 ^a	1.37 ^a	1.53 ^a	0.07	<0.001

¹Standard error of means.

Means in a row with different superscripts (a-c) are significantly different ($P < 0.05$).

Group A = unchallenged, untreated control; group B = challenged with *S. Pullorum*; group C = challenged + 0.5% acetic acid; group D = challenged + 1% acetic acid; group E = challenged + 1.5% acetic acid.

Data are means of 6 pens with 12 birds per pen.

Table 2. Mortality rates of broiler chickens in different treatment groups fed on different experimental diets at days 0 (before the challenge) and 7, 14, and 21 (after the challenge).

Days	Group A	Group B	Group C	Group D	Group E
3-7	1	5	4	3	3
7-14	0	4	2	1	1
14-21	0	2	0	0	1
Total no.	1	11	5	4	5
Total %	1.39	15.3	7	6	7

Group A = unchallenged, untreated control; group B = challenged with *S. Pullorum*; group C = challenged + 0.5% acetic acid; group D = challenged + 1% acetic acid; group E = challenged + 1.5% acetic acid.

Groups each had 12 chicks challenged with *S. Pullorum* and fed different levels of acetic acid in diet. Challenge dose = 4×10^4 cfu/mL per bird of *S. Pullorum*.

hemorrhagic liver (100%). In most of the cases, the liver had a mottled appearance (Figure 2C). Spleens were congested and enlarged (88.8%). Other frequent findings were unabsorbed yolk (83.3%), hydropericardium (Figure 2B), and congested lungs and hazy appearance of air sacs (94.4%, Figure 2A).

Petechial hemorrhages were present on the serosal surface of intestines (83.3%). However, it was interesting to note that the all the parameters measured in the postmortem findings showed reduced signs of infection when birds were fed 1% acetic acid compared to all challenged groups. Lesions were more severe on day 7

and gradually decreased until day 21 (Table 3). No gross lesions were found in birds of the control group.

Percentage calculated from 1st to 3rd weeks after infection. Group A = unchallenged, untreated control; group B = challenged with *S. Pullorum*; group C = challenged + 0.5% acetic acid; group D = challenged + 1% acetic acid; group E = challenged + 1.5% acetic acid.

Relative weights of the spleen, liver, and heart of different treatment groups of broiler chickens during experimental days are presented in Table 4. Neither challenge nor acetic acid supplementation had any effect on relative weights of spleens, livers, and hearts.

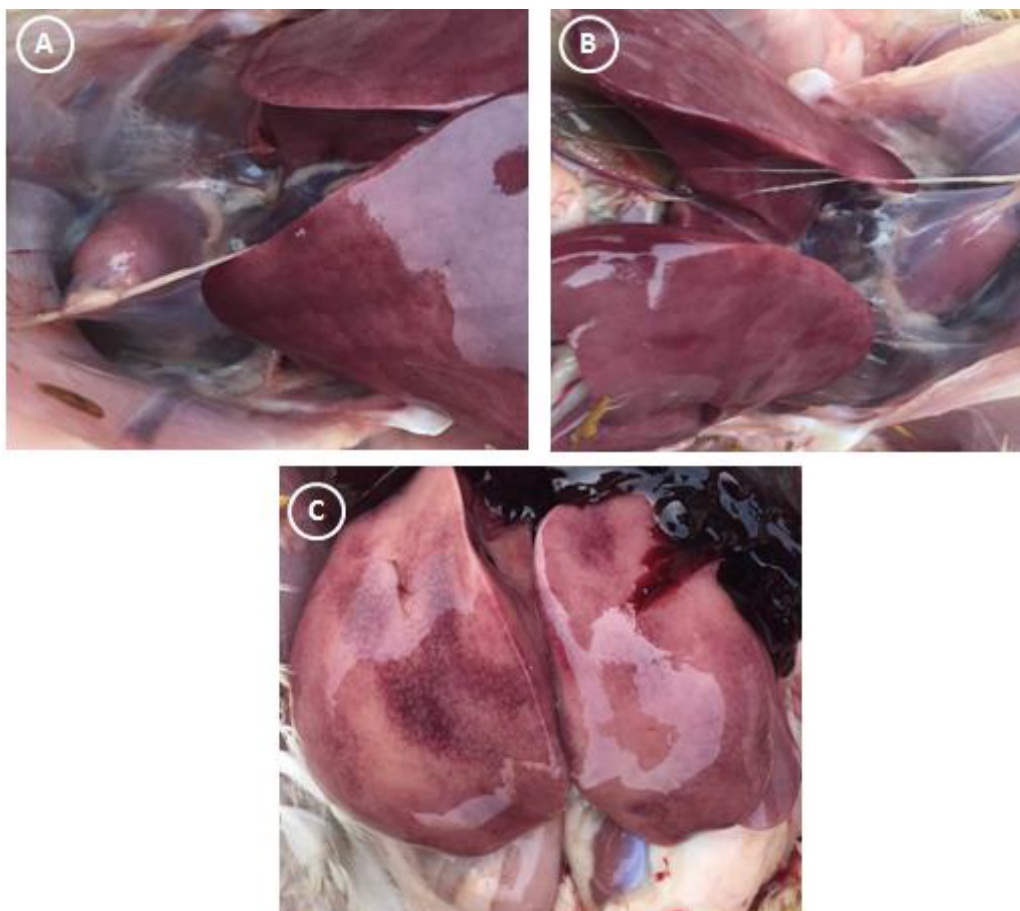


Figure 2. Postmortem changes in birds challenged with *S. Pullorum* (group B) on day 21. A) Air sacs of challenged birds showed cloudy appearance. B) Heart showing hydropericardium lesions. C) Pale and congested liver.

3.4. Histopathological changes

Histopathological examination revealed congestion, multifocal necrosis, and infiltration of inflammatory cells (mainly heterophils, lymphocytes, and macrophages) in perivascular areas of the livers of the *S. Pullorum* challenge treatment group (Figure 3A). In some areas hemorrhages were noted. Spleen sections from birds of group B revealed congestion along with scattered areas of necrosis (Figure 3B). In the challenged treatment group (group B), intestinal mucosa exhibited degenerated villi along with infiltration of inflammatory cells (Figure 3C). In all acetic acid-supplemented groups (C–E), decreases to a certain extent in inflammatory changes were observed in some of the birds compared to the *S. Pullorum* challenge group. Splens of some of the birds (3 out of 18) receiving 1% acetic acid supplementation (group D) showed only mild congestion and focal necrosis compared to challenged birds (16 out of 18).

3.5. Quantification of *S. Pullorum* from duodenal and cecal digesta

Digesta samples of birds challenged orally with *S. Pullorum* revealed higher bacterial load on different postchallenge days (6.21–8.79 CFU/g). Use of acetic acid significantly reduced ($P < 0.05$) colonization of *S. Pullorum* in the digesta of broilers fed acetic acid-supplemented diets compared to the control group (Table 5). Although *S. Pullorum* counts were lowest in the birds fed the highest level of acetic acid supplementation (1.5%), the counts were statistically similar to those of birds fed diets supplemented with 1% acetic acid throughout the experimental period (Table 5).

4. Discussion

This experiment was conducted to evaluate the effect of three different concentrations of acetic acid in broiler chickens orally challenged with *S. Pullorum*. Limited data are available on the effect of acetic acid on the health of broiler chickens, particularly during *S. Pullorum* infection.

Table 3. Cumulative postmortem findings of broiler chickens in different treatment groups fed on different experimental diets at days 7, 14, and 21 after challenge.

Lesion	Days	Group A	Group B	Group C	Group D	Group E
Congested and hemorrhagic liver	7	0/6	6/6	5/6	2/6	4/6
	14	0/6	6/6	6/6	2/6	4/6
	21	0/6	6/6	6/6	1/6	2/6
	Total %	0%	100%	94.4%	27.7%	55.5%
Pericarditis	7	0/6	6/6	5/6	2/6	2/6
	14	0/6	6/6	6/6	2/6	2/6
	21	0/6	4/6	4/6	1/6	1/6
	Total %	0	88.8	77.7	27.7	27.7
Congested lungs and hazy appearance of lungs' air sacs	7	0/6	6/6	5/6	1/6	2/6
	14	0/6	6/6	6/6	1/6	2/6
	21	0/6	5/6	5/6	1/6	1/6
	Total %	0	94.4	83.3	16.6	27.7
Congested spleen	7	0/6	6/6	4/6	1/6	3/6
	14	0/6	6/6	6/6	2/6	2/6
	21	0/6	4/6	4/6	0/6	2/6
	Total %	0	88.8	72.2	16.6	50
Unabsorbed yolk	7	0/6	6/6	6/6	5/6	4/6
	14	0/6	6/6	6/6	3/6	3/6
	21	0/6	3/6	3/6	0/6	2/6
	Total %	0	83.3	83.3	44.4	50

Percentage calculated from 1st to 3rd weeks after infection. Group A = unchallenged, untreated control; group B = challenged with *S. Pullorum*; group C = challenged + 0.5% acetic acid; group D = challenged + 1% acetic acid; group E = challenged + 1.5% acetic acid.

Table 4. Relative weights of spleens, livers, and hearts of broiler chickens of different treatment groups on days 7, 14, and 21 after infection.

Organ	Days	Group A	Group B	Group C	Group D	Group E	P-value
Spleen	7	0.08 ± 0.02	0.12 ± 0.02	0.09 ± 0.02	0.10 ± 0.03	0.09 ± 0.02	0.6892
	14	0.08 ± 0.01	0.10 ± 0.01	0.09 ± 0.00	0.10 ± 0.01	0.11 ± 0.01	0.1433
	21	0.08 ± 0.01	0.09 ± 0.02	0.08 ± 0.02	0.10 ± 0.03	0.10 ± 0.01	0.3368
Liver	7	3.88 ± 0.16	3.98 ± 0.23	3.90 ± 0.12	3.88 ± 0.33	3.87 ± 0.30	0.9982
	14	3.02 ± 0.15	3.03 ± 0.17	3.14 ± 0.16	3.19 ± 0.13	3.19 ± 0.18	0.7331
	21	2.94 ± 0.09	3.09 ± 0.14	3.07 ± 0.12	3.13 ± 0.17	3.14 ± 0.15	0.8713
Heart	7	0.88 ± 0.07	0.90 ± 0.08	0.89 ± 0.04	0.90 ± 0.04	0.89 ± 0.07	0.9999
	14	0.72 ± 0.04	0.73 ± 0.02	0.72 ± 0.08	0.74 ± 0.03	0.73 ± 0.04	0.9978
	21	0.66 ± 0.02	0.68 ± 0.03	0.67 ± 0.02	0.68 ± 0.02	0.69 ± 0.03	0.8792

Group A = unchallenged, untreated control; group B = challenged with *S. Pullorum*; group C = challenged + 0.5% acetic acid; group D = challenged + 1% acetic acid; group E = challenged + 1.5% acetic acid.

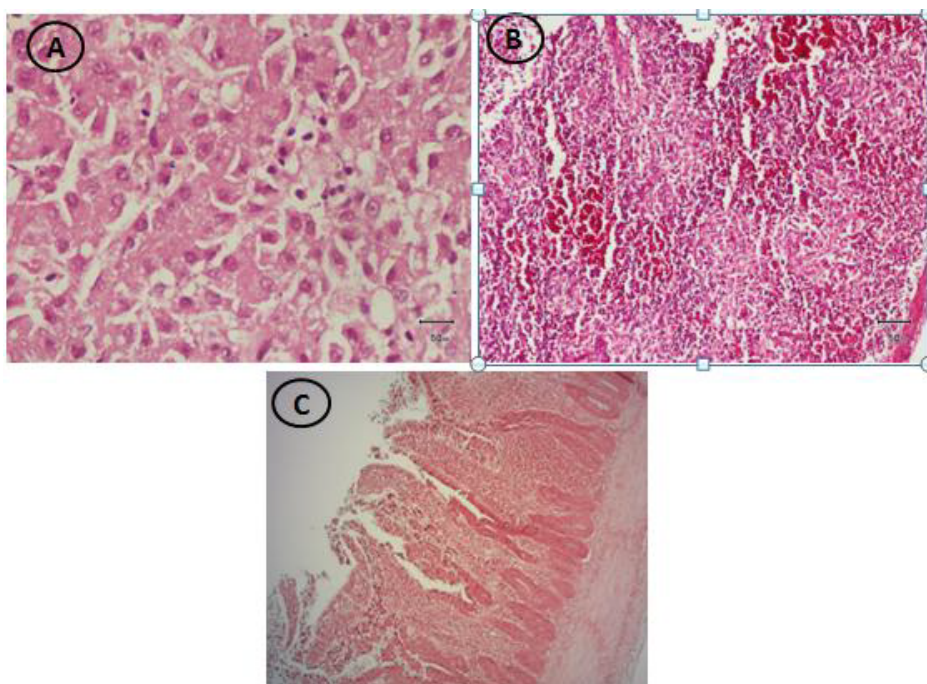


Figure 3. Photomicrography of birds experimentally challenged with *S. Pullorum* (group B) showing A) focal necrosis in liver, B) congestion in spleen, and C) degenerated villi of intestine.

Table 5. Quantification of *S. Pullorum* in cecal digesta of different treatment groups.

	Days	Group A	Group B	Group C	Group D	Group E	SEM ¹	P-value
<i>S. Pullorum</i> (log ¹⁰ cfu/g of digesta)	7	0.30 ^a	8.79 ^c	5.74 ^b	3.45 ^c	2.93 ^{ac}	0.51	0.001
	14	0.93 ^a	7.93 ^c	4.84 ^c	2.89 ^c	2.07 ^{ac}	0.64	0.001
	21	0.76 ^a	6.21 ^c	3.45 ^b	2.61 ^b	2.09 ^b	0.32	0.012

¹Standard error of means.

Means in a row with different superscripts (a–c) are significantly different (P < 0.05).

Group A = unchallenged, untreated control; group B = challenged with *S. Pullorum*; group C = challenged + 0.5% acetic acid; group D = challenged + 1% acetic acid; group E = challenged + 1.5% acetic acid.

However, there are a few reports on the antimicrobial effects of organic acids other than acetic acid (5,12). These reports have shown promising results in altering microbial populations in the gastrointestinal tract and performance of broiler chickens.

In the present study, most of the birds with *S. Pullorum* challenge had prominent symptoms of Pullorum disease. Following the experimental challenge, birds appeared dull and depressed and showed different degrees of diarrhea with vent pasting in all groups except the control. These results agree with Haider et al. (13), who observed 48% diarrhea and 52% vent pasting in their *Salmonella*-infected group. The diarrhea percentage was higher in the group challenged and supplemented with 1.5% acetic acid

compared to the other two challenge treatment groups with acetic acid supplementation (groups C and D).

4.1. Growth performance

In the present study, *S. Pullorum* challenge resulted in adverse effects on weight gain (P < 0.05) and FCR of broiler chickens. *Salmonella* infection causes significant deterioration in growth performance of poultry and consequently results in heavy economic loss (14,15).

In this trial, acetic acid supplementation improved the growth performance of birds to be similar to the unchallenged control compared to challenged birds. Among acetic acid-supplemented groups, the maximum weight gain was shown by the group supplemented with 1% acetic acid (Table 1). Improvement in weight gain of

birds from day 3 to day 21 due to supplementation with acetic acid was in line with the findings of Al-Kassi and Mohssen (12), who also showed higher weight gain with organic acid supplementation.

As a result of reduced weight gain, FCR was increased in broiler chickens challenged with *S. Pullorum* compared to birds in the unchallenged and acetic acid supplementation groups. Acetic acid supplementations (groups C–E) resulted in better FCR ($P < 0.05$) compared to challenged birds without supplementation (group B). Improvement in FCR due to supplementation with acetic acid is in line with the previous findings of Al-Tarazi and Alshawabkeh (10). Improvement in growth performance may be due to the fact that organic acids improve the digestibility of proteins and minerals (16,17).

4.2. Mortality

Mortality percentage was between 6% and 15% throughout the experiment in challenged treatment groups (groups B–E), indicating successful induction of clinical disease. Data regarding effects of *Salmonella* on chicken mortality are inconsistent. Higher mortality in birds challenged with *S. Pullorum* compared to untreated control birds observed in the current study contradicts the study of Bohez et al. (18), who observed a low mortality rate (0.7%) even when chicks were challenged with high doses (10^8 cfu) of *S. Enteritidis*. In another study, Wang et al. (19) did not notice any mortality in broiler birds infected with 4×10^4 cfu of *S. Pullorum*. A mortality rate of up to 8% was reported by Haider et al. (20) following infection with *S. Pullorum* at higher doses (10^7 cfu/mL). Chickens being challenged with *S. Gallinarum* (10^8 CFU) resulted in mortality of 31% (21). Another study demonstrated that chickens inoculated orally with *S. Pullorum* at 4 days of age showed 50% mortality (22). These differences may be due chick age at challenge, strain of bacterial organism or serotype challenge, challenge dosage, and environmental conditions (23,24).

In the present study, acetic acid supplementation resulted in a decreased mortality rate (6%–7%) compared to the untreated challenged control (15.3%). These results are in line with Al-Tarazi and Alshawabkeh (10), who found that feeding treatment with organic acid reduced mortality from 58.3% in untreated birds to 8.3% in treated ones.

4.3. Postmortem changes

The prominent postmortem changes seen in *S. Pullorum*-challenged birds (group B) were congested and hemorrhagic liver. In some birds white foci were also observed in the liver. The spleen showed splenomegaly and congestion. Other frequent findings were unabsorbed yolk, hydropericardium, congested lungs, and hazy appearance of air sacs. Percentages of different cumulative postmortem findings are shown in Table 3. The results are

in agreement with an experiment (20) in which the gross pathological changes observed in livers were hemorrhages (54%) and necrotic foci (38%). Spleens showed congestion and enlargement (42%) in *S. Pullorum*-infected birds. Liver and intestinal lesions were reported by Hossain et al. (25). Liver congestion following *S. Pullorum* challenge corresponded with the findings of another experiment (26). Intensity of gross lesions reduced gradually at 21 days of age (Table 3). Birds with acetic acid supplementation (in particular 1%) showed less severe and reduced rate of lesions. Congestion and hemorrhagic liver in *S. Pullorum*-challenged birds were reduced from 100% to 27.7% in birds with 1% acetic acid supplementation. Overall, acetic acid supplementation (1%) reduced the percentage of pathological changes in different organs, indicating a lower morbidity rate due to supplementation of acetic acid (Table 3).

4.4. Histopathology

Prominent lesions in *S. Pullorum*-challenged birds (group B) were hepatitis, congestion, and infiltration of inflammatory cells with focal necrosis in the liver (100%), focal necrosis and congestion in the spleen (88%), and degenerated intestinal villi along with infiltration of inflammatory cells (94%) (Figures 3A–3C). Similar microscopic lesions were reported by Haider et al. (20) in the birds experimentally challenged with *S. Pullorum*. Sections of liver tissue from birds with 1% acetic acid supplementation revealed fewer necrotic areas with infiltration of few inflammatory cells (33%) compared to birds challenged with *S. Pullorum* (100%). Similarly, spleen sections revealed fewer areas of congestion and necrosis in group D (16%) compared to group B (88%).

4.5. Quantification of *Salmonella* from cecal digesta

Quantification of *S. Pullorum* was done in cecal digesta as *Salmonella* infection is the highest and persistent in the cecum compared to other parts of the digestive tract (27). Therefore, its colonization is mainly used as a parameter for evaluation of treatment efficacy against *Salmonella* (27,28). In this study, *S. Pullorum* challenge resulted in higher colonization of *S. Pullorum* in cecal digesta. These results are in agreement with the results of Al-Tarazi and Alshawabkeh (10) and Borsoi et al. (29), in which *Salmonella* challenge caused higher *Salmonella* colonization in cecal digesta.

Supplementation of acetic acid in the diet reduced the frequency of *S. Pullorum* isolation ($P < 0.05$) on all sampling days (7, 14, and 21), suggesting that use of acetic acid can regulate the cecal microflora of birds after *S. Pullorum* infection. Significant reduction in the numbers of *Salmonella* with increasing concentrations of acetic acid (Table 5) was in line with previous findings (10,30) using organic acids (formic acid, propionic acid, and short-chain fatty acids) that showed the same results. Similar to the

current study, earlier researchers (8) also demonstrated significant reduction in colonization of *S. Gallinarum* in the crop and cecum with increasing concentration of organic acid (propionic acid) from 1.2% to 1.8%. The antibacterial effect of organic acid is thought to be related to the reduction of pH and the ability to dissociate in the intestine. As organic acids are weak acids and lipid-soluble, they therefore easily enter the cell wall and affect microbial metabolism, resulting in the death of bacteria (31,32). In market-age broiler chickens the use of acids has been shown to reduce pH of the crop and hence reduce recovery of *Salmonella* from the crop (33).

4.6. Conclusions

The results of the present study have demonstrated the adverse effects of *Salmonella* infection on growth parameters, various organs, and histopathology in broiler

chickens. From the present study it can be concluded that among the three different concentrations of acetic acid used, 1% acetic acid showed better results in terms of better growth performance, lower mortality rate, fewer pathological changes, and reduced colonization of *S. Pullorum* in broiler chickens experimentally challenged with *S. Pullorum*, confirming results of an earlier study that showed that antibacterial activity of organic acid is concentration-dependent (10). However, further studies are needed to determine the maximum safe level of acetic acid supplementation in other diseases such as coccidiosis in the antibiotic-free era.

Acknowledgment

The authors would like to thank the Higher Education Commission of Pakistan for financial support.

References

1. Subtain SM, ZI Chaudhry, Anjum AA, Maqbool A, Sadique U. Study on pathogenesis of low pathogenic avian influenza virus H9 in broiler chickens. *Pak J Zool* 2011; 43: 999–1008.
2. Chappell L, Kaiser P, Barrow P, Jones MA, Johnston C, Wigley P. The immunobiology of avian systemic salmonellosis. *Vet Immunol Immunop* 2009; 128: 53–59.
3. Wigley P, Berchieri A Jr, Page K, Smith AL, Barrow PA. *Salmonella enterica* serovar Pullorum persists in splenic macrophages and in the reproductive tract during persistent disease-free carriage in chickens. *Infect Immun* 2001; 69: 7873–7879.
4. Williams P, Losa R. The use of essential oils and their compounds in poultry nutrition. *World Poultry* 2001; 17: 14–15.
5. Van Immerseel F, Cauwerts K, Devriese LA, Haesebrouck F, Ducatelle R. Feed additives to control *Salmonella* in poultry. *World Poultry Sci J* 2002; 58: 431–443.
6. Jeong JS, Kim IH. Effect of *Bacillus subtilis* C-3102 spores as a probiotic feed supplement on growth performance, noxious gas emission, and intestinal microflora in broilers. *Poultry Sci* 2014; 93: 3097–3103.
7. Iba AM, Berchieri A Jr. Studies on the use of formic acid-propionic acid mixture (Bio-Add™) to control experimental *Salmonella* infection in broiler chickens. *Avian Pathol* 1995; 24: 304–311.
8. Alshawabkeh K, Tabbaa JM. Using dietary propionic acid to limit *Salmonella Gallinarum* colonization in broiler chicks. *Asian-Aust J Anim Sci* 2002; 15: 243–246.
9. Van Immerseel F, De Buck J, Boyen F, Bohez L, Pasmans F, Volf Rychlik I, Haesebrouck F, Ducatelle R. Medium chain fatty acid decreases colonization and invasion through *hilA* suppression shortly after infection of chickens with *Salmonella enterica* serovar Enteritidis. *Appl Environ Microbiol* 2004; 70: 3582–3587.
10. Al-Tarazi YH, Alshawabkeh K. Effect of dietary formic and propionic acids on *Salmonella Pullorum* shedding and mortality in layer chicks after experimental infection. *J Vet Med* 2003; 50: 112–117.
11. Bancroft JD, Stevens A, Turner DR. *Theory and Practice of Histological Technique*. 4th ed. London, UK: Churchill Livingstone; 1996.
12. Al-Kassi AG, Mohssen MA. Comparative study between single organic acid effect and synergistic organic acid effect on broiler performance. *Pakistan Journal of Nutrition* 2009; 8: 896–899.
13. Haider MG, Chowdhury EHK, Hossain A, Rahman MT, Song MS, Hossain MM. Experimental pathogenesis of pullorum disease in chicks by local isolate of *Salmonella enterica* serovar. Enteric subspecies *Pullorum* in pullets in Bangladesh. *Korean Journal of Poultry Science* 2009; 35: 341–350.
14. Vandeplass S, Dauphin RD, Thiry C, Beckers Y, Welling GW, Thonart P, Théwis A. Efficiency of a *Lactobacillus plantarum*-xylanase combination on growth performances, microflora populations, and nutrient digestibilities of broilers infected with *Salmonella Typhimurium*. *Poultry Sci* 2009; 88: 1643–1654.
15. Marcq C, Cox E, Szalo IM, Théwis A, Beckers Y. *Salmonella Typhimurium* oral challenge model in mature broilers: bacteriological, immunological, and growth performance aspects. *Poultry Sci* 2011; 90: 59–67.
16. Mroz, Z, Jongbloed AW, Partanen KH, Vermin K, Kemme PA, Kogut J. The effects of calcium benzoate in diets with or without organic acids on dietary buffering capacity, apparent digestibility, retention of nutrients and manure characteristics in swine. *J Anim Sci* 2000; 78: 2622–2632.
17. Omogbenigun FO, Nyachti CM, Soliminski BA. The effect of supplementing microbial phytase and organic acids to corn-soybean based diet fed to early weaned pigs. *J Anim Sci* 2003; 81: 1806–1813.

18. Bohez L, Gantois I, Ducatelle R, Pasmans F, Dewulf J, Haesebrouck F, Van Immerseel F. The *Salmonella* Pathogenicity Island 2 regulator *ssrA* promotes reproductive tract but not intestinal colonization in chickens. *Vet Microbiol* 2008; 126: 216–224.
19. Wang LC, Zhang TT, Wen C, Jiang ZY, Wang T, Zhou YM. Protective effects of zinc-bearing clinoptilolite on broilers challenged with *Salmonella* Pullorum. *Poultry Sci* 2008; 91: 1838–1845.
20. Haider MG, Chowdhury AKM, Hossain MM. Experimental pathogenesis of pullorum disease in chicks by local isolate of *Salmonella* Pullorum in Bangladesh. *Journal of the Bangladesh Agricultural University* 2008; 10: 87–94.
21. Berchieri JR, Barrow PA. Reduction in incidence of experimental fowl typhoid by incorporation of a commercial formic acid preparation (Bio-Add™) into poultry feed. *Poultry Sci* 1996; 75: 339–341.
22. Carina Audisio M, Oliver G, Apella MC. Protective effect of *Enterococcus faecium* J96, a potential probiotic strain, on chicken infected with *Salmonella* Pullorum. *J Food Prot* 2000; 63: 1333–1337.
23. Totton CS, Farrar MA, Wilkins W, Bucher O, Waddell AL, Wilhelm JB, McEwen AS, Rajic A. A systematic review and meta-analysis of the effectiveness of biosecurity and vaccination in reducing *Salmonella* spp. in broiler chickens. *Food Res Int* 2011; 45: 617–627.
24. Soleimani FA, Zulkifli I, Hair-Bejo M, Omar RA, Raha RA. The role of heat shock protein 70 in resistance to *Salmonella enteritidis* in broiler chickens subjected to neonatal feed restriction and thermal stress. *Poultry Sci* 2011; 91: 340–345.
25. Hossain M, Chowdhury E, Islam M, Haider M Hossain, M. Avian *Salmonella* infection: isolation and identification of organisms and histopathological study. *Bangladesh Journal of Veterinary Medicine* 2011; 4: 7–12.
26. Pinheiro LA, De Oliveira GH, Berchieri A Jr. Experimental *Salmonella enterica* serovar Pullorum infection in two commercial varieties of laying hens. *Avian Pathol* 2001; 30: 129–133.
27. Filho-Lima J, Vieira E, Nicoli J. Antagonistic effect of *Lactobacillus acidophilus*, *Saccharomyces boulardii* and *Escherichia coli* combinations against experimental infections with *Shigella flexneri* and *Salmonella enteritidis* subsp. *typhimurium* in gnotobiotic mice. *J Appl Microbiol* 2000; 88: 365–370.
28. Hargis B, Caldwell D, Brewer R, Corrier D, Deloach J. Evaluation of the chicken crop as a source of *Salmonella* contamination for broiler carcasses. *Poultry Sci* 1995; 74: 1548–1552.
29. Borsoi A, Santos LRD, Diniz GC, Salle C, Moraes H, Nascimento VP. *Salmonella* fecal excretion control in broiler chickens by organic acids and essential oils blend feed added. *Revista Brasileira de Ciência Avícola* 2011; 13: 65–69.
30. McHan F, Shots B. Effect of short chain fatty acids on the growth of *Salmonella typhimurium* in an in vitro system. *Avian Dis* 1993; 37: 396–398.
31. Schulz I, Ströver F, Ullrich KJ. Lipid soluble weak organic acid buffers as “substrate” for pancreatic secretion. *Pflügers Arch* 1971; 323: 121–140.
32. Russell JB, Diez-Gonzalez F. The effects of fermentation acids on bacterial growth. *Adv Microb Physiol* 1998; 39: 205–234.
33. Byrd JA, Hargis BM, Caldwell DJ, Bailey RH, Herron KL, McReynolds JL, Brewer RL, Anderson RC, Bischoff KM, Callaway TR et al. Effect of lactic acid administration in the drinking water during pre-slaughter feed withdrawal on *Salmonella* and *Campylobacter* contamination of broilers. *Poultry Sci* 2001; 80: 278–283.