

## First clinical *Strongyloides stercoralis* case in a dog in Turkey\*

Şinasi UMUR<sup>1\*\*</sup>, Yücel MERAL<sup>2</sup>, Cenk Soner BÖLÜKBAŞ<sup>1</sup>, Ali Tümay GÜRLER<sup>1</sup>, Mustafa AÇICI<sup>1</sup>  
<sup>1</sup>Department of Parasitology, Faculty of Veterinary Medicine, Ondokuz Mayıs University, Samsun, Turkey  
<sup>2</sup>Department of Internal Diseases, Faculty of Veterinary Medicine, Ondokuz Mayıs University, Samsun, Turkey

Received: 01.06.2016 • Accepted/Published Online: 02.12.2016 • Final Version: 19.04.2017

**Abstract:** A 2.5-year-old small male Cavalier King Charles spaniel was brought to Ondokuz Mayıs University's Faculty of Veterinary Medicine Animal Hospital with symptoms of severe watery diarrhea, pain during defecation, intermittent cough, vomiting, and emaciation. Examination of the fecal smear revealed moderate infection of *Strongyloides stercoralis* larvae and two adult females. Counting of the larvae in feces was performed by Baermann method and 20 larvae were determined per gram of feces. The dog was treated with ivermectin (Avromec, 0.2 mg/kg subcutaneously) and multivitamin syrup (Vitabiol) for 5 days for supporting the body condition. This paper is the first clinical case report of *S. stercoralis* in a dog in Turkey.

**Key words:** Dog, ivermectin, *Strongyloides stercoralis*, treatment, Turkey

### 1. Introduction

Canine strongyloidiasis is a zoonotic infection caused by the intestinal nematode *Strongyloides stercoralis* (1). The parasite is found generally in dogs and cats and also in humans worldwide, especially in tropical regions (2,3).

*S. stercoralis* is an interesting nematode in several ways: only female nematodes are parasitic and it can multiply parthenogenetically in the host, and it has two life cycles, a free-living period and a parasitic period (3,4).

Parasite morphology varies between the free-living and parasitic periods of the life cycle. The parasitic female is small and slender, nearly 2 mm in length. The tip of the tail is bluntly shaped and the esophagus is elongated and filariform, nearly filling the anterior half of the body length (4,5).

Development of the larva is rapid under ideal conditions; the infective larval stage may be reached in about 2 days. Based on environmental conditions, some of the larvae develop into the parasitic form while others develop into free-living worms. The infective larvae (L<sub>3</sub>) are transmitted via oral and percutaneous routes and also the transmammary pathway, but there is no placental infection in dogs (4,6,7).

Infection usually occurs in shelters, where most puppies are affected, especially since a large number of dogs are hosted in small units, and in humid and hot seasons, sometimes due to poor hygienic conditions (7).

The clinical signs of strongyloidiasis vary depending on the severity of infection and the age and immune status of the animal (1,3).

Diagnosis of *S. stercoralis* infection is difficult due to its complex life cycle and the irregularly excreted larvae may be small in number or absent from the feces, even in cases of clinical disease (3). There are many diagnostic methods used to detect *S. stercoralis* including direct smear examination, the Baermann method, coproculture, intestinal biopsy, or aspirate and also some serological and molecular techniques such as enzyme-linked immunosorbent assay (ELISA) and polymerase chain reaction (PCR) (1,5,7–9). However, each technique has some problems with sensitivity, specificity, cost, or applicability, so there is no gold standard for diagnosing *S. stercoralis* (8).

Direct smear, fecal flotation with zinc sulfate, and the Baermann method are cheap, simple, and easily applicable methods in all parasitology laboratories. However, they have low sensitivity and a single examination can fail to detect larvae in all cases, so they need repeated tests or collections of samples on different days (10).

There are many drugs of choice for the treatment of adult *S. stercoralis* in dogs. For this purpose, ivermectin (0.2 mg/kg, subcutaneously or per os (PO), with a second

\* This paper was presented at the 14th International Symposium on Prospects for the 3rd Millennium Agriculture at the University of Agricultural Sciences and Veterinary Medicine, Cluj-Napoca, Romania, 24–26 September 2015.

\*\* Correspondence: sumur@omu.edu.tr

dose 4 weeks later; once, 0.8 mg/kg, PO), fenbendazole (once a day for 3–5 days at 50 mg/kg, repeated 4 weeks later), albendazole (twice daily for 3 consecutive days at 100 mg/kg) (11,12), and selamectin (once a day at 6 mg/kg) are used.

*S. stercoralis* has a cosmopolitan distribution in tropical and subtropical regions but may also be found in temperate zones in humans in the world, whereas it is sporadic in humans and rarely seen in dogs in Turkey (13).

In Turkey, there is only one old study available about the presence and prevalence of *Strongyloides* sp. in dogs and cats in which the prevalence of the parasite was recorded as 0.54% and 0.58%, respectively. There is no clinical case report in dogs and cats in Turkey (14,15).

The present study describe a clinical strongyloidiasis case for the first time in Turkey and successful treatment of *S. stercoralis* infection in a dog with ivermectin administered subcutaneously.

## 2. Case history

A 2.5-year-old small male Cavalier King Charles spaniel weighting 3.8 kg was presented to Ondokuz Mayıs University's Faculty of Veterinary Medicine Animal Hospital with symptoms including severe watery diarrhea, pain at defecation, intermittent cough, vomiting, and emaciation.

Fresh fecal samples were collected from the infected dog on days 1, 3, 7, and 14 for parasitological examination by direct fecal smears and the Baermann method (2,10). Larvae count was performed per gram of feces with the Baermann method and then 10 larvae were examined. Characteristics used in morphological identification of the parasite were measured and larvae were photographed.

The larvae and young female nematodes were examined with a microscope (Nikon Eclipse 80i, Tokyo, Japan) connected to a digital camera and specific software used for measurements (Nikon DS-L1), and they were identified using morphological keys (1,3,5,10).

After confirmation, the dog was treated with ivermectin (0.2 mg/kg subcutaneously) and multivitamin syrup (Vitabiol) for 5 days.

## 3. Results and discussion

Examination of the fecal smear revealed a moderate amount of *S. stercoralis* larvae and two adult females. Larval count was performed in feces with the Baermann method and 20 larvae were determined per gram of feces.

There is no gold-standard method for diagnosis of *S. stercoralis* (1,7–9). In our study direct fecal smears and the Baermann method were preferred because they are cheap, easy, and less time-consuming. However, these methods require a considerably larger quantity of stools, which

might lead to compliance problems if an additional sample is required due to insufficient volume.

The first-stage larvae were easily identified as the genital primordium was clearly seen, which is the factor that allows *S. stercoralis* to be easily differentiated from other nematode larvae in dogs or free-living nematodes (3,5).

In this study, the first-stage ( $L_1$ ) larvae (n: 10) typically had a rhabditiform esophagus. They were 317.69 (239.20–366.62)  $\mu\text{m}$  long and 18.81 (17.02–20.18)  $\mu\text{m}$  wide at the end of the esophagus level, and 18.87 (16.96–20.62)  $\mu\text{m}$  wide at the middle level of the genital primordium. The length of the esophagus was 90.35 (88.10–93.70)  $\mu\text{m}$ , while that of the procorpus was 44.21 (42.13–46.25)  $\mu\text{m}$ , isthmus was 15.44 (11.67–19.46)  $\mu\text{m}$ , metacorpus was 23.96 (23.74–24.03)  $\mu\text{m}$ , and genital primordium was 29.73 (25.39–32.64)  $\mu\text{m}$  (Figure 1A).

The young females (n: 2) were 1.320 (1.215–1.425) mm long and 34–36  $\mu\text{m}$  wide with a very long cylindrical esophagus that occupied nearly the anterior half of the body (Figure 1B). The vulva was located posteriorly. The tail was short, narrow, and sharply tapered (Figure 1C).

The morphological characters of the female parasites were also compatible with the findings of published studies (1,2,5,10).

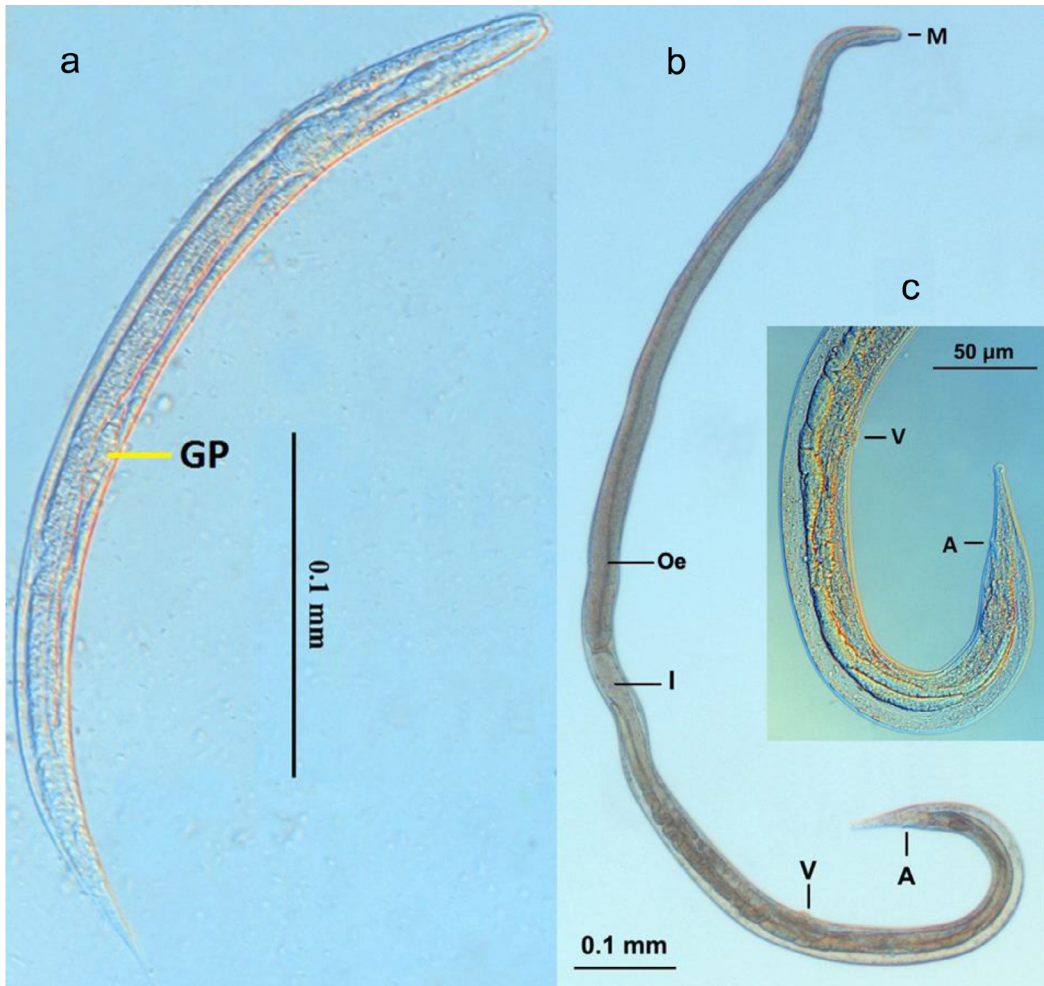
Infections in dogs can be treated with ivermectin, fenbendazole, albendazole, and thiabendazole (12,13). In our study the dog was treated with ivermectin (Avromec, 0.2 mg/kg subcutaneously) and multivitamin syrup (Vitabiol) for 5 days.

There were no larvae in fecal examinations of the samples that were taken after the third day of ivermectin treatment. This result showed that ivermectin was effective against all larval stages and adults in the small intestines.

Yang et al. (12) reported that ivermectin was 100% effective against  $L_1$ ,  $L_2$ , and adults of *S. stercoralis* in dogs but it was not effective against tissue-dwelling  $L_3$ . Fenbendazole and others were used for treatment, as well (11).

There is no efficient drug against autoinfective migratory larvae so treatment of actively hyperinfected dogs may be difficult (3). Fecal examination in all treated animals should be done weekly for 2 to 3 weeks to detect larvae. Ideally, prevention, by improved sanitation (suitable disposal of feces), practicing of good hygiene (wearing gloves and washing hands), etc., is used before any drug regimen is administered.

It has been suggested that cases of diarrhea should be considered for *S. stercoralis*, especially for young puppies, and at least the direct stool smears method should be applied for the larvae. The result of the present case suggests that ivermectin is suitable for treatment of dogs naturally infected with *S. stercoralis*.



**Figure 1.** Microscopic appearance of *Strongyloides stercoralis*: a) first-stage larva; b) young female; c) posterior end of the young female. A: Anus, GP: genital primordium; I: intestine; M: mouth; Oe: esophagus, V: vulva.

However, this treatment regimen is not approved for all animals and feces should be examined regularly for at least 6 months after treatment to confirm efficacy.

Some helminths such as *S. stercoralis* can also be transmitted to humans, including animal owners, as well as to veterinary practitioners and veterinary nurses. Therefore, the possibility of *S. stercoralis* transmission to humans cannot be eliminated.

In conclusion, there is no reported study about the prevalence and/or pathogenicity of *S. stercoralis* in dogs

in Turkey. The present case shows that *S. stercoralis* can cause disease in mature dogs and infection may become a chronic problem in appropriate environments. Infection could be diagnosed by direct smears and/or the Baermann technique, but they are not routinely performed in small animal practice in Turkey. A single subcutaneous dose of ivermectin (0.05 mL, 1% w/v) was found to be effective in the current case with subsiding of symptoms and larval disappearance upon fecal examination.

## References

1. Junior AF, Gonçalves-Pires MRF, Silva DAO, Gonçalves ALR, Costa-Cruz JM. Parasitological and serological diagnosis of *Strongyloides stercoralis* in domesticated dogs from southeastern Brazil. *Vet Parasitol* 2006; 136: 137-145.
2. Dillard KJ, Saari SAM, Anttila M. *Strongyloides stercoralis* infection in a Finnish kennel. *Acta Vet Scand* 2007; 49: 37.
3. Nolan TJ. Canine strongyloidiasis. In: Bowman DD, editor. *Companion and Exotic Animal Parasitology*. Ithaca, NY, USA: International Veterinary Information Service; 2001. Available online at [http://www.ivi.org/signin.asp?url=/advances/Parasit\\_Bowman/nolan\\_strongyloidiasis/chapter\\_frm.asp?LA=1](http://www.ivi.org/signin.asp?url=/advances/Parasit_Bowman/nolan_strongyloidiasis/chapter_frm.asp?LA=1).

4. Viney ME, Lok JB. *Strongyloides* spp. In: WormBook; 2007. Available online at [http://www.wormbook.org/chapters/www\\_genomesStrongyloides/genomesStrongyloides.html](http://www.wormbook.org/chapters/www_genomesStrongyloides/genomesStrongyloides.html).
5. Speare R. Identification of species of *Strongyloides*. In: Grove DI, editor. Strongyloidiasis: A Major Roundworm Infection of Man. London, UK: Taylor and Francis; 1989. pp. 11-84.
6. Shoop WL, Michael BE, Eary CH, Haines HW. Transmammary transmission of *Strongyloides stercoralis* in dogs. J Parasitol 2002; 88: 536-539.
7. Gonçalves ALR, Machado GA, Gonçalves-Pires MRF, Ferreira-Junior A, Silva DAO, Costa-Cruz JM. Evaluation of strongyloidiasis in kennel dogs and keepers by parasitological and serological assays. Vet Parasitol 2007; 147: 132-139.
8. Montes M, Sawhney C, Barros N. *Strongyloides stercoralis*: there but not seen. Curr Opin Infect Dis 2010; 23: 500-504.
9. Repetto SA, Alba Soto CD, Cazorla SI, Tayeldin ML, Cuello S, Lasala MB, Tekiel VS, González Cappa SM. An improved DNA isolation technique for PCR detection of *Strongyloides stercoralis* in stool samples. Acta Trop 2013; 126: 110-114.
10. Requena-Mendez A, Chiodini P, Bisoffi Z, Buonfrate D, Gotuzzo E, Munoz J. The laboratory diagnosis and follow up of strongyloidiasis: a systematic review. PLoS Negl Trop Dis 2013; 7: e2002.
11. Itoh N, Kanai K, Hori Y, Nakao R, Hoshi F, Higuchi S. Fenbendazole treatment of dogs with naturally acquired *Strongyloides stercoralis* infection. Vet Rec 2009; 164: 559-560.
12. Yang M, Gebeyehu EB, Jung SJ, Kwon OD, Kwak D. Treatment of naturally acquired *Strongyloides stercoralis* infection in a dog with ivermectin. J Anim Plant Sci 2013; 23: 337-339.
13. Ardıç N. An overview of *Strongyloides stercoralis* and its infections. Mikrobiyol Bul 2009; 43: 169-177 (in Turkish with English abstract).
14. Doğanay A. Check list of the parasites of cats and dogs in Turkey. Ankara Univ Vet Fak 1992; 39: 336-348 (in Turkish with English abstract).
15. Umur Ş, Töz SÖ. Strongyloidiasis. In: Doğanay M, Altıntaş N, editors. Zoonozlar (Hayvanlardan İnsanlara Bulaşan Enfeksiyonlar). Ankara, Turkey: Bilimsel Tıp Yayınevi; 2009. pp. 1065-1072 (in Turkish).