

Complications of ultrasound-guided cystocentesis in companion animals: 21 cases (2005–2016)

Sabrina MANFREDI^{1*}, Cibele CARVAHLO², Paolo FONTI³, Giacomo GNUDI¹, Francesca MIDURI¹,
Martina FABBI¹, Eleonora DAGA¹, Manuela RAVERA¹, Simona MORABITO⁴, Edoardo AURIEMMA⁴,
Ilaria PARROCCINI⁵, Mattia BONAZZI⁵, Antonella VOLTA¹

¹Department of Veterinary Medical Science, University of Parma, Parma, Italy

²Nucleus of Improvement in Veterinary Ultrasonography (NAUS), Sao Paulo, Brazil

³Specialized Veterinary Center, Rome, Italy

⁴Veterinary Institute of Novara, Granozzo con Monticello, Italy

⁵San Geminiano Veterinary Clinic, Modena, Italy

Received: 03.02.2018 • Accepted/Published Online: 18.05.2018 • Final Version: 12.10.2018

Abstract: Complications of cystocentesis in dogs and cats are seldom reported. The aim of this study was to describe clinical and ultrasonographic features of complications after diagnostic cystocentesis. Medical records of animals that underwent ultrasound-guided diagnostic cystocentesis (UGDC) were retrospectively reviewed to describe adverse events. The inclusion criteria were: ultrasound report describing the complication, signalment, clinical history, urine culture, and surgical exploration or necroscopic findings if present. Images of ultrasonographic examination were reviewed. Complications were classified as minor and major. Minor complications were defined as self-limited events; major complications were those that led to prolonged hospitalization and required intensive therapy or surgery, or lead to death. Twenty-one cases met the inclusion criteria (20 animals). Major complications included septic peritonitis (n = 2), big vessel laceration (n = 2), and acute abdomen (n = 1). Death occurred in two cases (septic peritonitis). Minor complications included nodular fat necrosis (n = 1), abdominal wall abscess formation (n = 1), intraluminal blood clots (n = 2), self-limited bleeding (n = 5), wall bladder hematoma (n = 3), bladder mucosal detachment (n = 1), intraparietal gas bubbles (n = 2), and focal peritonitis adjacent to bladder (n = 1). Findings of this study can be useful to promptly identify complications after UGDC and to ensure a proper treatment and follow-up.

Key words: Urinary bladder, aspiration, canine, feline, risk

1. Introduction

Cystocentesis is a form of paracentesis that consists of needle puncture of the urinary bladder (UB) for the purpose of removing a variable quantity of urine by aspiration (1). The main advantage of cystocentesis is to avoid contamination of the urine from the urethra, genital tract, and integument that may complicate interpretation of routine urinalysis findings (1,2). Cystocentesis is also a practical way to obtain urine samples from animals that may not necessarily provide one on command or in a timely fashion when hospitalized (3) and to give immediate relief of patient discomfort due to bladder overdistension (4,5).

Cystocentesis is considered a simple but invasive procedure with a potential risk of complications (6). The main contraindications to cystocentesis are an insufficient volume of urine in the UB and the animal's resistance to restraint (1), recent abdominal surgery or trauma,

pyometra (7), coagulopathy, thrombocytopenia, and anticoagulant therapy (2). Finally, cystocentesis is not recommended in patients with known bladder neoplasia (2). Severe complications associated with cystocentesis, though uncommon, have been previously described especially in dogs, and include uroabdomen, septic peritonitis, and laceration of the abdominal aorta (AA) (4,8).

A large study of complications of the procedure performed under ultrasonographic guide has not been previously published; in particular, the clinical and echographic features of adverse effects of cystocentesis have not been evaluated by controlled studies. The aim of this study was to determine the types of complications related to ultrasound-guided diagnostic cystocentesis (UGDC) in dogs and cats, focusing the paper on ultrasonographic features.

* Correspondence: sabrinamanfredi@hotmail.it

2. Materials and methods

Medical record databases of five veterinary centers performing diagnostic imaging activities were searched between 2005 and 2016 to identify dogs and cats that experienced complications after UGDC. The following information was extracted from medical records: species, breed, sex, age, and weight at the time of cystocentesis. The medical records were searched to determine whether the animal was anesthetized or sedated during the procedure and when the animal was noncooperative, the transducer used, and the size of the needle and syringe. The general clinical status of patient was extracted (anamnesis, clinical evaluation, blood analysis, ultrasound examination, radiology) and the procedure of UGDC was categorized as a part of a routine check-up procedure in asymptomatic animals or when urinalysis was part of diagnostic work-up in symptomatic animals. When possible, investigators reviewed ultrasound (US) examination to evaluate the imaging findings of UB (thickening of the wall, sediment, and suspicion of neoplasia) and the state of repletion (empty, normally distended, urinary tract obstruction). The size of the needle was recorded according to the personal method of the attending ultrasonographer of each center. The results of laboratory findings of urine analysis and in particular the culture analysis were recorded. Medical records were searched to evaluate when the adverse events occurred, if immediate (within 24 h after cystocentesis) or delayed and whether or not US examination was repeated after the procedure. UB or peritoneal/retroperitoneal or abdominal wall anomalies should be recorded in the US report. Finally, data regarding time and cause of death as well as follow-up (if known) were retrieved. Complications were classified as minor and major: minor complications were defined as self-limited events; major complications were those that led to prolonged hospitalization and required intensive therapy or surgery or led to shock and death.

3. Results

From January 2005 to September 2016 we estimated a total number of approximately 26,000 UGDC procedures.

All veterinary centers performed UGDC using a 22- or 23-gauge needle and a 5-mL syringe, using US equipment provided with linear or microconvex transducers (set at 10–12 MHz and 7–8 MHz, respectively). The complications are discussed below. Twenty patients met the inclusion criteria (14 dogs and 6 cats). Among these, 5 cases were classified as major complications and 16 as minor complications (overall prevalence: 0.00076%). A dog presented two complications simultaneously. Among these, two dogs and a cat with complications underwent UGDC for routine check-up, while the remaining 12 dogs and five cats underwent UGDC as a part of diagnostic

work-up for a specific disease: chronic kidney disease (8 cases), lower urinary tract infection (6 cases), cholangitis (one case), acute kidney disease (one case), and fever of unknown origin (one case).

All the patients except one had a normally distended bladder before UGDC. Only a dog with minor complications had a mildly filled urinary bladder.

3.1. Major complications

3.1.1. Big vessel laceration

Iatrogenic laceration of the caudal vena cava (CVC) and AA occurred in two dogs (cases no. 1 and 2). UGDC was performed prior to abdominal US. In case number one, the first attempt to collect urine yielded a small amount of venous blood; a second attempt yielded urine. The UB was normally filled and no movement of the patient was described in both cases. Abdominal US was then performed to check for kidney disease (case no. 1) and fever of unknown origin (case no. 2). In the first case, an area of mixed echogenicity (approximately 2 cm) strictly adjacent to the ventral aspect of the CVC, dorsal to the UB and ventral to the colon, was seen. No flow was detected with color Doppler in the structure. The lesion seemed to push the adjacent vena cava. A small amount of anechoic fluid surrounding the lesion was visible. The main differential diagnosis included hematoma/hemorrhage in the proximity of the CVC, peritoneal granuloma/abscess, and focal edema. Laboratory findings did not support the possibility of active bleeding at that time. The dog was hospitalized due to severe kidney disease and died 4 days after admission. Necropsy revealed a small pinprick and 1 mm of iatrogenic laceration along the ventral surface of the CVC; an uncomplicated extraluminal hematoma was visible. In the second case, after cystocentesis, a heterogeneous retroperitoneal area of mixed echogenicity (approximately 3 cm) with edematous appearance was seen adjacent to the ventral aspect of the AA and dorsal to the UB (Figure 1A). A small amount of echogenic free fluid accumulation surrounding the lesion was also visible, compatible with iatrogenic perforation of the aorta and subsequent arterial blood dripping. Laboratory findings did not support the possibility of active bleeding; the dog was hospitalized and a total-body computed tomography examination was performed 24 h later to investigate the hyperthermia. A focal accumulation of free fluid in the retroperitoneal space ventral to the AA was confirmed; the UB was normally distended. No signs of active bleeding on postcontrast images were detected (Figure 1B). The dog recovered well and was discharged 2 days later.

3.1.2. Septic abdomen (pyoperitoneum)

Septic peritonitis after intraabdominal leakage of infected urine occurred in two dogs following UGDC (cases no. 3 and 4). In both cases, the state of repletion of the UB

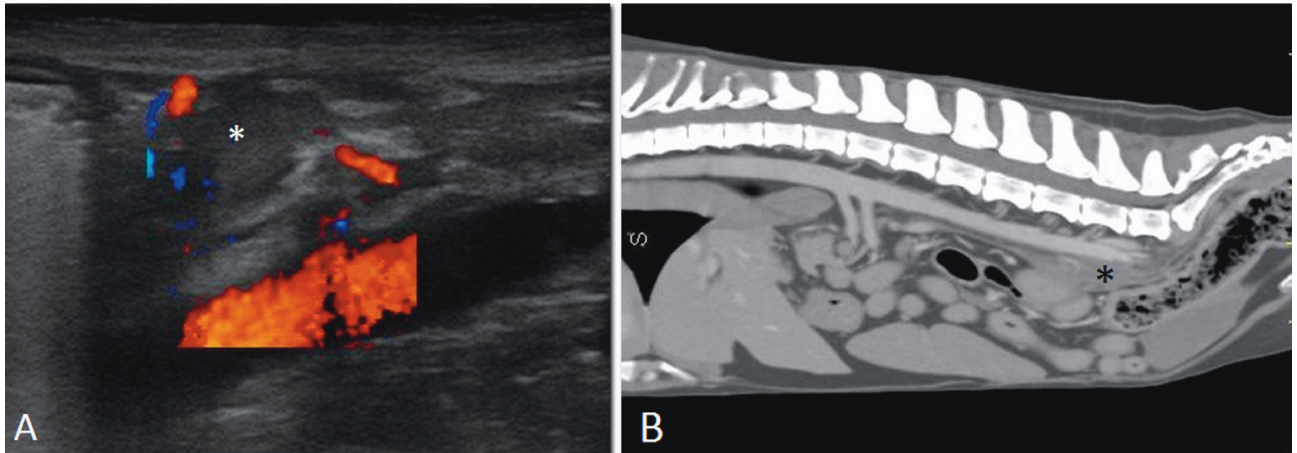


Figure 1. Iatrogenic AA laceration. A) Longitudinal ultrasound image showing a moderate amount of echogenic fluid adjacent to the AA (*). B) Sagittal postcontrast CT image of the same dog 24 h after cystocentesis. Focal accumulation of fluid (*) in the retroperitoneal space adjacent to the AA without signs of active bleeding.

was normal and no movement of the patients during the procedure was reported. In case no. 8 several attempts to collect urine were recorded. Approximately a few hours (case no. 3) and 2 days (case no. 4) after cystocentesis, both dogs were found recumbent, tachycardic, and tachypneic. According to clinical signs (abdominal pain, fever), US exam (presence of severe echogenic abdominal effusion), and laboratory findings (leukocytosis and cytological examination of abdominal fluid consisting predominantly of toxic neutrophils, many of which contained bacteria), the animals were determined to be in septic shock. Both animals were managed with surgical exploration after response to shock therapy. Cloudy yellowish (case no. 3) and reddish (case no. 4) fluids were present in the abdominal cavities and the peritoneal surfaces were inflamed. No hole was visible on the surface of both UBs; in case no. 3, the bladder wall was extremely friable to palpation. In both cases, postoperative treatment included fluid support with fluid therapy, antibiotics, antiemetics, and analgesia. Dog no. 3 died 5 h after surgery. Necropsy confirmed septic peritonitis, acute neutrophilic orchitis, and bacterial cystitis. Case no. 4 responded to therapy and the dog was discharged from the hospital 48 h later. However, the patient was euthanized due to complications related to Cushing disease a few days later. In both cases, *Escherichia coli* was isolated from the urine. Culture of peritoneal fluid was not available in either case.

3.1.3. Acute abdomen

Acute abdomen was documented in a cat (case no. 5) that had undergone UGDC 10 h earlier. No abnormalities were detected during abdominal US. The cat was presented to the emergency service with painful abdomen, hyperthermia (40 °C), and tachycardia (200 bpm). Abdominal US did not detect free abdominal fluid; however, a rounded

hyperechoic structure (2 × 2.5 cm) was seen within the UB and adherent to its wall; the structure was not vascularized and, based on history, it was presumed to be a large blood clot (BC) (Figure 2). Hematological analyses were within normal limits, and urinalysis from the cystocentesis sample, collected 10 h earlier, was normal. The cat recovered and was treated with intravenous fluids, nonsteroidal antiinflammatory drugs, and antibiotics. During recovery the cat developed mild macrohematuria. The patient was monitored in the clinic for 48 h after the event and was assessed to improve; follow-up examination one week later revealed no BC in the UB.

3.2 Minor complications

3.2.1. Nodular fat necrosis (NFN)

A cat (case no. 6) under chemotherapy due to nasal lymphoma was submitted to three UGDC procedures during a one-month period due to persistent glycosuria.

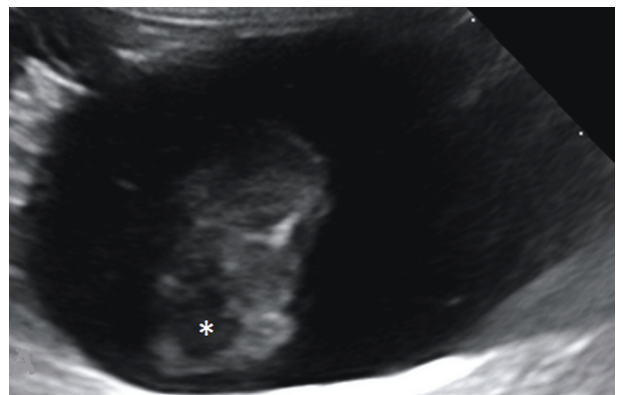


Figure 2. Echographic imaging of intravesical echoic blood clots (asterisk) detected 10 h after cystocentesis in a cat.

Each procedure was followed by AFAST (abdominal focused assement with sonography for travma) echographic check (UB wall and peritoneum). The last US evaluation revealed a solid echoic C-shaped structure of 1.5 cm in diameter with clean acoustic shadowing, adherent to the omentum and cranially to the UB (Figure 3A). The same structure was observed on radiographic examination as a focal circular (oval) mineralized soft tissue lesion, which was most consistent with NFN (Figure 3B).

3.2.2. Abscess

A female dog (case no. 7) with recurrent cystitis due to neurological bladder developed an abdominal wall abscess 10 days after UGDC. The dog had a 6-month history of paraplegia with loss of deep pain sensation. On US, a hypoechoic rounded structure (about 1 cm) was visible in the abdominal wall, just ventral to the UB (Figure 4). A posterior enhancement artefact was visible. No color Doppler signal could be detected within the lesion. A fine needle aspirate was performed: cytological analysis revealed a cell population consisting predominantly of neutrophils, many of which contained bacteria. *Enterobacter faecalis* was cultured from the abscess; the bacterium was also found in the urine sample. The abscess and cystitis were treated by antibiotics; however, the dog was lost to follow-up.

3.2.3. Urinary bladder wall tear/hematoma

A focal hyperechoic lesion in the UB wall was ultrasonographically detected in a cat immediately after UGDC (case no. 8), using a 10-MHz linear transducer. The lesion was located in the ventral UB wall a few minutes after the procedure. The urine sample appeared immediately contaminated by frank blood during collection. No free fluid suggestive of urine extravasation was detected. The complication was secondary to movement

of the patient during the aspiration; the patient developed macrohematuria lasting for 3 days. Due to worsening of renal failure, the animal was euthanized, but necropsy was not allowed by owner.

A round focal hypoechoic thickening of the ventral UB wall (1–2 mm) was detected at the site of needle puncture in two other cases and was considered most consistent with a minimal local hematoma (case no. 14). A hyperechoic and irregular focal thickening of the ventral UB wall was accidentally detected echographically 3 days after cystocentesis in a dog (case no. 19) and was considered most consistent with a focal intramural hematoma.

3.2.4. Blood clot and skin hematoma

A dog (case no. 9) developed a bladder BC 4 h after the procedure (Figure 5). The UB was mildly filled and a single attempt was documented to collect urine. Abdominal US was repeated because of transient mild macrohematuria documented during recovery. An oval (2.5 × 1 cm) intraluminal structure adherent to the dorsal wall of the UB was described; the lesion was hyperechoic with irregular margins. No color Doppler sign was detected within the lesion. The dog was euthanized 48 h later due to progressive renal disease. A cat (case no. 10) developed a small hematoma (about 2 cm) with subcutaneous tracking of blood down to the ventral abdominal wall 30 min after UGDC (Figure 6A). The cat was recovered from renal failure, and clinical evaluation 24 h later revealed a clear expansion of the subcutaneous hematoma (5 cm) (Figure 6B). AFAST scanning was repeated at that time and revealed a hyperechoic intravesical lesion attached to the ventral UB wall of 8 mm in diameter without color Doppler signal, presumed to be a BC (Figure 7). No free peritoneal fluid was seen. Systemic blood pressure, urine culture, coagulative profile, and platelets were normal. The

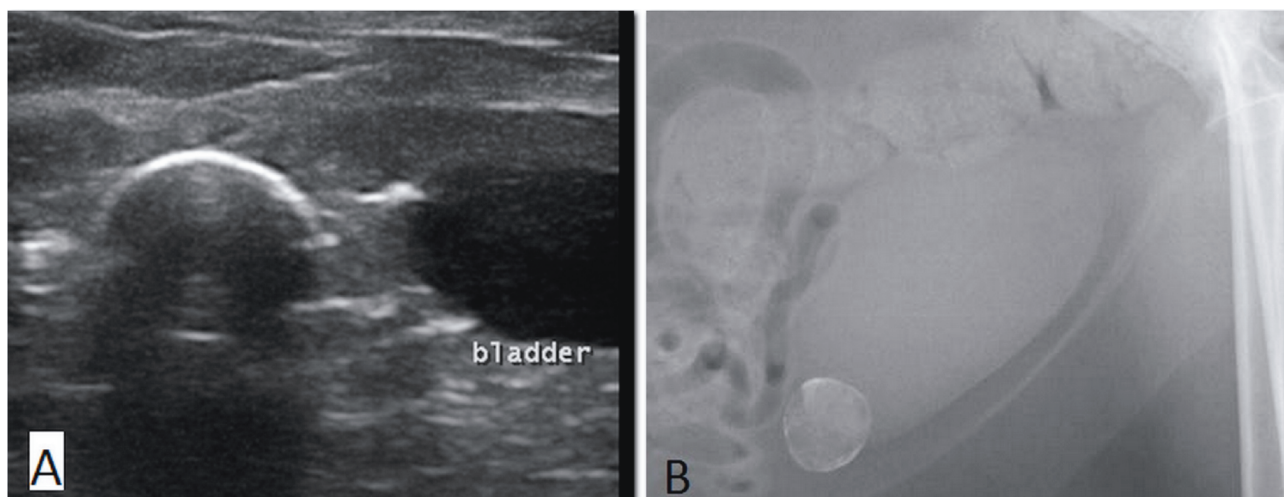


Figure 3. A) Hyperechoic C-shaped structure with clean acoustic shadowing, adherent to the omentum and cranial to the urinary bladder. B) The radiographic finding is highly suggestive of NFN.

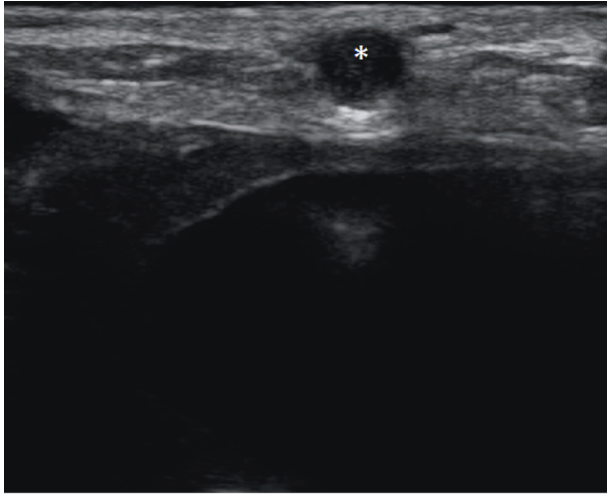


Figure 4. Ultrasonographic image of an abdominal wall abscess (*) ventral to the urinary bladder. The diagnosis was confirmed by culture analysis and fine needle aspirate.

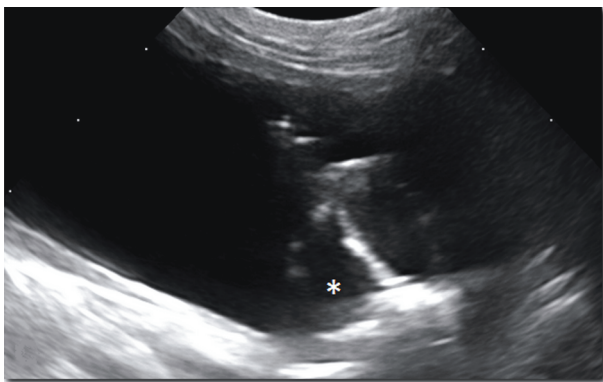


Figure 5. Echographic imaging of an intravesical echoic blood clot (asterisk) detected 4 h after cystocentesis in a dog.

UB lesion resolved within 24 h; clinical follow-up revealed resolution of the skin hematoma within 3 weeks.

3.2.5. Bladder mucosal detachment

An abdominal US was repeated 24 h after UGDC due to persistent hematuria that had developed in the last hours in a cat (case no. 11). Some hyperechoic strands and septa resembling membranes and surrounding hypoechoic intramural fluid collection were detected in the dorsal urinary bladder wall. It was presumed to be a bladder mucosal detachment (Figure 8). Furthermore, an abundant amount of mobile echogenic particles floating freely within the lumen was visible. The day before no echographic abnormalities were reported and no clinical findings related to the urinary tract. Hematuria resolved within a few days, but US was not repeated.

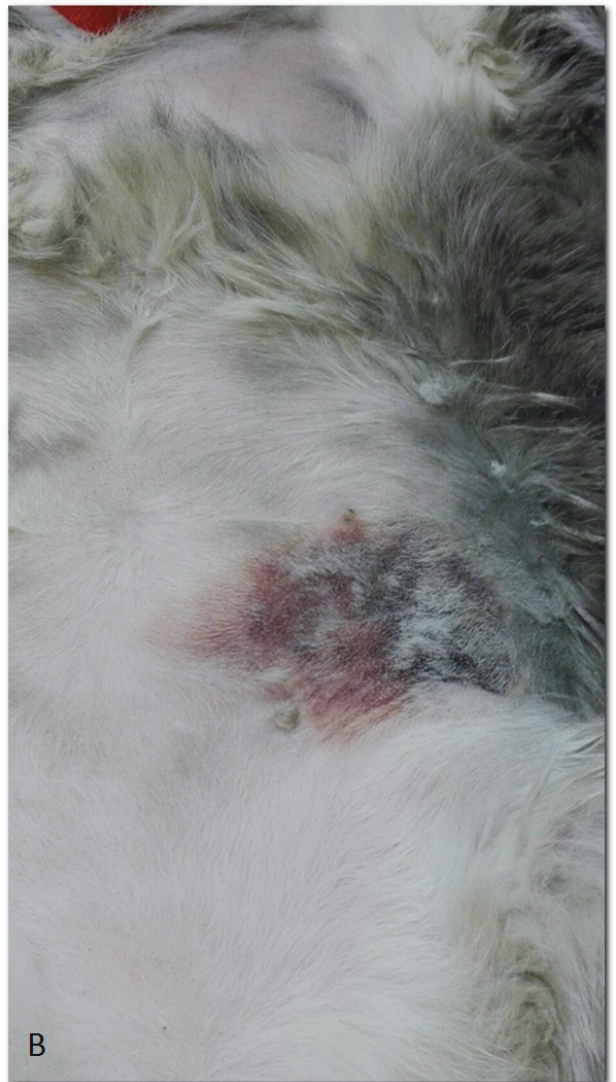
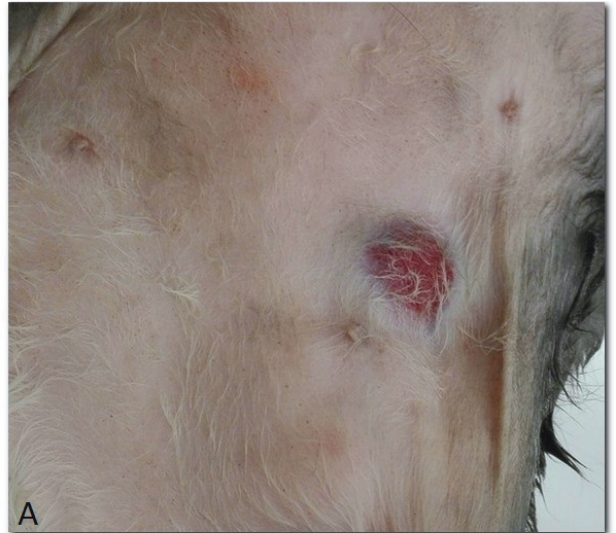
Figure 6. Skin hematoma 30 min (A) and 24 h (B) after ultrasound-guided cystocentesis in a cat with renal failure.

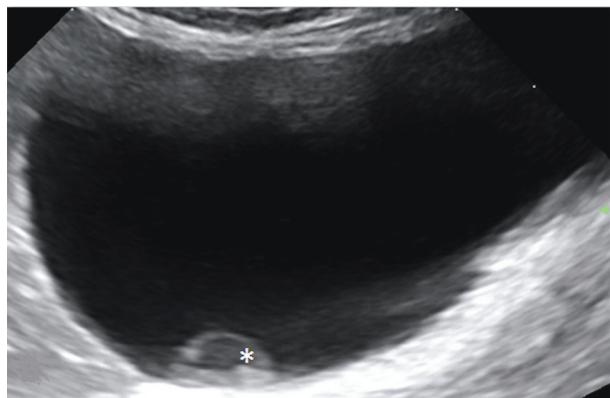


Figure 7. Intravesical echoic blood clot (asterisk) in a cat 24 h after cystocentesis in a cat.

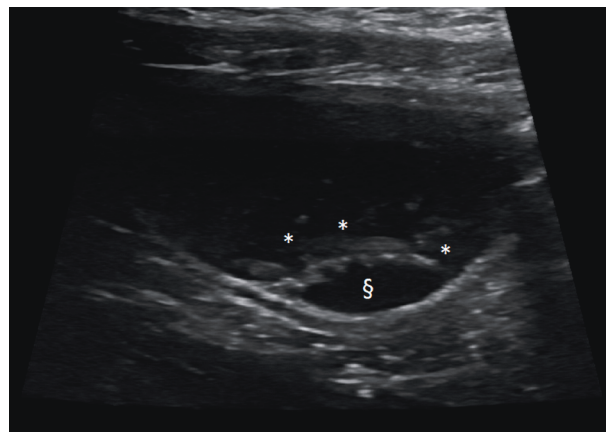


Figure 8. Some hyperechoic septa resembling membranes (*) and surrounded by anechoic fluid (§), strictly adherent to the dorsal bladder wall detected in a cat 24 h after cystocentesis.

3.2.6. Intraparietal hyperechoic mobile speckles

Some hyperechoic mobile speckles interpreted as reverberations were seen entrapped within the ventral bladder wall immediately after the procedure; these presumed gas bubbles were located exactly at the site of insertion of the needle (cases no. 12 and 13).

3.2.7. Intraluminal self-limiting bleeding

In a few cases, some hyperechoic foci or a hyperechoic line within the UB, corresponding to the needle tract, could be seen immediately following UGDC and were considered as expression of mild and self-limiting bleeding (cases no. 14, 15, 16, and 17). These foci/lines were composed of multiple small segments, which fell toward the gravity-dependent bladder wall over time. All these animals were immediately evaluated after cystocentesis to check the status of the UB. Lesions were no longer visible a few minutes later. In one case (case no. 18), an abundant amount of mobile echogenic particles floating freely within the lumen presumed to be red cells was visible 1 h after the procedure and was not present previously.

3.2.8. Focal peritonitis adjacent to the urinary bladder

A peritoneal hypoechoic area surrounded by hyperechoic fat, ventrocranially to the UB wall but strictly in contact with it, was echographically seen in a dog with hematuria (case no. 20). Irregular margins and absence of color Doppler signals strengthened the suspicion of inflammatory or traumatic peritoneal lesion. The dog had undergone abdominal US and cystocentesis 3 days before. No echographic lesions were detected at that time. US recheck after 2 weeks was unremarkable.

4. Discussion

In this series, rare cases of major and minor complications after UGDC are described. Septic peritonitis was the most severe complication leading to death. In these cases, septic peritonitis was secondary to UGDC rather than therapeutic

as described in a case report (4). In one case the source of infection in the peritoneum was presumed to be the infected urine withdrawn from the bladder by numerous attempts to perform cystocentesis. In the other case, a needle puncture could have led to microscopic bladder lesions in a patient affected by hyperadrenocorticism. As mentioned above, extravasation of infected urine can be life-threatening and the consequences more severe compared to extravasation of sterile urine (4). To our knowledge, iatrogenic CVC laceration secondary to urine aspiration was never described in the veterinary literature. Instead, AA laceration was documented in one report, but no echographic guide was used (8). Identifying the tip of the needle by US to successfully puncture the ventral bladder wall could be very important in certain cases. US is a useful diagnostic modality to assess an abdominal complication immediately after cystocentesis but can also be used to assess clinical response. Retroperitoneal hematoma was identified in both cases without a severe amount of echogenic free fluid. As the extravasation of blood was circumscribed, CVC and AA perforations were not life-threatening in our cases; however, we categorized these complications as major, as rupture of a big vessel could induce catastrophic haemorrhagic shock (8). Acute abdomen after cystocentesis was never documented. Adverse reactions following cystocentesis have been reported in feline patients; however, no US guide was used (3). Our patient developed clinical signs 10 h later and a huge intravesical BC was detected. BCs can be easily visualized by US. Transient hematuria is frequently documented following cystocentesis but is not considered a major side effect (1,2). In this patient, the intravesical BC was presumably the cause of abdominal pain and discomfort. Abdominal NFN is a condition that

has been reported in several species (9); it is considered an incidental finding without clinical signs on abdominal radiographs of obese and older animals, especially cats (9). The echographic features of NFN have been described in a few cases, which corresponded to what was reported in our case (9). This feline patient was under chemotherapy with cyclophosphamide, which has potential toxicosis to the UB due to irritant effects of the drug's metabolite, acrolein, on the bladder mucosa (10). It is possible that a leakage of urine from cystocentesis could have been an irritant for the adjacent tissues, causing peritoneal ischemia and necrosis in a short time. A similar mechanism could be evoked in the patient with peritoneal inflammation/reaction adjacent to the UB wall accidentally discovered 3 days after UGDC (case no. 20). A minimal leakage of urine, even if sterile, could be an irritant for the adjacent tissues but without clinical impact as in these cases. In humans, it is demonstrated that suprapubic aspiration of urine puts transiently neutropenic children at risk of abdominal abscess formation even if the likelihood of such consequence is considered rare (11). To our best knowledge, there are no reports documenting this kind of complication in domestic animals. The origin of the bacterium in the abscess was presumed to be the infected urine, which was withdrawn from the bladder by cystocentesis, in a debilitated patient (12). The cat that developed a subcutaneous hematoma had a normal coagulation profile. Apart from cystocentesis, no other causes for an extensive subcutaneous hematoma were identified. The passage of the needle within the subcutis could have enhanced a suction force on small capillaries in the dermal layer and caused a breach of small vessels with subsequent extravasation of blood. This complication was considered as minor as it does not require treatment and spontaneously resolves in a few days. It is also known that iatrogenic bladder wall trauma during cystocentesis is considered very uncommon, but may be encountered especially if the wall is abnormal (13). However, no detailed ultrasonographic findings are documented in the veterinary literature. In this series, formation of a luminal BC could be visualized within 24 h after the procedure and spontaneously resolved within few days. Clots are usually hyperechoic, nonshadowing, irregularly shaped luminal lesions often located in the dependent portion of the bladder (14). Usually no vascularization can be detected (13,14). The ultrasonographic features of presumed iatrogenic mucosal detachment resemble the imaging findings described in pseudomembranous cystitis (15). This condition has been described in dogs and cats and is associated with diffuse ulceration, necrosis, and hemorrhage of the bladder wall. The typical appearance is represented by wall thickening and multiple luminal

septations and strips, resembling membranes (13,15). In our case the acute presentation of symptoms and normal appearance of the UB at first presentation seem to rule out this condition, supporting an iatrogenic/traumatic cause. Small bladder wall lesions at the site of the needle aspiration (hypoechoic focal thickening of the wall) can indicate mural hematoma, without an intraluminal component. This type of lesion can be considered of little clinical impact. However, in one case (case no. 8), due to sudden movement of the cat, the urine sample was contaminated by frank blood and was not useful for analysis. In some cases, a few bubbles of air entrapped in the wall can be detected. The presence of intramural gas bubbles has been described only in cases of emphysematous cystitis (16). Furthermore, an intraluminal hyperechoic line along the needle passage can be seen, resembling mild bleeding. In one case, a significant amount of mobile echogenic particles floating freely within the lumen was detected in a dog after sneezing during the procedure (case no. 18). Predisposing factors for bleeding have not been studied in our series. Furthermore, no statistical analysis to evaluate risk factors for general complications was performed (such as weight, age, bacterial infection, or experience of the operator).

Similar size needles were used (22- or 23-gauge) in this retrospective study, as described in the literature (1,2,4,16); even if no statistical analysis was performed, in our opinion the type of needle used could be considered of little relevance on complications encountered. However, it is possible that the use of a bigger needle could result in a bigger puncture size and a major risk of bleeding, tears, or laceration. Another important issue is the size of the syringe because it determines the suction force applied on it (17). Larger syringe size (20 mL) requires significantly more strength to aspirate and may result in significant loss of needle control (17). In this study only 5-mL syringes were used, which have been proved to provide adequate needle control for the aspiration procedure (17).

As described in the literature, the state of repletion of the UB could have an impact on complications (5). In the present study only diagnostic procedures were included and patients with complications never had abnormally distended bladders before UGDC. Furthermore, one of the main contraindications to diagnostic cystocentesis is an insufficient volume of urine in the urinary bladder (1). In this study, only in one case was the UB described as mildly filled. In such a case multiple attempts to collect urine can be performed, adding risk of complications.

In general, recognition of these findings can be important when discussing the differential diagnosis of bladder wall thickening, intraluminal lesions, or perivesical

space abnormalities discovered during US. The use of high-frequency transducers (8–12 MHz) may be advised in order to detect subtle ultrasonographic changes in UB content such as moving speckles or bladder wall lesions. Findings of this report can be useful to improve familiarity with US; recognition of these lesions can be important to

make a proper diagnosis and to select the right treatment, avoiding unnecessary diagnostic procedures.

Acknowledgment

The authors thank Dr Caterina Bartoli and Dr Andrea Corsini for clinical suggestions.

References

- Kruger JM, Osborne CA, Ulrich LK. Cystocentesis. Diagnostic and therapeutic considerations. *Vet Clin North Am Small Anim Prac* 1996; 26: 353-361.
- Vap LM, Shropshire SB. Urine cytology collection, film preparation, and evaluation. *Vet Clin North Am Small Anim Prac* 2017; 47: 135-149.
- Oduwayo A, Ng ZJ, Holford AL. Probable vasovagal reaction following cystocentesis in two cats. *J Feline Med Surg Open Reports* 2015; 22: 1-4.
- Specht A, Chan D, O'Toole T, Kent M, Benson J, Rozanski EA, Rusj JE. Acute staphylococcal peritonitis following cystocentesis in a dog. *J Vet Emerg Crit Care* 2002; 12: 183-187.
- Hall J, Hall K, Powell LL, Lulich J. Outcome of male cats managed for urethral obstruction with decompressive cystocentesis and urinary catheterization: 47 cats (2009-2012). *J Vet Emerg Crit Care* 2015; 25: 256-262.
- Sørensen TM, Jensen AB, Damborg P, Bjørnvad CR, Guardabassi L, Jessen LR. Evaluation of different sampling methods and criteria for diagnosing canine urinary tract infection by quantitative bacterial culture. *Vet J* 2016; 216: 168-173.
- Davis H, Riel DL, Pappagianis M, Miguel K. Diagnostic sampling and therapeutic techniques. In: Basset JM, Thomas JA, editors. *Clinical Textbook for Veterinary Technicians*. 8th ed. London, UK: Saunders; 2013. p. 605.
- Buckley GJ, Aktay SA, Rozanski EA. Massive transfusion and surgical management of iatrogenic aortic laceration associated with cystocentesis in a dog. *J Am Vet Med Assoc* 2009; 235: 288-291.
- Schwarz T, Morandi F, Gnudi G, Wisner E, Paterson C, Sullivan M, Johnston P. Nodular fat necrosis in feline and canine abdomen. *Vet Radiol Ultrasound* 2000; 41: 335-339.
- Withrow SJ, Vail DM. The biology and pathogenesis of cancer. In: Withrow SJ, Vail DM, editors. *Small Animal Oncology*. 4th ed. St. Louis, MO, USA: Saunders; 2007. p. 14.
- Moustaki M, Stefanos E, Malliou C, Fretzayas A. Complications of suprapubic aspiration in transiently neutropenic children. *Pediatr Emerg Care* 2007; 23: 823-825.
- Datz CA. Noninfectious causes of immunosuppression in dogs and cats. *Vet Clin North Am Small Anim Prac* 2010; 40: 459-467.
- Sutherland-Smith J, Penninck D. Bladder and urethra. In: Penninck D, D'Anjou MA, editors. *Atlas of Small Animal Ultrasonography*. 2nd ed. Ames, IA, USA: Wiley Blackwell; 2015. pp. 378-383.
- O'Brien RT, Wood EF. Urinary bladder mural hemorrhage associated with systemic bleeding disorders in three dogs. *Vet Radiol Ultrasound* 1998; 39: 354-356.
- Le Boedec L, Pastor ML, Lavouè R, Reynolds BS. Pseudomembranous cystitis, an unusual condition associated with feline urine outflow obstruction: four cases. *J Feline Med Surg* 2011; 13: 588-593.
- Beatrice L, Nizi F, Callegari D, Paltrinieri S, Zini E, D'Ippolito P, Zatelli A. Comparison of urine protein-to-creatinine ratio in urine samples collected by cystocentesis versus free catch in dogs. *J Am Vet Med Assoc* 2010; 236: 221-224.
- Haseler LJ, Sibbit RR, Sibbit jr WL, Michael AA, Gasparovic CM, Bankhurst AD. Syringe and needle size, syringe type, vacuum generation, and needle control in aspiration procedures. *Cardiovasc Intervent Radiol* 2011; 34: 590-600.