



## Two cases of phacoemulsification in the presence of a small pupil using an iris expander

Ha-Eun LEE<sup>1</sup> , Joon-Young KIM<sup>1\*</sup> , Da-Eun LEE<sup>2</sup> , Jin-Gu KANG<sup>2</sup>   
<sup>1</sup>Veterinary Medical Teaching Hospital, Konkuk University, Seoul, Republic of Korea  
<sup>2</sup>College of Veterinary Medicine, Konkuk University, Seoul, Republic of Korea

Received: 21.08.2018 • Accepted/Published Online: 25.01.2019 • Final Version: 12.02.2019

**Abstract:** A small pupil and poor pupil dilation are well-known risk factors faced by veterinary ophthalmologists during and after cataract surgery. We here describe two cases of phacoemulsification performed using an iris expander (Visitec I-Ring Pupil Expander, Beaver-Visitec International, USA) for treating cataracts in dogs with small pupils. Using this technique, we performed cataract extraction effectively in dogs with insufficiently dilated pupils. This case report provides useful information on the use of an iris expander for phacoemulsification in eyes with a small pupil, which can be applied in veterinary settings.

**Key words:** Canine, cataract extraction, I-Ring pupil expander, poor pupil dilation

### 1. Introduction

Some dogs who present for cataract removal have eyes with small pupils that dilate poorly. Poor pupil dilation and fibrillary material in the pupillary axis can present significant obstacles to safe phacoemulsification of a cataract (1). Poor pupil dilation is caused by aging, synechia, previous trauma or surgery, diabetes, uveitis, chronic miotic therapy, or pseudoexfoliation (2). Small pupils complicate the phacoemulsification procedure and increase the risk of zonular dehiscence, capsular rupture, vitreous loss, dropped nucleus, tear of the iris sphincter, bleeding, and rupture of the posterior lens capsule (2,3). The surgeon can ignore the pupil size and perform small-incision surgery maneuvers through an unenlarged incision; however, this may result in the above complications (2,4).

Small pupil enlargement techniques can essentially be divided into 4 categories: viscomydriasis, surgical (papillary membrane removal, multiple partial sphincterotomies, etc.), iris stretching (iris retractors, etc.), and iris expanders (5). Pharmacological therapy, by means of nonsteroidal eye drops or strong mydriatics, may be ineffective in cases with posterior synechia (2,4). Surgical or iris stretching methods may be associated with bleeding, permanent loss of iris sphincter function, and abnormal pupil shape postoperatively (5). Iris expanders represent a more effective option for maintaining mydriasis as well as protecting the pupillary margin during surgery than traditional iris retractors (6) in human ophthalmology.

However, reports on small pupil management with an iris expander are rare in the veterinary literature. To the best of our knowledge, because iris manipulation in dogs induces more serious inflammation than in humans, the reports of small pupil management in dogs are rare.

The purpose of this case report was to present an account of treatment of cataract surgery in the eyes of dogs with small pupils using an iris expander.

### 2. Case history

#### 2.1. Case 1

A 7-year-old castrated male Poodle was referred with a left eye cataract and a history of glaucoma. The local animal hospital reported limited vision in the left eye and transient high intraocular pressure (42 mmHg), and administered antiglaucoma eye drops (Cosopt, 2% dorzolamide and 0.5% timolol, MSD, Riom, France) before referring the case to our institution.

On initial ophthalmic examination, this eye showed a positive dazzle reflex and menace response. The direct and indirect pupillary light reflex (PLR) test revealed a slow positive response. Severe conjunctival hyperemia and episcleral congestion were present. Tear production was normal in the Schirmer tear test (STT) (25 mm/min), although intraocular pressure (IOP) (TONO-Pen VET, Reichert Technologies, Depew, NY, USA) was low (6 mmHg). Slit lamp biomicroscopy (Hawk Eye, Dioptrix, Toulouse, France) indicated severe ciliary flush and mild corneal edema (Figure 1a). Additionally, posterior

\* Correspondence: canvet@hanafos.com

synechiae were detected at 10 o'clock and 2 o'clock (Figure 1a). The color of the iris was very dark and aqueous flare was detected (Figures 1a and 1b). The lens showed a hypermature cataract (Figures 1a and 1b). Posterior synechiae were also revealed. Ultrasonography revealed severe vitreous degeneration and decreased lens size (Figure 1c). An almost-closed ciliary cleft was found on an ultrasound biomicroscopy examination (UBM) (MD-320WD1101; MEDA Co., Ltd.; Tianjin, China) (Figure 1d). No abnormalities in retinal function were noted on electroretinography examination (ERG) without sedation or anesthesia with a bright flash system (10 cd s/m<sup>2</sup>, mini-Ganzfeld photopic test; RETI port, Roland Consult) (Figure 1e). The diagnosis was hypermature cataract with phacolytic uveitis. Furthermore, secondary glaucoma was also suspected because of the collapsed ciliary cleft. Cataract extraction and trabeculectomy were selected for treatment. Because of transient intraocular hypertension and the narrowed ciliary cleft, we could not use mydriatics prior to surgery.

Immediately before the surgery, atropine (Isopto Atropine, Alcon NV, Hünenberg, Switzerland), tropicamide with phenylephrine (Mydrin P, Santen Pharmaceutical Co. Ltd., Osaka, Japan), prednisolone acetate (Pred Forte, Allergan, Irvine, CA, USA), flurbiprofen sodium (flurbiprofen sodium, Bausch & Lomb, Tampa, FL, USA), and ofloxacin (Tarivid, Santen Pharmaceutical Co. Ltd.) eye drops were administered every 30 min for 2 h; however, the pupil did not fully dilate because of severe posterior synechiae. We therefore prepared an iris expander (Visitec I-Ring Pupil Expander, Beaver-Visitec International, Waltham, MA, USA).

Cefazolin (30 mg/kg intravenously; Safdin, Daehan New Pharm Co., Ltd., Seoul, Korea) was administered as a prophylactic antibiotic. Propofol (6 mg/kg intravenously; Provive 1%, Myung-moon Pharm. Co., Ltd., Seoul, Korea) was used to induce anesthesia. Anesthesia was maintained using isoflurane (Isoflurane; Choongwae Co., Ltd., Seoul, Korea). The patient was positioned in dorsal recumbency. Atracurium besilate (Atra, Hana Pharm Co. Ltd., Gyeonggi, Korea), a neuromuscular blocking agent, was intravenously injected to facilitate the globe positioning and reduce the external force arising from the extraocular muscles. The ophthalmic surgical site was routinely prepared.

A 3-mm clear corneal incision was made. Intracameral sodium hyaluronate 1.4% (Healon GV, AMO, Uppsala, Sweden) was injected into the anterior chamber. Subsequently, a second 1-mm incision was made at an angle of 70° from the first incision. Synechiolysis was performed with an iris spatula. An I-Ring pupil expander, in an inserter, was introduced into the anterior chamber through the primary incision (Figure 2a). A manipulator

was introduced to engage the I-Ring pupil expander (Figure 2b). Phacoemulsification was performed using a mini-capsulorhexis technique, because severe capsular fibrosis hindered the use of capsulectomy (7). The nucleus did not seem to be particularly hard, because the patient was only 7 years old. Instead, the progression of cataracts was rapid, and the lens material rapidly liquefied, leading to phacolytic uveitis. Thus, because the lens capsule was not stable during surgery, phacoemulsification was performed with low ultrasound power and low bottle height. An intraocular lens (IOL) was not implanted due to the ruptured posterior capsule. After performing anterior vitrectomy to remove the dislocated vitreous, the residual viscoelastic agent was removed carefully. Subsequently, the I-Ring pupil expander was gently disengaged using a manipulator and completely drawn into the inserter from the primary incision. The corneal incision was closed with a 9-0 polyglactin 910 suture (Vicryl, Ethicon LLC, Somerville, NJ, USA).

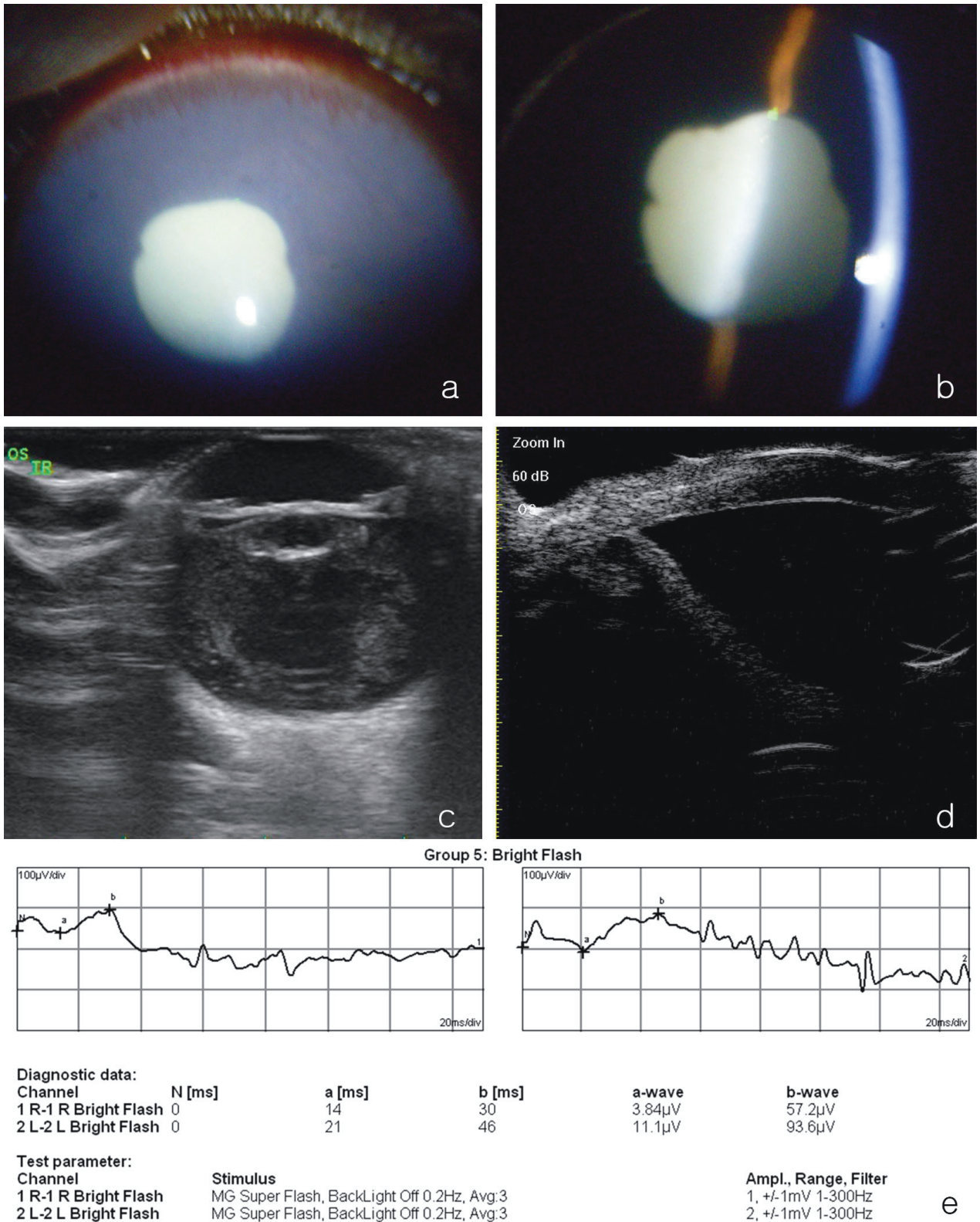
Modified filtering surgery with Ologen collagen matrix was performed following phacoemulsification using the method described by Lee et al. (8).

## 2.2. Case 2

A 2-year-old female Bichon Frise was referred with a left eye cataract that had been detected 1 month before.

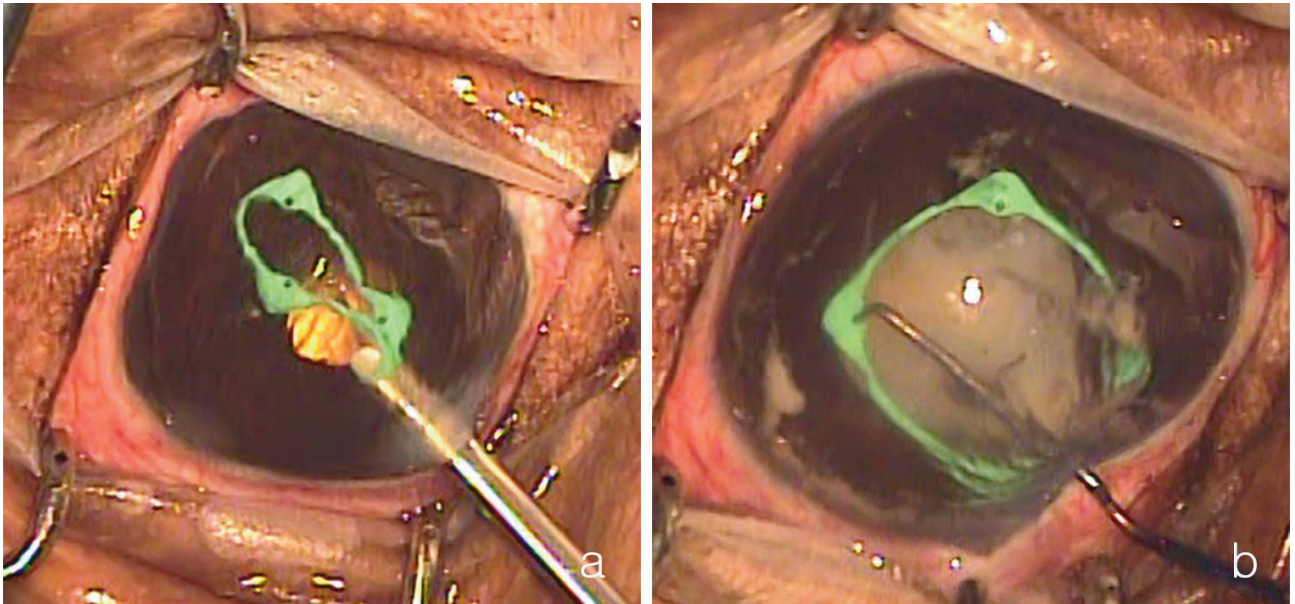
During initial ophthalmic examination, the affected eye showed a positive dazzle reflex, although the menace response was negative. The PLR, STT (21 mm/min), and IOP (22 mmHg) were normal. Slit lamp biomicroscopy indicated an immature cataract (Figures 3a and 3b). Except for the cataract, no abnormality was detected in this eye. Upon bright-flash ERG examination, retinal function was observed to be normal (Figure 3c). Ultrasound imaging showed the intumescence of the lens, but there was no evidence of lens luxation (Figure 3d). We diagnosed the dog with an immature cataract, and at the owner's request, the animal underwent cataract surgery 8 days later. Prednisolone (PDS) eye drops (twice a day) and systemic PDS (0.5 mg/kg, twice a day) were administered for 5 days before the operation.

Immediately prior to the operation, the affected eye showed miosis. The IOP was 12 mmHg. Moderate conjunctival hyperemia, mild episcleral congestion, and nictitating membrane protrusion were also detected (Figure 3e). The iris color was darker than that at initial examination, the anterior chamber was deeper, and mild aqueous flare was detected (Figure 3f). Prior to surgery, we administered atropine, tropicamide with phenylephrine, prednisolone acetate, flurbiprofen sodium, and ofloxacin eye drops every 30 min for 2 h. However, the pupil did not dilate sufficiently for cataract extraction. We therefore prepared an I-Ring pupil expander. The cause of this severe miosis was considered to be lens-induced uveitis.



**Figure 1.** Initial ophthalmic examination of the left eye in Case 1. a, b) Slit-lamp biomicroscopic examination; severe ciliary flush, mild corneal edema, and an aqueous flare are shown. c) Ultrasonography examination; increased lens opacity, decreased lens volume, and severe vitreous degeneration are visible. d) Ultrasound biomicroscopic examination showed a narrow ciliary cleft. e) Electroretinography examination showed normal cone cell function in the left eye.





**Figure 2.** Intraoperative pictures of Case 1. a) An I-Ring pupil expander, in an inserter, was introduced into the anterior chamber through the primary incision. b) A manipulator was introduced to engage the I-Ring pupil expander.

Routine ophthalmic anesthesia was performed as for Case 1. The patient was positioned in dorsal recumbency. Atracurium besilate was intravenously injected to facilitate globe positioning and to reduce external forces from the extraocular muscles. For asepsis, the ophthalmic surgical site was routinely prepared.

A 3-mm clear corneal incision was made. The anterior lens capsule was stained with Trypan Blue (Optithec Tissue Blue, Tarun Enterprises, Allahabad, India). Subsequently, Healon GV was injected into the anterior chamber. An I-Ring pupil expander, in an inserter, was introduced into the anterior chamber. The I-Ring pupil expander was placed in the pupil using a manipulator. Capsulorhexis was performed with a 26-G needle and continuous curvilinear capsulorhexis forceps. Subsequently, a second 1-mm incision was made at an angle of 70° from the first incision. Cataract extraction was performed using a routine phacoemulsification technique (Figure 4a). After an IOL (an-lens MD4-13, an-vision Inc., Salt Lake City, UT, USA) was implanted (Figure 4b), the I-Ring pupil expander was gently removed, as described in case 1. The viscoelastic agent was removed with balanced salt solution. The corneal incision was closed with a 9-0 polyglactin 910 suture.

### 3. Results and discussion

#### 3.1. Surgical outcomes and follow-up

##### 3.1.1. Case 1

After the operation, the menace response and the dazzle reflex were immediately normal. For 10 days after surgery,

tropicamide with phenylephrine, prednisolone acetate, flurbiprofen sodium, and ofloxacin eye drops were applied four times a day. The frequency of application was gradually decreased over 2 months. Although the IOP remained low (6 mmHg) for 1 month postoperatively, ocular hypertension developed later. Glaucoma was initially well controlled with antiglaucoma eye drops (Cosopt [three times a day], Xalatan [twice a day, latanoprost], Pfizer Manufacturing Belgium, Puurs, Belgium). Corneal opacity did not clear up completely, but continuously improved (Figures 5a and 5b). Ciliary flush also disappeared. Although the vision in this eye was maintained for 250 days postoperatively, it was later lost because the retina detached due to uncontrolled glaucoma.

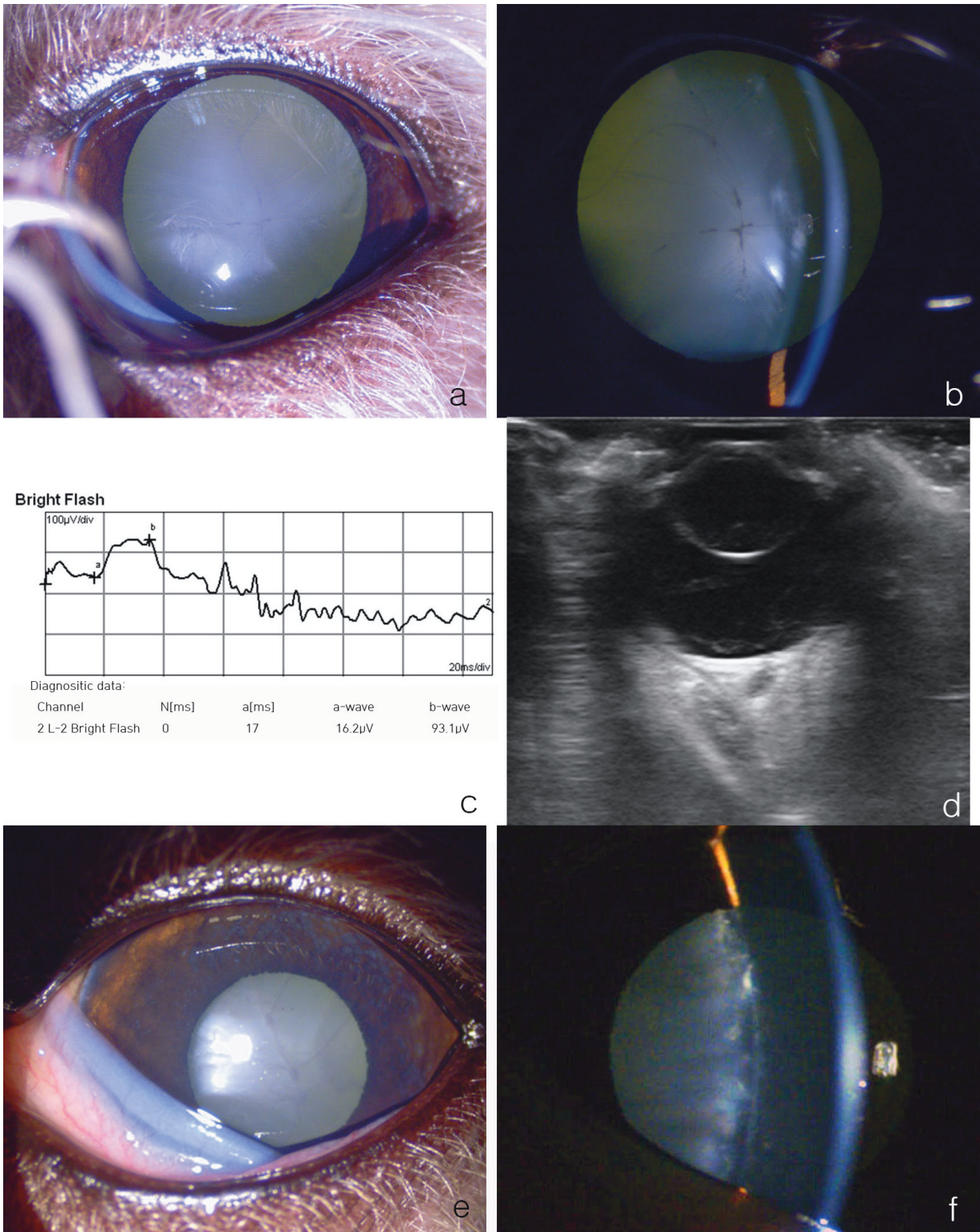
##### 3.1.2. Case 2

The menace response and dazzle reflex were found to be normal immediately after surgery. Postoperative medications were the same as in Case 1. Severe flare, moderate corneal edema, and moderate conjunctival hyperemia continued for 10 days and then disappeared. Posterior synechiae were present from the 2 o'clock to 5 o'clock position and the pupil did not dilate well during 50 days of follow-up (Figure 5c). Most of the flare had disappeared (Figure 5d). IOP (18 mmHg) and vision were well maintained.

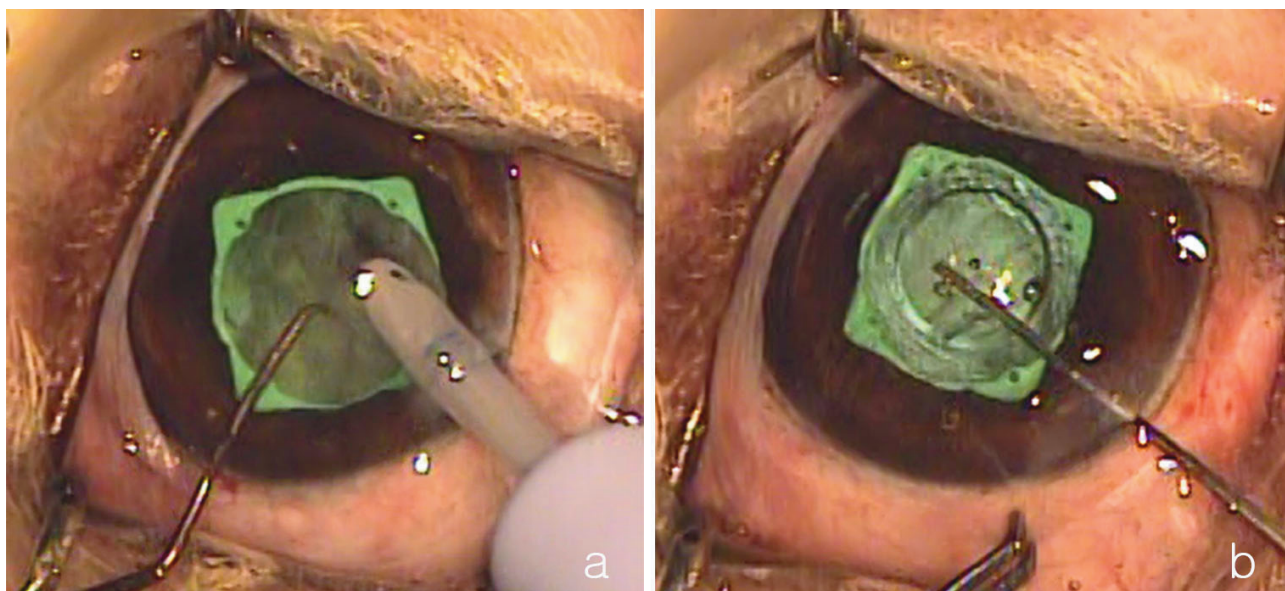
### 3.2. Discussion

A small pupil is a well-known risk factor for numerous complications during and after cataract surgery (9). Various surgical methods have been reported for dilating pupils that show poor dilation (9). Since pharmacological





**Figure 3.** Initial (a, b, c, d) and 8 days later (e, f) ophthalmic examination of left eye (Case 2). a, b) Slit lamp biomicroscopy indicated an immature cataract. c) Electroretinography examination showed normal cone cell function in left eye. d) Ultrasound revealed intumescence of the lens, but there was no evidence of lens luxation. e) Eight days later, lens opacity had deteriorated and the anterior chamber had deepened. The pupil did not dilate well even though we used mydriatics (atropine, phenylephrine, and tropicamide). f) Aqueous flare detected in the anterior chamber 8 days later.



**Figure 4.** Intraoperative pictures of Case 2. a) Cataract extraction was performed with a routine phacoemulsification technique. b) An intraocular lens was implanted through the I-Ring pupil expander.

approaches to dilating the pupil before or during cataract operation cannot guarantee the result, a mechanical pupil dilator should be used at the time of phacoemulsification (9). Iris expanders have become increasingly popular, because they allow easy mechanical dilation of the pupil (9,10). In veterinary medicine, the difficulty with small pupil cases is resolved by means of nonsteroidal eye drops, strong mydriatics, and viscomydriasis (4), although with these methods, pupil dilation remains insufficient for phacoemulsification in some cases. In cases of small pupils with posterior synechiae, iris cutting methods, iris stretching methods, or iris retainer methods are needed to dilate the pupil sufficiently (2). Iris cutting methods and iris stretching methods have similar disadvantages, in that they require a certain level of experience and carry a risk of sphincter rupture (2). Among the iris retainer methods, iris expanders compensate for the deficiencies of other two methods (2,9). Representative iris expanders are the diamond-shaped Malyugin ring (MicroSurgical Technology Inc., Redmond, WA, USA) and the circular I-Ring pupil expander (10). Both expanders have the advantage of easy insertion and removal via an injector, as compared with the traditional iris retainer, and decrease the risk of sphincter rupture because the pupil is not stretched excessively.

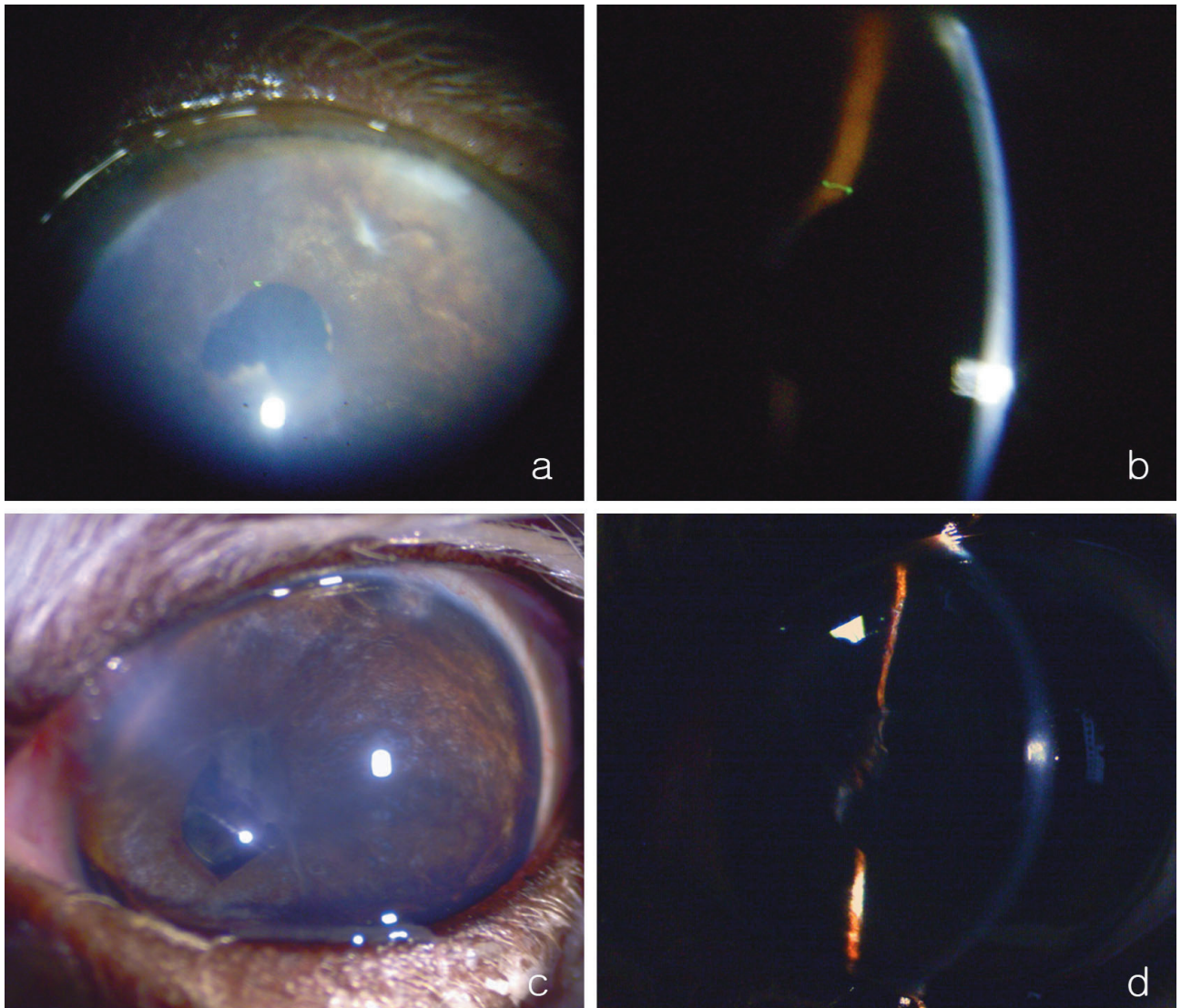
While the Malyugin ring is inserted through a 2.2-mm single port and the mean pupil diameter during surgery is 6.25 mm, the I-Ring pupil expander, which was used during our surgery, is inserted through a 2.5-mm single port and provides a mean pupil diameter of 6.3 mm during surgery (10). Although there is no major advantage in

terms of pupil diameter during surgery, the I-Ring has some advantages over the Malyugin ring. First, the I-Ring pupil expander can be more safely manipulated via four positioning holes and acts as a barrier against iris aspiration during phacoemulsification, in 360 degrees (10).

However, iris expanders also have limitations in veterinary ophthalmology. First, the canine mean pupil diameter is wider than that of humans. The diameter of expanders should therefore be wider than those developed for humans, so that the pupil size will be sufficiently wide for safe operation during canine phacoemulsification. Second, iris expanders cannot adjust the pupil size according to the preference of the surgeon (3). Third, expanders are only single-use; thus, to reduce costs, reusable expanders should be developed. Although the I-Ring pupil expander can protect the iris during surgery, the contact between the expander and the iris can induce uveitis, which results in posterior synechiae. In this present study, severe posterior synechiae were detected after surgery in both cases. It is not clear whether these synechiae originated from preoperative uveitis or contact of the pupil expander with the iris. Severe uveitis occurred in both cases after operation and may have resulted in the severe synechiae.

In Case 1, we used combined cataract and glaucoma surgery, which may have caused severe postoperative uveitis and a risk of hypotonic IOP. In this case, combined surgery was indicated because of the narrowed ciliary cleft that was detected by UBM examination and the transient ocular hypertension that was reported. We did not choose to use endolaser cyclophotocoagulation because of the severe preoperative uveitis. Filtering surgery was





**Figure 5.** Postoperative pictures. a, b) Slit lamp examination of Case 1, 65 days postoperatively. c, d) Slit lamp examination of Case 2, 50 days postoperatively.

performed as rapidly as possible after cataract surgery to minimize the probability of hypotonic IOP.

In conclusion, it is useful and effective to use the I-Ring pupil expander to manage small pupils that cannot be sufficiently dilated by medication during cataract extraction. Although mechanical iris retraction and expansion are not recommended because manipulations of the canine iris can result in serious inflammation, small-pupil enlargement techniques are occasionally required; in such cases, the I-Ring pupil expander is useful. This

technique has some limitations; for instance, it can lead to the development of synechiae, and it can dilate the pupil only to 6.3 mm in canine cataract patients. As no previous reports of using the I-Ring pupil expander to manage small pupils in veterinary medicine are available, we believe that these case reports will provide insight into a useful technique for cataract extraction in cases with an insufficiently dilated pupil, and the information provided can be applied in veterinary settings in the future.



**References**

1. Smith GT, Liu CS. Flexible iris hooks for phacoemulsification in patients with iridoschisis. *J Cataract Refr Surg* 2000; 26: 1277-1280.
2. Kershner RM. Management of the small pupil for clear corneal cataract surgery. *J Cataract Refr Surg* 2002; 28: 1826-1831.
3. Akman A, Yilmaz G, Oto S, Akova YA. Comparison of various pupil dilatation methods for phacoemulsification in eyes with a small pupil secondary to pseudoexfoliation. *Ophthalmology* 2004; 111: 1693-1698.
4. Wilkie DA, Colitz CMH. Surgery of the lens. In: Gelatt KN, Gilger BC, Kern TJ, editors. *Veterinary Ophthalmology*. 5th ed. Ames, IA, USA: John Wiley & Sons, Inc.; 2013. pp. 1234-1286.
5. Kim ES, Han SB, Lee SJ, Kim M. Cataract surgery through the small pupil. *Clin Interv Aging* 2016; 11: 1387-1389.
6. Fine IH, Packer M, Hoffman RS. Phacoemulsification in the presence of a small pupil. In: Steinert RF, editor. *Cataract Surgery, Techniques, Complications, and Management*. 2nd ed. Philadelphia, PA, USA: Saunders; 2004. pp. 211-221.
7. Gimbel HV. Principles of nuclear phacoemulsification. In: Steinert RF, editor. *Cataract Surgery, Techniques, Complications, and Management*. 2nd ed. Philadelphia, PA, USA: Saunders; 2004. pp. 153-181.
8. Lee SJ, Kim JY, Jeong SW. Modified trabeculectomy, using Ologen collagen matrix implants, for treating glaucoma in 4 dogs. *Vet Ophthalmol* 2016; 19: E23.
9. Malyugin B. Cataract surgery in small pupils. *Indian J Ophthalmol* 2017; 65: 1323-1328.
10. Tian JJ, Garcia GA, Karanjia R, Lu KL. Comparison of 2 pupil expansion devices for small-pupil cataract surgery. *J Cataract Refr Surg* 2016; 42: 1235-1237.