

Prolonged gestation in a Swedish Red cow due to fetal unilateral adrenal gland dysgenesis

Ebru KARAKAYA BİLEN¹ , Ahmet AKKOÇ² , Barış GÜNER³ ,
Gülnoz YILMAZBAŞ MECİTOĞLU⁴ , Ahmet GÜMEN⁴ , Abdulkadir KESKİN^{4,*} 

¹Department of Obstetrics and Gynecology, Faculty of Veterinary Medicine, University of Siirt, Siirt, Turkey

²Department of Pathology, Faculty of Veterinary Medicine, Uludağ University, Bursa, Turkey

³Department of Obstetrics and Gynaecology, Faculty of Veterinary Medicine, Balıkesir University, Balıkesir, Turkey

⁴Department of Obstetrics and Gynaecology, Faculty of Veterinary Medicine, Uludağ University, Bursa, Turkey

Received: 05.11.2018

Accepted/Published Online: 04.03.2019

Final Version: 04.04.2019

Abstract: A 5-year-old Swedish Red cow, pregnant for 465 days according to the last insemination record, was presented in this case. She conceived by artificial insemination at spontaneous estrus using frozen-thawed sperm of Swedish Red sire. No abnormalities were detected during gestation and no clinical signs of parturition at the expected time of delivery were noted. She was reexamined several times to eliminate breeding records error and, once prolonged gestation was confirmed, parturition was induced. The calf survived birth but died 10 min after birth. A macroscopically giant fetus was diagnosed. Following necropsy, some congenital anomalies were noticed. While the structure of the right adrenal gland was normal, disorganized soft tissue was observed in the left one, in which cortical and medullar regions could not be distinguished. The calf's pituitary gland was also normal. Thus, prolonged gestation was attributed to a case of unilateral adrenal gland dysgenesis.

Key words: Prolonged gestation, adrenal gland, dysgenesis, cow

1. Introduction

In cattle, prolonged gestation, defined as a gestational period exceeding 11 months, has been attributed to several syndromes, specifically to either anatomical or functional anomalies of the fetus [1]. Defects in the brain in general, and in the pituitary gland in particular, are often the cause of prolonged gestation in cattle, which can also be due to a primary adrenal insufficiency [2]. Infectious, toxic, and genetic causes have been associated with brain or pituitary defects, and a possible genetic background has been reported in several cattle breeds. Pituitary gland hypoplasia is associated with fetal gigantism, hirsutism, retarded ossification, and hypoplasia of the thyroid and adrenal glands. These abnormalities have been identified in the Holstein-Friesian, Ayrshire, and Guernsey breeds, resulting from an autosomal recessive gene defect [1]. Another autosomal recessive genetic defect has been reported in Guernsey, Jersey, and Swedish Red cattle, in which the affected calves are often described as "fetal monsters" suffering from hydrocephaly, fetal growth retardation, delayed ossification, hypotrichosis, and atresia jejunalis. Aplasia of the pituitary gland and/or hypoplasia of the adrenal gland are often seen on postmortem examination of the calves [3]. Parturition is initiated by

the fetal hypothalamic-pituitary-adrenal axis in several animal species, and alterations in this axis may lead to prolonged gestation. Some experimental studies verified that defects in the fetal pituitary or adrenal glands are related specifically to prolonged gestation in sheep, goats, and cattle [4–7]. According to the reports, pituitary gland aplasia is the most common abnormality associated with prolonged gestation in cattle [8–10]. However, in this case, we aimed to describe the first case report on prolonged gestation in a Swedish Red cow due to fetal unilateral dysgenesis of adrenal gland.

2. Case history and pathological findings

The 5-year-old Swedish Red cow that is the focus of this case was pregnant for 465 days, according to the last insemination record. Based on the herd's reproductive health and management records (Alpro 2000 software, DeLaval, Tumba, Sweden), she experienced no abnormalities in her previous two pregnancies and parturitions. Her average milk production in the first and second lactation was 6600 kg (305 days). In the third gestation, she conceived at spontaneous estrus by artificial insemination administered by the farm veterinarian using the same breed sire's frozen-thawed sperm. Pregnancy

* Correspondence: kadirk@uludag.edu.tr

assessments were performed at days 31 and 62 by ultrasound and gestation was confirmed. Even though she had been normally dried off at 225 days, the calf was not delivered at the expected time. The dam was subsequently reexamined three times by the farm veterinarian (at 300, 350, and 465 days of gestation) to confirm that the calf was still viable and to eliminate breeding records error.

When the dam was referred, there were no clinical signs of parturition. Specifically, no udder development, no relaxation of the pelvic ligaments, and no vulvar edema were noted during clinical examination. However, transrectal palpation failed to reveal any detectable abnormalities while indicating that the fetus was alive and was abnormally large in size. Echogenicity of the fetal fluid and placentome size were determined as normal by ultrasound examination (Honda HS 2000 equipped with a 7.5 MHz transducer, Honda, Japan). After verification of prolonged gestation, it was determined that C-section would be performed. However, the farm veterinarian decided to induce parturition by a single dose of 20 mg dexamethasone (20 mL, i.m., Devan, Vetas, Turkey) and 500 µg cloprostenol (2 mL, i.m., Estrumate, CEVA-DIF, Turkey). According to the statement of the farm veterinarian, parturition commenced 60 h after the induction. Due to the calf's abnormal size and presentation/position, dystocia occurred. The calf was delivered alive by extraction force but died 10 min after birth. The dam died two and a half months after the parturition due to the right abomasal displacement.

The fetus cadaver was transferred to the Pathology Department of Bursa Uludağ University for necropsy. The fetus weighed approximately 100 kg (Figure 1) and exhibited some congenital anomalies. When the skull was examined, prominent convexity in frontal bones was detected. The brain was mildly enlarged and hemispheric convolutions were flattened. Internal hydrocephalus was also evident. Examination of both kidneys revealed severe cystic dilatations in the pelvis renalis. In addition, the left adrenal gland was enlarged and firmer relative to the right adrenal gland (Figure 2). In the cut section of the left adrenal gland, cortical and medullar regions could not be clearly identified. Moreover, a scattering of small hemorrhagic areas throughout the left adrenal gland was observed. The right adrenal gland was of normal size and no abnormalities were detected. Tissue samples were collected from the brain, pituitary gland, adrenal glands, and other major organs and were stored in neutral-buffered formalin for routine histopathologic examination. All sections were stained with hematoxylin-eosin (H&E). Some selected slides from the adrenal mass were stained immunohistochemically with ready-to-use antichromogranin A (Thermo, Fremont, CA, USA) and anticytokeratin (Thermo) antibodies using



Figure 1. Visual comparison of the giant fetus examined in this study with another deceased fetus of normal size.

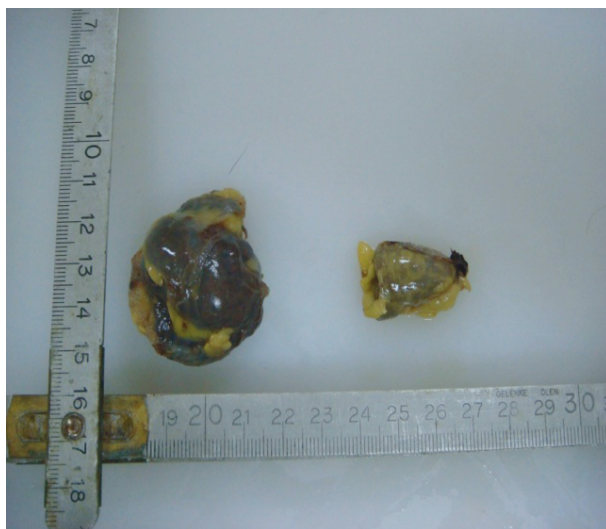


Figure 2. Gross appearance of left and right adrenal glands.

the streptavidin-biotin-peroxidase method, as previously described [11] after autoclaving the slides at 120 °C for 15 min for antigen retrieval. Diaminobenzidine (DAB) was used as chromogen. In hematoxylin-eosin stained brain sections, ependymal cells lining the lateral ventricles were flattened and subependymal white matter and cerebral cortex were thinned. Marked atrophy was found in the neurohypophyseal part of the pituitary gland, while no microscopic changes could be observed in the adenohypophyseal part. The left adrenal gland structure was abnormal, comprising disorganized soft tissue and irregularly distributed blood vessels (Figure 3). Cortical and medullar regions could not be distinguished. On the other hand, no microscopic lesions were noted in the right adrenal gland and no abnormalities were detected in any other major organs based on the microscopic

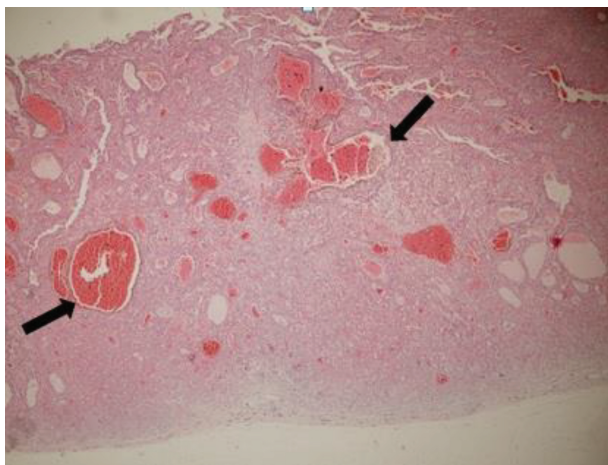


Figure 3. Microscopic section of the left adrenal gland, irregularly distributed blood vessels (see the arrows), and haphazardly and nonuniformly developed histologic structures. H&E staining with 40× magnification.

examinations. Immunohistochemically strong, diffuse cytoplasmic staining of chromaffin cells with chromogranin A antibody was used as evidence in the left adrenal gland (Figure 4).

3. Results and discussion

Prolonged gestation associated with fetal pituitary gland hypoplasia is genetically determined by an autosomal recessive gene of the fetus [1]. Prolonged gestation and the resulting fetal gigantism have been reported in Holstein-Friesian, Ayrshire, and Swedish cattle breeds; thus, these studies support the findings presented here. Fetal gigantism is expected to occur in this case due to prolonged gestational length. In several cases, postmortem findings generally reported aplasia of the pituitary and/or hypoplasia of the adrenals related with prolonged gestation [3,8]. However, unilateral adrenal dysgenesis has never been described in the current literature. Another unique aspect of this case is that the fetus had unilateral adrenal gland dysgenesis, while no apparent abnormalities were found in the pituitary gland. The pathological findings revealed not only fetal gigantism, but also skull deformities, along with defects in several organs, which is in line with the existing findings pertaining to prolonged gestation in cattle [8–10]. Authors of previous reports have postulated that the fetal adrenal gland functioning is one of the major determinants for the initiation of parturition [4,5]. The involvement of adrenal glands in delayed parturition was confirmed by Drost and Holm [7], who reported that complete bilateral removal of the adrenal glands of sheep fetuses in utero resulted in failure of the ewes to undergo labor. In the case of cattle,

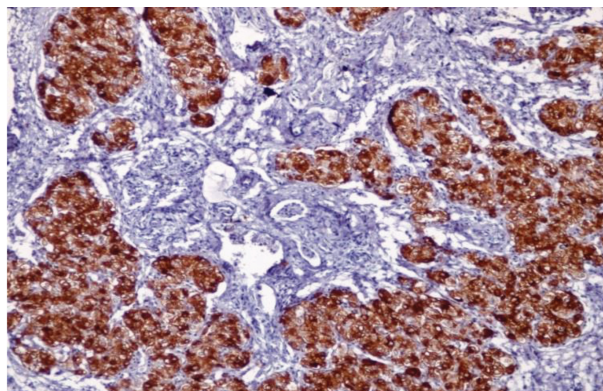


Figure 4. Microscopic section of the left adrenal gland, indicating irregularly distributed chromaffin cells. H&E staining with 40× magnification.

parturition initiation is also controlled by the fetus, but the mechanism for terminating progesterone production differs from that in sheep because it is produced by the corpus luteum in cows. During the initiation of parturition, corticotropin-releasing hormone stimulates the adrenocorticotrophic hormone (ACTH) production by the pituitary gland. Owing to this ACTH stimulation, cortisol produced by fetal adrenal glands increases, leading to the activation of producing prostaglandins. Any failure in this sequence would result in prolonged gestation. Prolonged gestation in cattle, reported by Holm [12], means that the fetus remains alive in utero for an extended period of time even though it has adrenal glands that are hypoplastic. However, no reports on prolonged gestation related to unilateral adrenal dysgenesis could be identified in the current literature. We thus posit that due to the unilateral adrenal dysgenesis, the plasma cortisol levels in the dam never reached the required concentration (25 to 100 ng/mL) to take over the initiation of the birth process from the fetus [13]. Adrenal cortices contain three layers, whereby the ACTH-dependent part is responsible for producing glucocorticoids, such as corticosterone and cortisol. Moreover, the adrenal medulla producing adrenalin and noradrenalin is located in the middle of the adrenal gland and is covered by the adrenal cortex. Adrenal medulla consists of chromaffin cells, named for their characteristic brown staining with chromic acid salts. In the case presented here, some of the selected slides from the left adrenal gland were stained with chromogranin antibody to examine the distribution and appearance of chromaffin cells. Normally, these cells should form in the medullary region of the gland. However, in our case, positively stained cells were observed in both cortical and medullary parts, indicating abnormal location of these cells, and reflecting abnormal organogenesis.

4. Conclusion

We assumed that the prolonged gestation followed by delivery of a gigantic and abnormally developed fetus that died 10 min after birth was indicative of plasma cortisol levels in the dam remaining below the concentration required for initiating parturition due to unilateral adrenal

dysgenesis in the calf. Therefore, it is likely that the dam was unable to deliver. Although prolonged gestation due to adrenal abnormalities in cattle is commonly related with hypoplasia of the glands, we have demonstrated here that unilateral adrenal dysgenesis can also lead to prolonged gestation.

References

1. Jackson PGG. Prolonged gestation in cattle and sheep. In: Kahn MA (editor). *The Merck Veterinary Manual*. 9th ed. Whitehouse Station, Great Britain: Merck&Co.; 2005. pp. 1137-1141.
2. Stabenfeldt GH, Edqvist L, Drost M. Endocrine changes during normal and prolonged bovine pregnancy. *Acta Endocrinol (Suppl.)* 1975; 199: 385.
3. McFeely RA, Ganjam VK. Induction of parturition in farm animals. *Ann Rech Vet* 1976; 7 (2): 151-156.
4. Liggins GC. The role of cortisol in preparing the fetus for birth. *Reprod Fertil Dev* 1994; 6 (2): 141-150. doi: 10.1071/RD9940141
5. Liggins GC, Kennedy PC, Holm LW. Failure of initiation of parturition after electrocoagulation of the pituitary of the fetal lamb. *Am J Obstet Gynecol* 1967; 98 (8): 1080-1086. doi: 10.1016/0002-9378(67)90031-2
6. Wood CE. Estrogen/hypothalamus-pituitary-adrenal axis interactions in the fetus: the interplay between placenta and fetal brain. *J Soc Gynecol Investig* 2005; 12: 67-76. doi:10.1016/j.jsjg.2004.10.011
7. Drost M, Holm LW. Prolonged gestation in ewes after foetal adrenalectomy. *J Endocr* 1968; 40: 293-296.
8. Graves TK, Hansel W, Krook L. Prolonged gestation in a Holstein cow: adenohipophyseal aplasia and skeletal pathology in the offspring. *Cornell Vet* 1991; 81: 277-294.
9. Cornillie P, Van den Broeck W, Simoens P. Prolonged gestation in two Belgian blue cows due to inherited adenohipophyseal hypoplasia in the fetuses. *Vet Rec* 2007; 161 (11): 388-391. doi: 10.1136/vr.161.11.388
10. Buczinski S, Bélanger AM, Fecteau G, Roy JP. Prolonged gestation in two Holstein cows: transabdominal ultrasonographic findings in late pregnancy and pathologic findings in the fetuses. *J Vet Med A* 2007; 54 (10): 624-626. doi: 10.1111/j.1439-0442.2007.00985.x
11. Akkoç A, Özyiğit MÖ, Yılmaz R, Alasonyalılar A, Cangül IT. Cardiac metastasizing rhabdomyosarcoma in a great Dane. *Vet Rec* 2006; 158: 803-804. doi: http://dx.doi.org/10.1136/vr.158.23.803
12. Holm LW. Prolonged pregnancy. *Adv Vet Sci* 1967; 11:159-205.
13. Nathanielsz PW. A time to be born: how the fetus signals to the mother that it is time to leave the uterus. *Cornell Vet* 1993; 83: 181-187.