

Cyanoacrylate tissue adhesive for the management of corneal perforation in dogs: a report of three cases

Je-Hwan JANG¹, Joon-Young KIM*¹

Veterinary Medical Teaching Hospital, Konkuk University, Seoul, Republic of Korea

Received: 18.05.2019 • Accepted/Published Online: 11.09.2019 • Final Version: 02.10.2019

Abstract: Corneal perforation can cause profound vision loss and requires immediate treatment. Bandage contact lens insertion and gluing are temporary treatment methods. However, if the patient cannot undergo surgery for a variety of reasons, these methods are inevitably used as permanent treatment methods. The use of cyanoacrylate tissue adhesive (CTA) for the management of corneal perforation in humans has been reported for several decades. Here we describe, for the first time as per our knowledge, the use of CTA (Vetbond) for the management of corneal perforation with a diameter of <3 mm in three dogs. The procedure of application was simple and only required topical anesthesia. Surgical intervention was not needed in any case, and healing was achieved with repeated applications of CTA alone. Our findings suggest that CTA application can be safely used for the management of corneal perforation (<3 mm) in dogs that cannot undergo surgery with cosmetic outcomes that are better than those achieved with conventional treatments (e.g., conjunctival grafts).

Key words: n-Butyl 2-cyanoacrylate, corneal perforation, cyanoacrylate tissue adhesive, dog

1. Introduction

Since the introduction of n-butyl cyanoacrylate application for the management of corneal diseases in humans in 1968, cyanoacrylate derivatives have been used in a number of ophthalmological surgical procedures in humans, including the treatment of corneal ulcers and perforations [1]. Ollivier et al. reported a variety of indications for a mixture of 95% n-butyl 2-cyanoacrylate and 5% cyanoacrylic acid stained with methylene blue dye [cyanoacrylate tissue adhesive (CTA); Vetbond, 3M, Loughborough, UK]; these include deep stromal ulcers, descemetocelles, small perforations, lacerations, and refractory corneal ulcers [2]. However, CTA is generally not recommended for corneal perforations or descemetocelles because of possible ocular toxicity [3]. Accordingly, it is generally avoided in cases involving severe corneal problems, such as deep corneal stromal ulcers, perforations, and impending perforations, in veterinary clinics. However, the use of CTA for corneal perforations in humans has been reported for several decades, and several studies have reported high success rates for the management of corneal thinning and perforations using CTA [4]. Corneal perforation can cause profound vision loss [5] and requires immediate treatment for preservation of the anatomical integrity of the cornea and prevention of complications such as secondary glaucoma

or endophthalmitis [5]. There are several methods for the management of corneal perforation; of these, bandage contact lens insertion and gluing are temporary methods. However, if the patient cannot undergo surgery for a variety of reasons, these methods are inevitably used as permanent treatment methods. Moreover, CTA application is relatively inexpensive and does not require systemic anesthesia. Therefore, the usefulness and safety of CTA application for the management of corneal diseases in dogs that cannot undergo surgery should be explored. To the best of our knowledge, the use of CTA for the management of corneal perforation in patients who could not be operated on because of poor systemic condition has not been described previously. Herein, we describe such cases in three dogs.

2. Case history

Case 1 involved a 10-year-old spayed female Shih-Tzu with a chronic corneal ulcer in the right eye for 2 weeks. This eye was treated with eye drops at the local animal hospital; however, the condition worsened and corneal perforation developed. Initial ophthalmological examination at our center revealed a deep ulcer measuring 2 mm in diameter in the center of the cornea and moderate blepharospasm. A very small perforation was also detected in the temporal

* Correspondence: canvet@hanafos.com

region of the ulcer; this perforation was already sealed with a fibrin plug (Figure 1). Severe corneal neovascularization from the dorsonasal limbus to the corneal ulcer was also detected (Figure 1). In the fluorescein test, all ulcer areas were stained except for the perforated area. The intraocular pressure (IOP) decreased to 10 mmHg, and a Schirmer tear test showed increased tear production (22 mm/min). The owner also reported fluid discharge for 1 day. The menace response and dazzle reflex were positive. Because of chronic heart failure, the dog could not receive systemic anesthesia.

Case 2 involved a 13-year-old spayed female Pekingese with central corneal perforation in the left eye that

disrupted the shape of the globe. The cornea appeared wrinkled, and superficial neovascularization was also present. Ophthalmological examination revealed vision loss in the left eye, with no menace response or dazzle reflex. The anterior chamber was shallow, and an aqueous leak was observed at the perforation site. The perforation measured 2 mm in diameter and was sealed with a fibrin plug (Figure 2a). IOP was considerably reduced and could not be measured. Ultrasonography revealed loss of globe integrity, and the anterior chamber was not visible (Figure 2b). The retina could not be evaluated because of the altered globe structure. Because of severe collapse in the eye due to perforation, we could not perform any further

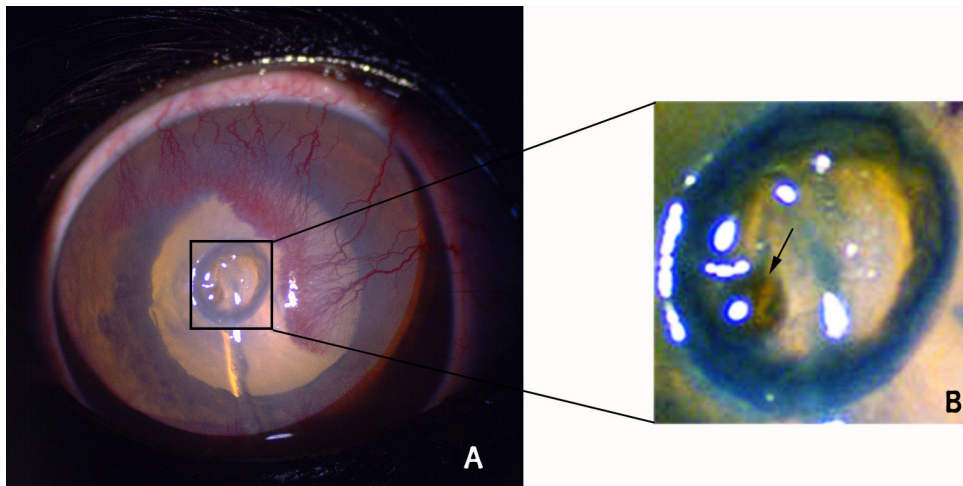


Figure 1. Initial ophthalmic examination of the right eye in Case 1. A) A very small corneal perforation is detected in the temporal region of the corneal ulcer, and it is already sealed with a fibrin plug. B) A close-up view of the ulceration. A very small perforation was detected in the temporal region of the ulcer (arrow); this perforation was already sealed with a fibrin plug. For better visualization of the perforated ulcers, the contrast in the original photo has been increased.

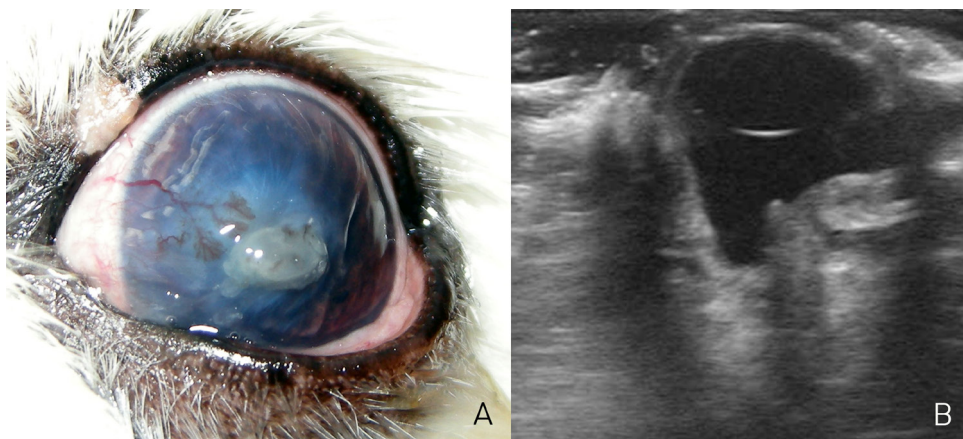


Figure 2. Initial ophthalmic examination of the left eye in Case 2. A) The anterior chamber is shallow, and an aqueous leak can be seen at the perforation site. The perforation measures 2 mm in diameter and is sealed with a fibrin plug. B) Ultrasonography shows loss of the globe integrity. The anterior chamber is not visible.

ophthalmic examination. We recommended emergency conjunctival grafting; however, physical examination revealed difficulty in breathing. Radiographic examination showed aerophagia secondary to dyspnea and right- and left-sided heart disease. The patient was deemed unfit to receive general anesthesia.

Case 3 involved a 9-year-old castrated male Shih-Tzu with central corneal perforation in the left eye. The dog had a history of glaucoma in the right eye for 2 years and had undergone chemical ablation with cidofovir. In addition, it had received treatment for chronic hepatic failure at several animal hospitals. The left eye had developed a superficial corneal ulcer that was successfully treated. Two weeks later, the same eye was subjected to severe blunt trauma, which resulted in sudden worsening of the ulcer-related symptoms. Ophthalmological examination revealed a deep stromal ulcer, severe corneal edema, a severe ciliary flush, and hypopyon. There was no menace response or dazzle reflex. A fluorescein test showed a large stained area (approximately 5 mm) in the center of the cornea. Considering the history of chronic hepatic failure, we attempted to treat the eye with levofloxacin (Cravit, Santen Pharmaceutical Co., Ltd., Japan) and 1.2% hyaluronate (an-HyPro, An-Vision, Germany). However, corneal perforation developed 1 week later (Figure 3).

The CTA application procedure in our cases was as follows. The affected eye was anesthetized with topical anesthesia (proparacaine, Alcaine, Alcon, Belgium) and fully irrigated with Hartmann's solution (Daihan Hartmann's Sol., Dai Han Pharm. Co., Ltd., Republic of Korea). Antibiotic eye drops (Tarivid, Santen Pharmaceutical Co.,

Ltd., Japan) were subsequently instilled. The ulcerated surface and adjacent epithelium were carefully dried with a cellulose sponge (Figure 4a), which was also used to debride some loose epithelium around the area of perforation. Using a 1-mL syringe with a 26-G hypodermic needle, we carefully applied a small droplet of CTA (Vetbond) to the area of perforation (Figure 4b). A compensator prevented the patient's head from moving for approximately 30 s; this allowed the glue to dry partially (Figure 4c). Once the tissue glue had dried to a certain extent, a very small amount was reapplied in the manner described above. This prevented the glue from forming droplets on the corneal surface (Figure 4d). Thus, several layers of CTA were allowed to settle over the perforated area, and the outermost membrane was kept as smooth as possible. In addition, we ensured that the adhesive did not fall on the eyelid. After the procedure, prophylactic topical antibiotics were applied twice daily for 2 weeks.

3. Results and discussion

All three cases were considered unsuitable for surgery under general anesthesia. All the patients had very poor body condition, and they were all brachycephalic breeds. In these breeds, lagophthalmos is seen as an anatomical feature of the skull; therefore, the center of the cornea is exposed, and retention of tears in this area is difficult. Because of poor body condition, the corneal epithelialization is also expected to be poor, which would exacerbate the corneal ulcer.

In Case 1, we decided to use CTA for management of the ulcer and perforation. After CTA application,

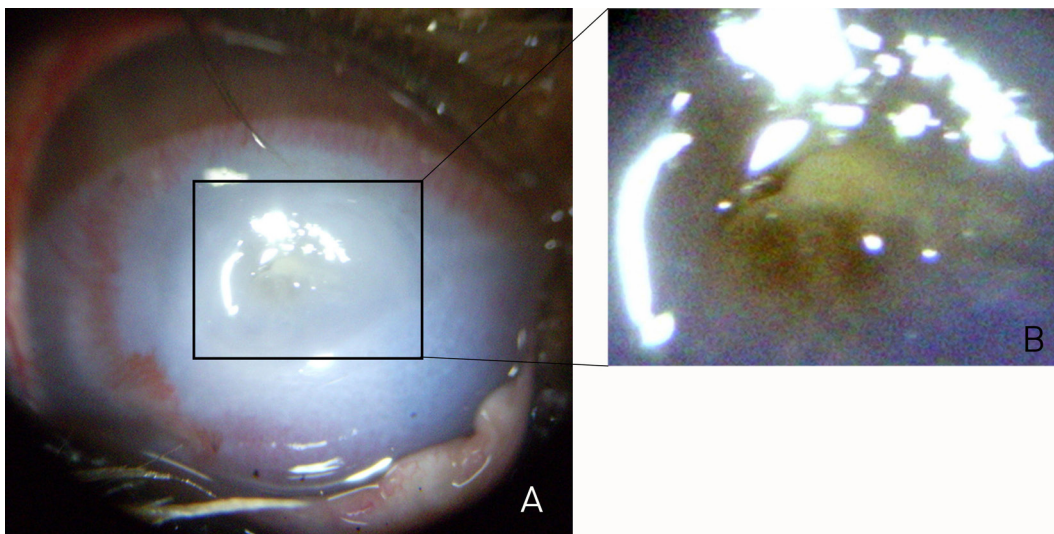


Figure 3. Initial ophthalmic examination of the left eye in Case 3. A) A deep stromal ulcer, severe corneal edema, and a severe ciliary flush can be seen. Corneal perforation is also detected at the center of the ulcer. B) Close-up view of the ulceration. This perforation was already sealed with a fibrin plug. For better visualization of the perforated ulcers, the contrast in the original photo has been increased.

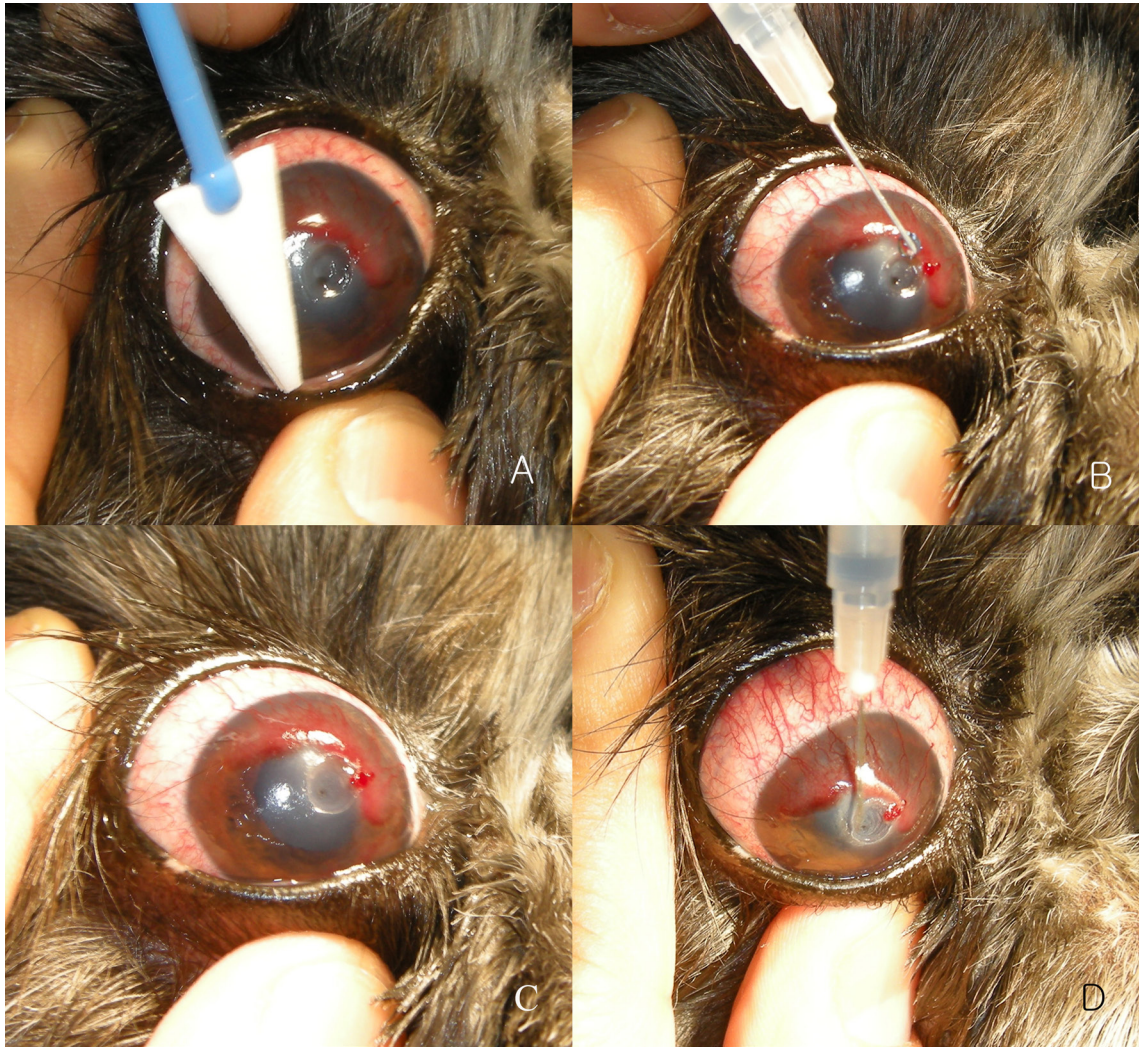

Figure 4. Method of application of CTA for the management of corneal perforation in dogs. A) The ulcer surface and adjacent epithelium are carefully dried by a cellulose sponge, which is also used to debride some loose epithelium around the perforation area. B) A small CTA droplet is carefully applied to the perforation via a needle and syringe (1-mL syringe with a 26-G hypodermic needle). C) A compensator prevents the patient's head from moving for approximately 30 s; this allows the glue to dry partially. D) Once the tissue glue has dried to a certain extent, a very small drop is applied again. This method prevents the glue from forming droplets on the cornea.

we inserted a contact lens (Pure Vision 2, Bausch & Lomb Inc., USA) and instilled antibiotic and mydriatic eye drops (Mydrin-P, Santen Pharmaceutical Co., Ltd., Japan). The contact lenses had the following parameters: diameter 14 mm, base curve 8.6 mm, thickness 0.07 mm [6], and they were maintained in the cornea for 6 days to protect the cornea and CTA. Two days later, the adhesive sloughed and the ulceration site was exposed. Nevertheless, the blepharospasm had almost resolved and the conjunctival hyperemia had reduced, although increased neovascularization and corneal leukosis could be observed. We reapplied CTA to the area of ulceration (Figure 5a), and sloughing occurred a week later. Although

the depth of the ulcer remained unchanged, there was no blepharospasm or ocular discharge. If the CTA sloughed, we reapplied it. Thus, we maintained CTA in the area of ulceration for 20 days, following which the ulcer became shallow and exhibited granulation tissue formation (Figure 5b). CTA application was discontinued, and almost complete healing with a reduction in the corneal opacity was observed 42 days after the first application. Corneal leukosis could be seen around the area of ulceration, and the neovascularization had almost disappeared (Figure 5c). We administered systemic NSAIDs and antibiotics for 10 days followed by flurbiprofen eye drops (Ocufer, Allergan Inc., Irvine, CA, USA) to treat the keratitis and

uveitis after granulation tissue was detected in the ulcer. However, we had not used antiinflammatory eye drops the first time we applied CTA because of the delay in healing of the corneal ulcer. Antibiotic eye drops were also applied during treatment.

In Case 2, CTA and antibiotic eye drops were used for treatment. We administered systemic NSAIDs and antibiotics for 7 days, followed by systemic steroids and antibiotics with 1% prednisolone acetate eye drops (Pred-forte, Allergan Inc., Irvine, CA, USA) for treating uveitis and retinitis. Two days after CTA application, the glue sloughed and revealed the perforated site. CTA was reapplied, and the perforation was sealed a week later. There

was no anterior aqueous leakage, and the corneal stroma was regenerating under the adhesive. However, severe anterior synechia was observed. We maintained CTA in the area of ulceration for 20 days. If the CTA sloughed, we reapplied it. Three weeks after the first application, the menace response and dazzle reflex were restored and the globe exhibited a normal shape on ultrasonography (Figure 6a). CTA application was discontinued at this point. During the follow-up period of 3 months, corneal leukosis developed in the area of ulceration. However, the ulcer had completely healed, the vision was restored, and the dog was able to resume normal daily activities (Figure 6b).

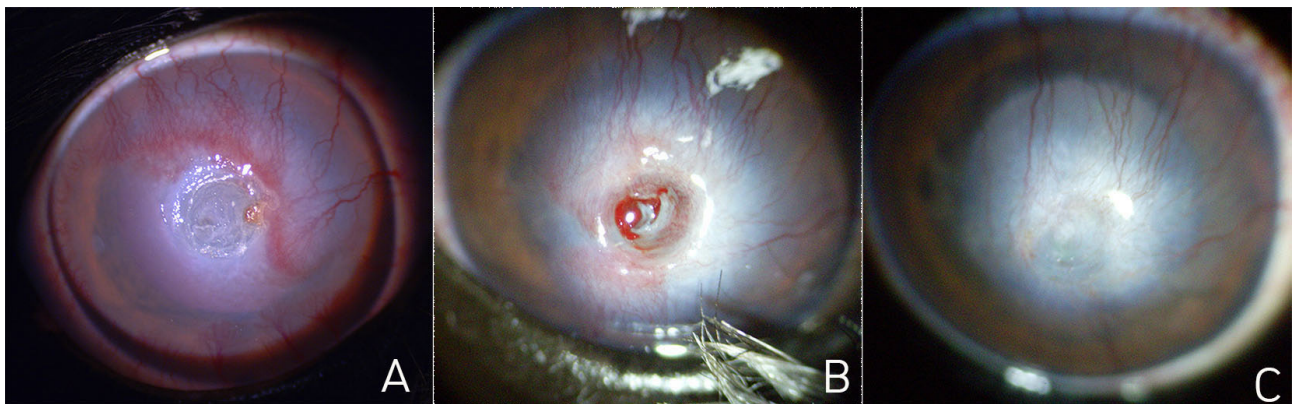


Figure 5. Healing after CTA application for the management of corneal perforation in Case 1. A) Two days after CTA application, more neovascularization and leukosis on the cornea are detected. CTA is reapplied to the area of ulceration. B) Twenty days later, granulation tissue has formed in the area of ulceration, and the depth of the ulcer has decreased. CTA application was discontinued at this point. C) Forty-two days later, most of the ulcer has healed and the cornea opacity is resolving. Corneal leukosis is present around the area of ulceration, while the neovascularization has almost disappeared.

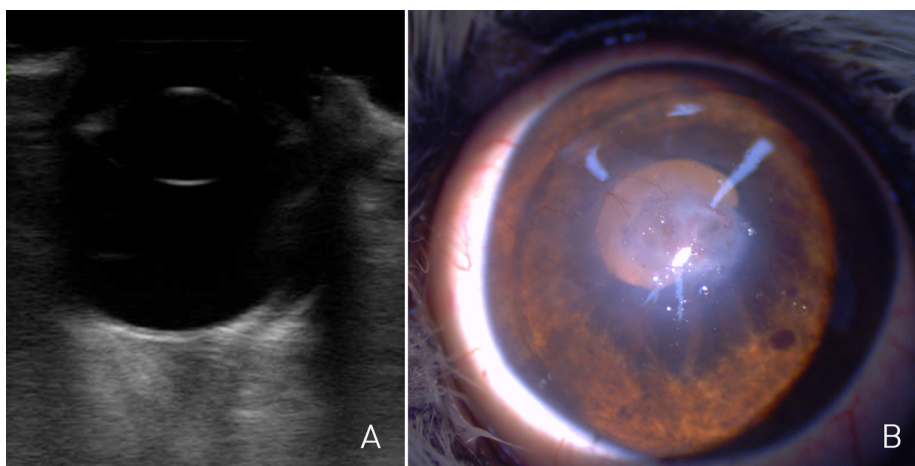


Figure 6. Healing after CTA application for the management of corneal perforation in Case 2. A) Three weeks later, the globe exhibits a normal shape on ultrasonography. CTA application was discontinued at this point. B) During the follow-up period of 3 months, corneal leukosis developed in the area of ulceration. However, the ulcer has completely healed and the vision has been restored.

In Case 3, considering the history of chronic hepatic failure, we decided to use CTA to seal the perforation, followed by the use of levofloxacin and hyaluronate eye drops. The patient had been undergoing medical treatment for a long time due to hepatic failure, and therefore, the liver was sensitive to steroids and NSAIDs. Liver serum chemistry had been severely sensitive even with any antiinflammatory agents. Due to this, the antiinflammatory treatment was stopped. Five days later, the CTA fell off the cornea, and the corneal opacity had reduced. Fibrosis and neovascularization had progressed to the perforated area (Figure 7a). Although the menace response was negative, the dog could pass through obstacles in a maze test. Sixteen days after the first application, the area of perforation was

fully covered with granulation tissue (Figure 7b). The blepharospasm resolved and the eye could open easily, with a positive menace response. CTA application was discontinued. Thirty-two days after the first procedure, the granulation tissue in the area of perforation began to disappear, the peripheral neovascularization had reduced, and the transparency of the corneal periphery had considerably increased (Figure 7c). One hundred days after the first CTA application, the neovascularization had considerably reduced and corneal leukosis due to corneal fibrosis could be observed. The iris was partially visible because of the increased transparency of the peripheral cornea (Figure 7d). The menace response and dazzle reflex were positive. After 1 year, the keratitis had resolved and

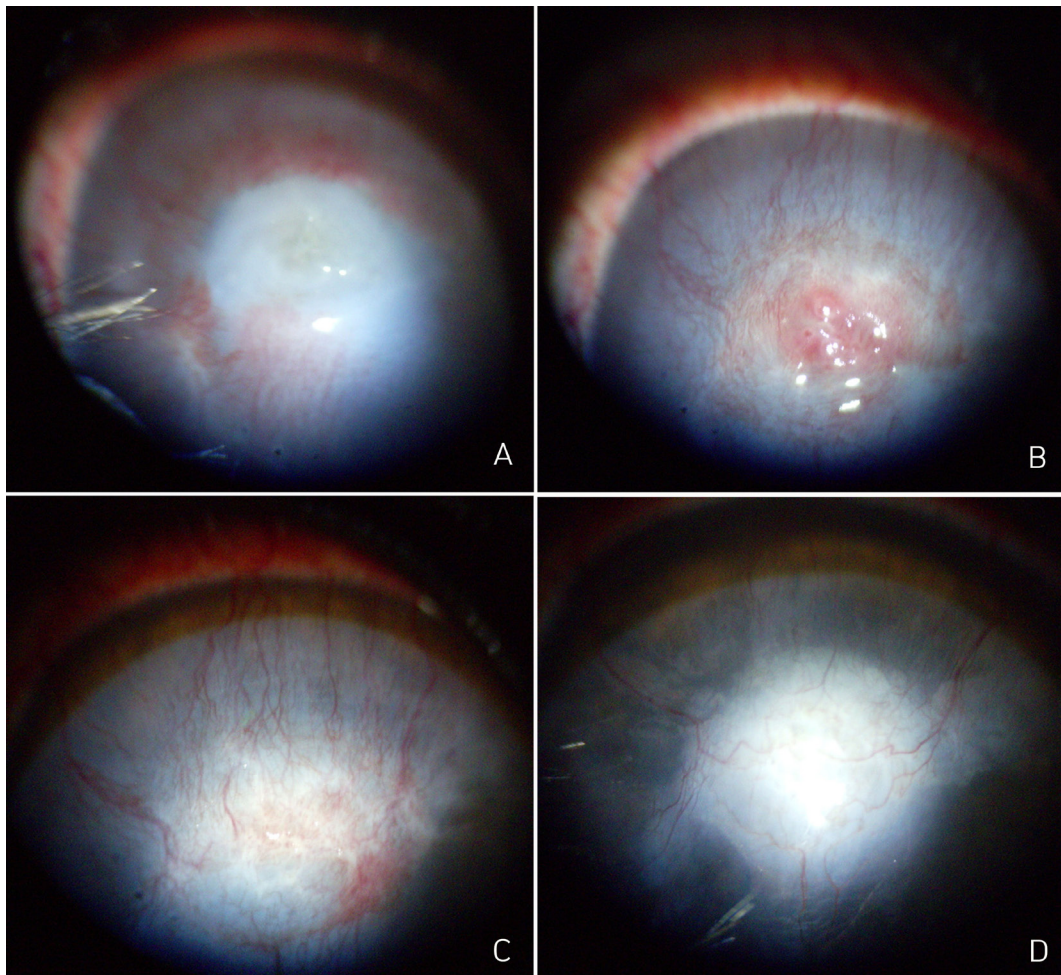


Figure 7. Healing after CTA application for the management of corneal perforation in Case 3. A) Five days after CTA application, the adhesive has fallen off the cornea and the peripheral corneal opacity has reduced. Fibrosis and neovascularization have progressed to the perforated area. B) Sixteen days later, the area of perforation is fully covered with granulation tissue. CTA application was discontinued at this point. C) Thirty-two days after the procedure, the granulation tissue in the area of perforation begins to disappear, the neovascularization at the edges of the cornea has reduced, and the transparency of the corneal periphery has considerably increased. D) After 100 days, the neovascularization has further reduced, while corneal leukosis has developed because of corneal fibrosis. The iris is partially visible because of increased transparency of the peripheral cornea. The menace response and dazzle reflex were positive at this point.

the cornea appeared healthy with a further increase in transparency.

In veterinary medicine, corneal perforations are managed with more conventional methods such as direct suturing and conjunctival grafts [7]. Because the toxicity caused by CTA can seriously affect the structure of the eye, the use of this adhesive is contraindicated in cases involving severe corneal ulcers, such as those with perforations or descemetocelles [8]. When CTA is applied to the cornea, it primarily affects the corneal endothelium and lens because it comes into direct contact with these structures [8]. Moreover, instillation of CTA into the anterior chamber can result in polymerization of the corneal endothelium and endothelial cell loss [8]. Therefore, this adhesive should be cautiously used for the management of corneal perforations. However, corneal perforation requires urgent treatment and is likely to result in vision loss if not treated in a timely and adequate manner. When general anesthesia is contraindicated for various reasons, it is difficult to find an appropriate strategy to manage corneal perforation. In such cases, the perforation can be burnt without general anesthesia. All three dogs reported here were contraindicated for surgery under general anesthesia, which was not accepted by the owners as well. Moreover, Cases 2 and 3 exhibited vision loss before treatment. It should be noted that CTA application is associated with some restrictions. According to several studies, the maximum lesion width suitable for the application of tissue adhesives is <3 mm [9]. In the present cases, the perforations measured <3 mm in diameter. CTA, being nonbiodegradable, may induce an inflammatory reaction, corneal neovascularization, a foreign body reaction, and tissue necrosis [9]. Neovascularization became more severe after CTA application in our cases, resulting in granularization of the ulcer site. Moreover, corneal leukosis developed after the ulcerated area was restored. However, the leukosis developed locally at the ulceration site, and the opacity considerably reduced as the ulcer healed. In addition, the abundant superficial vessels formed as a result of corneal neovascularization decreased with resolution

of the keratitis. Although the exaggerated corneal vascularization during the healing process increased the severity of corneal leukosis in all cases, we believe it was useful for treating the perforations. Once the ulcer healed and keratitis disappeared, this vascularization, along with the leukosis, reduced considerably. Because CTA is not biodegradable, it may interfere with corneal healing. Fibrin glues may be less toxic; however, they are not readily available [8]. In our experience, as fibrin glue is too slow to form an adhesive plug formation, it was almost impossible to apply without sedation or general anesthesia. CTA reportedly stays for 2–3 weeks if applied well [7]. In our cases, the glue did not remain for 2 weeks after the first application, probably because of aqueous humor leakage or frequent application of eye drops. Consequently, we applied CTA several times. The CTA treatment was sufficient to treat the perforations, and no further surgical intervention was required in any case [10]. During the CTA procedure, the fluorescein test was not useful because the entire ulcer area was completely covered with CTA and the ulcer area was not exposed. In general, it was confirmed that granularization in the ulcer area occurred after about 20 days of CTA application, and then CTA application was stopped. From this time, we considered the fluorescein test to be useless because of granularization. However, to the best of our knowledge, there are no studies concerning CTA application to treat corneal perforations in dogs.

In summary, we have described the use of CTA for the management of corneal perforations measuring <3 mm in dogs. Although the CTA sloughed off the cornea during the initial few days after application, it was maintained well once the affected site began to heal. All perforations showed satisfactory healing after 3 to 4 weeks. After keratitis disappeared, the corneal transparency increased, neovascularization reduced, and visual acuity returned to normal. Our findings suggest that CTA application can be safely used for the management of corneal perforation (<3 mm) in dogs that cannot undergo surgery with cosmetic outcomes that are better than those achieved with conventional treatments (e.g., conjunctival grafts).

References

- Ollivier F, Delverdier M, Regnier A. Tolerance of the rabbit cornea to an n-butyl-ester cyanoacrylate adhesive (Vetbond). *Veterinary Ophthalmology* 2001; 4 (4): 261-266. doi: 10.1046/j.1463-5216.2001.00195.x
- Ledbetter E, Gilger B. Diseases and surgery of the canine cornea and sclera. In: Gelatt KN, Gilger BC, Kern TJ (editors). *Veterinary Ophthalmology*. 5th ed. Ames, IA, USA: John Wiley & Sons, Inc.; 2013. pp. 976-1049.
- Markowitz GD, Orlin SE, Frayer WC, Andrews AP, Prince RB. Corneal endothelial polymerization of histoacryl adhesive: a report of a new intraocular complication. *Ophthalmic Surgery, Lasers and Imaging Retina* 1995; 26 (3): 256-258.
- Weiss JL, Williams P, Lindstrom RL, Doughman DJ. The use of tissue adhesive in corneal perforations. *Ophthalmology* 1983; 90 (6): 610-615.

5. Jhanji V, Young AL, Mehta JS, Sharma N, Agarwal T et al. Management of corneal perforation. *Survey of Ophthalmology* 2011; 56 (6): 522-538. doi: 10.1016/j.survophthal.2011.06.003
6. Braus BK, Riedler D, Tichy A, Spergser J et al. The effects of two different types of bandage contact lenses on the healthy canine eye. *Veterinary Ophthalmology* 2018; 21 (5): 477-486. doi: 10.1111/vop.12535.
7. Watte CM, Elks R, Moore DL, McLellan GJ. Clinical experience with butyl-2-cyanoacrylate adhesive in the management of canine and feline corneal disease. *Veterinary Ophthalmology* 2004; 7 (5): 319-326. doi: 10.1111/j.1463-5224.2004.00327.x
8. Vote BJ, Elder MJ. Cyanoacrylate glue for corneal perforations: a description of a surgical technique and a review of the literature. *Clinical & Experimental Ophthalmology* 2000; 28 (6): 437-442. doi: 10.1046/j.1442-9071.2000.00351.x
9. Sharma A, Kaur R, Kumar S, Gupta P, Pandav S et al. Fibrin glue versus N-butyl-2-cyanoacrylate in corneal perforations. *Ophthalmology* 2003; 110 (2): 291-298. doi: 10.1016/S0161-6420(02)01558-0
10. Setlik DE, Seldomridge DL, Adelman RA, Semchyshyn TM, Afshari NA. The effectiveness of isobutyl cyanoacrylate tissue adhesive for the treatment of corneal perforations. *American Journal of Ophthalmology* 2005; 140 (5): 920-921. doi: 10.1016/j.ajo.2005.04.062