

## Bullet-induced chronic cystitis in cat

Jutapoln SUNGHAN<sup>1,2</sup> , Nattakarn KHANTAPRAB<sup>1</sup> , Atigan THONGTHARB<sup>1,3,4,\*</sup> 

<sup>1</sup>Small Animal Hospital, Chiang Mai University Animal Hospital, Faculty of Veterinary Medicine, Chiang Mai University, Chiang Mai, Thailand

<sup>2</sup>Faculty of Veterinary Science, Prince of Songkla University, Songkhla, Thailand

<sup>3</sup>Department of Companion Animals and Wildlife Clinic, Faculty of Veterinary Medicine, Chiang Mai University, Chiang Mai, Thailand

<sup>4</sup>Research Center of Producing and Development of Products and Innovation for Animal Health and Production, Faculty of Veterinary Medicine, Chiang Mai University, Chiang Mai, Thailand

Received: 01.12.2019

Accepted/Published Online: 19.02.2020

Final Version: 06.04.2020

**Abstract:** A two-year-old male domestic short hair cat was referred with a history of lower urinary tract obstruction. Four months previously, this animal showed clinical signs of hematuria. On physical examination, the cat showed signs of mild abdominal cramping and painful urination or dysuria. Abdominal radiography was also performed, and the result showed a radiopaque material—a bullet—within the bladder lumen. Cystotomy was performed to remove the bullet from the urinary bladder. At that time, amikacin was used according to bacterial culture (*Enterobacter* spp.) and drug susceptibility results. Three weeks after surgery, the cat was presented to the Small Animal Hospital for a health check-up. There were no clinical signs or any complications to be seen.

**Key words:** Bullet, cat, cystitis, dysuria

### 1. Introduction

“Feline lower urinary tract diseases” (FLUTDs) describes any disorder of the urinary bladder or urethra of the cat. The causes of FLUTDs include metabolic disorders (uroliths and urethral plug), inflammatory disorders (infectious and noninfectious agents), trauma, anatomical abnormalities, neoplasia, and neurogenic disorders [1]. Inflammation of the urinary bladder or cystitis can be divided into infectious and noninfectious causes. The latter can be caused by foreign bodies, medicine, chemicals, radiation, autoimmune response, and idiopathic cystitis [2]. In humans, there have been studies reporting accidental foreign bodies in the urinary bladder including a lead pencil, balloon, pen, metallic wire, bullet, plastic container, Foley catheter, and plastic toy [3]. In veterinary medicine, there have been rare reports describing foreign bodies in the urinary bladders of cats [4,5].

In the medical literature, Cinman et al. demonstrated that 36 of 50 patients who had lower urinary tract problems were injured by bullets [6]. These objects may cause urethral obstruction and subsequent hematuria and dysuria [7]. Furthermore, the obstruction of urinary flow may cause urinary bladder distension, postrenal azotemia, and hyperkalemia. In the veterinary literature, there is one study describing urinary tract injury caused by an

air-gun pellet [5]. In the case of a penetrating gunshot wound to the abdomen, surgical exploration is highly recommended in order to prevent and control peritonitis resulting from a ruptured abdominal organ or blood vessel [8]. Furthermore, initial treatment using antibiotics is recommended in order to control gram-positive and gram-negative bacteria [9]. Both aggressive resuscitation and supportive care together with early abdominal exploratory surgery are often required [10]. However, patients with penetrating gunshot wounds to the abdomen have a worse prognosis compared with thoracic or limb injuries [9]. To our knowledge, the present study is the first report that demonstrates the successful treatment of a cat with a penetrating gunshot wound to the urinary bladder.

### 2. Case history

#### 2.1. History, clinical signs, and diagnosis

A two-year-old male domestic short hair cat was referred to the Small Animal Hospital of the Chiang Mai University Animal Hospital, Faculty of Veterinary Medicine, Chiang Mai University, with a history of lower urinary tract obstruction. Four months previously, this animal showed clinical signs of hematuria. On physical examination, the cat showed signs of mild abdominal cramping and painful urination or dysuria. Furthermore, a hard palpable skin

\* Correspondence: attvet62@hotmail.com

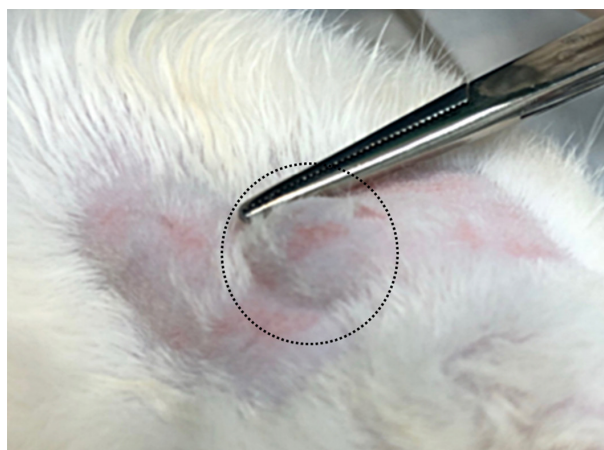
nodule was also observed at the ventral part of the neck (Figure 1). Hematological examination revealed increased packed cell volume (50%; normal range: 30%–45%), normal hemoglobin concentration (14.2 g/dL; normal range: 9.8–15.4 g/dL), normal red blood cell count ( $8.93 \times 10^6/\mu\text{L}$ ; normal range:  $5.0\text{--}10.0 \times 10^6/\mu\text{L}$ ), leukocytosis ( $27.700 \times 10^9/\text{L}$ ; normal range:  $5.5\text{--}19.5 \times 10^9/\text{L}$ ), and neutrophilia ( $25.484 \times 10^9/\text{L}$ ; normal range:  $2.5\text{--}12.5 \times 10^9/\text{L}$ ) with left shift (band neutrophils  $1.385 \times 10^9/\text{L}$ ; normal range:  $0\text{--}0.3 \times 10^9/\text{L}$ ) and thrombocytopenia ( $136 \times 10^9/\text{L}$ ; normal range:  $300\text{--}800 \times 10^9/\text{L}$ ), but a platelet smear was found to be normal. Blood chemical profiles revealed normal creatinine (1.73 mg/dL; normal range: 0.5–2.4 mg/dL), alanine aminotransferase (41 U/L; normal range: 25–97 U/L), and serum alkaline phosphatase (12 U/L; normal range: 0–45 U/L). However, blood urea nitrogen (49.4 mg/dL; normal range: 8–28 mg/dL) and plasma protein (8.4 g/dL; normal range: 5.4–7.5 g/dL) were elevated.

Abdominal radiography was also performed, and the results showed a radiopaque material within the bladder lumen (Figure 2). Other abdominal visceral organs and extraabdominal structures, including the diaphragmatic line, lumbar vertebra, pelvic structure, and abdominal wall, were normal. At that time, the owner requested exploratory laparotomy as treatment.

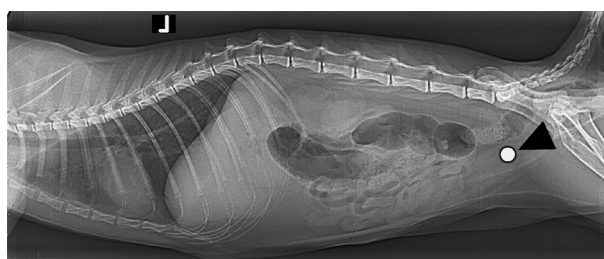
## 2.2. Case management and treatment

The cat was admitted to the hospital for surgery. Amoxicillin clavulanic acid (Augmentin, Siam Bheasach, Thailand) at 15 mg/kg was injected intravenously as a prophylactic antibiotic. Then general anesthesia was subsequently performed. Briefly, diazepam (Diazepam, The GOVT. Pharm, Thailand) at 0.2 mg/kg was introduced intravenously. Morphine (morphine sulfate injection, M&H Manufacturing, Thailand) at 0.2 mg/kg was subcutaneously injected as premedication and then induction and maintenance were conducted with propofol (Pofol, Dongkook Pharm, Korea) at 4 mg/kg and isoflurane (1.5%, Aerrane, Baxter, USA), respectively.

In the surgical procedures, the cat's hair coat was clipped and the surgical site was prepared with an aseptic technique. An abdominal surgical procedure was performed via a caudal ventral midline incision. Visceral organs were investigated and there was no remarkable lesion. For the cystostomy procedure, a stay suture was placed at the apex of the urinary bladder using 3/0 polydioxanone absorbable suture material (ETHICON PDS II, Johnson & Johnson International, Belgium). During the operation, the structure of the urinary bladder was evaluated. No evidence of scarring or necrosis was observed on the outer layer of the bladder. However, there was a bullet within the bladder lumen (Figure 3). A tom-catheter (KRUUSE, BUSTER Cat Catheter, side holes, with stylet, China) was inserted into the urinary bladder and then warm irrigating fluid (800 mL) was used to flush tissue debris. Bacterial culture together with drug sensitivity

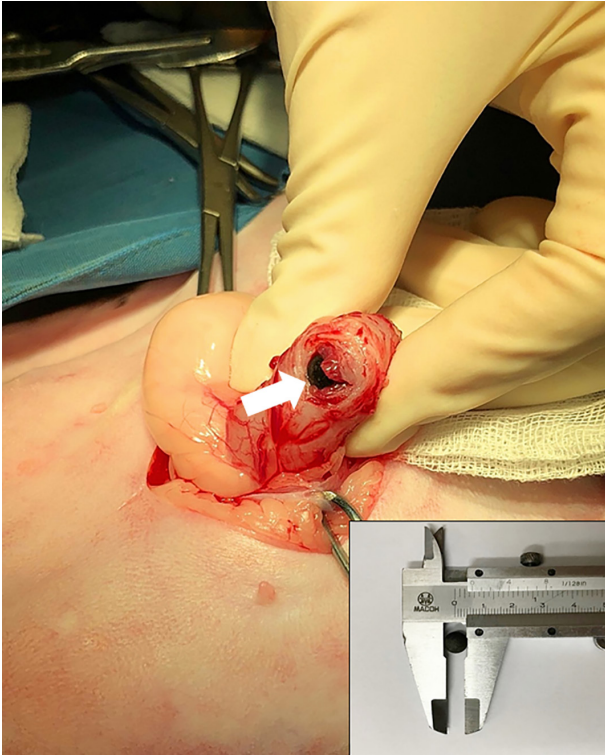


**Figure 1.** Neck. Cat. A bullet under the skin (dashed circle).



**Figure 2.** Abdominal radiograph (lateral view). Cat. Radiopaque material within the urinary bladder (arrowhead).

tests were also performed. Abdominal radiography was then performed after removing the foreign body. The bladder wall was closed with a single layer by an interrupted pattern with 3/0 polydioxanone absorbable suture material. Linea alba closure was performed by simple continuous pattern with 2/0 polyglactin 910 absorbable suture material (Tricryl 910, EFADA Medical Industries, Jordan). The muscle layer was subsequently closed by simple interrupted pattern with 2/0 polyglactin 910 suture to eliminate dead space. Subcutaneous tissue closure was done by simple continuous pattern with 3/0 polyglactin 910 suture and the skin was closed by simple interrupted pattern with 4/0 nylon suture (Dafilon, B. BRAUN, Germany). During postoperative care, a tom-catheter was placed for 3 days. Furthermore, the animal was closely monitored in an intensive care unit to evaluate clinical condition, pain score, and hematological profile. The bacterial culture identified *Enterobacter* spp. Therefore, amoxicillin-clavulanic acid (Augmentin, Siam Bheasach, Thailand) at 15 mg/kg intravenously twice a day and amikacin sulfate (Amikoside, NIDA PHARMA INC.) at 10 mg/kg by subcutaneous injection once a day were used following the results of antimicrobial susceptibility tests for prophylaxis. The urethral stenosis was treated with prazosin



**Figure 3.** Cystotomy. Cat. A bullet at the surgical site (arrow). This material is black with rounded shape (inset).

at 1 mg (Lopress, Siam Bheasach Co., Ltd., Bangkok, Thailand) for 3 weeks. Morphine sulfate at 0.3 mg/kg was subcutaneously injected for the first 24 h after surgery and then a fentanyl patch (Sandoz, Hexal AG Holzkirchen, German) was placed for 3 days for pain control. The stitches were removed one week after surgery.

On the first postoperative day, a blood sample was collected for hematological and blood chemical examination and the results showed normal packed cell volume (31%; normal range: 30%–45%), leukocytosis ( $48.510 \times 10^9/L$ ; normal range:  $5.5\text{--}19.5 \times 10^9/L$ ), and segmented neutrophilia ( $43.659 \times 10^9/L$ ; normal range:  $2.5\text{--}12.5 \times 10^9/L$ ) with left shift (band neutrophils  $0.970 \times 10^9/L$ ; normal range:  $0\text{--}0.3 \times 10^9/L$ ) and normal platelets ( $310 \times 10^9/L$ ; normal range:  $300\text{--}800 \times 10^9/L$ ) but the platelet smear was decreased, whereas blood chemistry profiles were normal. Three weeks after cystotomy, the cat was presented to the Small Animal Hospital for a health check-up. There were no clinical signs or any complications to be seen.

### 3. Results and discussion

The occurrence of a bullet in the urinary bladder has been rarely documented in animals. In the veterinary literature, there have been few studies describing the presence of a foreign body in the urinary bladder or other parts of the

urinary tract. One study demonstrated a sterile lead implant (air-gun pellet) in a feline bladder [5]. Animals that live outside and are unsupervised are at risk [11].

In the present study, the hematological profiles revealed leukocytosis and neutrophilia with left shift. Generally, neutrophils will migrate from blood circulation into the infection site to destroy pathogens. This phenomenon results in increasing neutrophil production in order to compensate for neutrophil consumption [12]. The elevation of packed cell volume and blood urea nitrogen, as well as hyperproteinemia, indicated dehydration [13,14].

In the case of a gunshot wound, the entrance and exit wounds should be evaluated. Furthermore, ecchymosis, blood at the urethral meatus, and hematuria should be evaluated and a digital rectal examination should be performed [6]. In this study, a young male cat showed red urine after being visited outside and presented a bullet in the urinary bladder upon surgery without entry or exit wounds. In general, the presence of a retained bullet in an animal's body is associated with an accidental gunshot [15]. All kinetic energy is normally absorbed in the body cavity when the bullet is fired from a low-velocity weapon or passes through dense tissues [16].

Gunshot wounds are the most common projectile injuries [17]. Common diagnostic tools for evaluating projectiles and locating wounds, bone fractures, and hemoperitoneum are abdominal radiography and ultrasound [17,18]. Abdominal and pelvic CT and CT-cystography are used to clarify the bladder trauma types and rule out bladder injuries [19]. In the present study, however, abdominal radiography was used owing to the limitation of advanced diagnostic imaging facilities (time, cost, special procedure, and availability). In domestic animals, all cases of penetrating injuries have to be explored to evaluate the severity of internal organ or body wall damage [20]. Furthermore, patients with gunshot wounds should receive adequate treatment if expected to survive [9]. In the present study, we found a bullet within the bladder, bladder wall thickening, and *Enterobacter* infection indicating inflammation of the bladder [2].

In conclusion, in the case of a gunshot injury, the presenting history, physical examination, and clinical features may be indistinguishable from other diseases. Imaging study, therefore, is suggested to be an important diagnostic tool for differential diagnosis. In the present study, radiography was a reliable technique. Surgery is the most effective treatment with good prognosis. Moreover, early diagnosis and continuous antibiotic prophylaxis also increase the chance of survival.

### Acknowledgment

The authors thank the Small Animal Hospital, Chiang Mai University Animal Hospital, Faculty of Veterinary Medicine, Chiang Mai University, for supporting our data collection efforts. This research was partially supported by Chiang Mai University.

## References

1. Pusoonthornthum R, Pusoonthornthum P, Osborne CA. Risk factors for feline lower urinary tract diseases in Thailand. *Thai Journal of Veterinary Medicine* 2012; 42 (4): 517-522.
2. Grover S, Srivastava A, Lee R, Tewari AK, Te AE. Role of inflammation in bladder function and interstitial cystitis. *Therapeutic Advances in Urology* 2011; 3 (1): 19-33. doi: 10.1177/1756287211398255
3. Bansal A, Yadav P, Kumar M, Sankhwar S, Purkait B et al. Foreign bodies in the urinary bladder and their management: a single-centre experience from North India. *International Neurourology Journal* 2016; 20 (3): 260-269. doi: 10.5213/inj.1632524.262
4. Cherbinsky O, Westropp J, Tinga S, Jones B, Pollard R. Ultrasonographic features of grass awns in the urinary bladder. *Veterinary Radiology & Ultrasound* 2010; 51 (4): 462-465. doi: 10.1111/j.1740-8261.2010.01688.x
5. Andre PG, Jackson OF. Lead foreign body in a cat's bladder. *Journal of Small Animal Practice* 1972; 13 (2): 101-102. doi: 10.1111/j.1748-5827.1972.tb06836.x
6. Cinman NM, McAninch JW, Porten SP, Myers JB, Blaschko SD et al. Gunshot wounds to the lower urinary tract: a single-institution experience. *Journal of Trauma and Acute Care Surgery* 2013; 74 (3): 725-731. doi: 10.1097/TA.0b013e31827e1658
7. Kollias GN, Kyriakopoulos MG. Urologic complications from a gunshot wound and the rare course of a bullet in the human body. *Scandinavian Journal of Urology and Nephrology* 1997; 31 (4): 397-399. doi: 10.3109/00365599709030628
8. Franke A, Bieler D, Friemert B, Schwab R, Kollig E et al. The First aid and hospital treatment of gunshot and blast injuries. *Deutsches Arzteblatt International* 2017; 114 (14): 237-243. doi: 10.3238/arztebl.2017.0237
9. Fullington RJ, Otto CM. Characteristics and management of gunshot wounds in dogs and cats: 84 cases (1986-1995). *Journal of the American Veterinary Medical Association* 1997; 210 (5): 658-662.
10. Kirby BM. Peritoneum and retroperitoneum. In: Tobias KM, Johnston SA (editors). *Veterinary Surgery: Small Animal*. 1st ed. St Louis, MO, USA: Saunders; 2012. pp. 1391-1423.
11. Pavletic MM. A review of 121 gunshot wounds in the dog and cat. *Veterinary Surgery* 1985; 14: 61-62.
12. Honda T, Uehara T, Matsumoto G, Arai S, Sugano M. Neutrophil left shift and white blood cell count as markers of bacterial infection. *Clinica Chimica Acta* 2016; 457: 46-53. doi: 10.1016/j.cca.2016.03.017
13. Boyd JW. The relationships between blood haemoglobin concentration, packed cell volume and plasma protein concentration in dehydration. *British Veterinary Journal* 1981; 137 (2): 166-172. doi: 10.1016/s0007-1935(17)31734-7
14. Robinson BE, Weber H. Dehydration despite drinking: beyond the BUN/creatinine ratio. *Journal of American Medical Directors Association* 2004; 5: S67-71. doi: 10.1097/01.JAM.0000035860.71185.39
15. Pavletic MM, Trout NJ. Bullet, bite, and burn wounds in dogs and cats. *Veterinary Clinics of North America: Small Animal Practice* 2006; 36 (4): 873-893. doi: 10.1016/j.cvsm.2006.02.005
16. Madhu DN, Monsang SW, Singh J, Pawde AM, Amarpal et al. Gunshot wound in a dog and its management. *Indian Journal of Canine Practice* 2014; 6 (2): 154-155.
17. Capak H, Bottegaro NB, Manojlovic A, Smolec O, Vnuk D. Review of 166 gunshot injury cases in dogs. *Topics in Companion Animal Medicine* 2016; 31 (4): 146-151. doi: 10.1053/j.tcam.2016.11.001
18. Salim A, Velmahos GC. When to operate on abdominal gunshot wounds. *Scandinavian Journal of Surgery* 2002; 91 (1): 62-66. doi: 10.1177/145749690209100110
19. Fentes D, Caamano V, Parrado L, Grille J, Nunez H et al. Gunshot bladder trauma: case report and literature review. *Actas Urologicas Espanolas* 2006; 30 (9): 947-953. doi: 10.1016/s0210-4806(06)73564-1
20. Risselada M, de Rooster H, Taeymans O, van Bree H. Penetrating injuries in dogs and cats - A study of 16 cases. *Veterinary and Comparative Orthopaedics and Traumatology* 2008; 21 (5): 434-439. doi: 10.3415/VCOT-07-02-0019