

Computed tomography and osteological examination of the nuchal perforations in Byzantine cattle skulls

Vedat ONAR^{1*}, Aleksander CHRÓSZCZ², Dominik PORADOWSKI²,
Nazan GEZER İNCE³, Mehmet Ali POLAT⁴, Rahmi ASAL⁴

¹Osteoarchaeology Practice and Research Centre and Department of Anatomy, Faculty of Veterinary Medicine, Istanbul University-Cerrahpaşa, İstanbul, Turkey

²Department of Biostructure and Animal Physiology, Faculty of Veterinary Medicine, Wrocław University of Environmental and Life Sciences, Koźuchowska 1, Wrocław, Poland

³Department of Anatomy, Faculty of Veterinary Medicine, İstanbul University-Cerrahpaşa, İstanbul, Turkey

⁴İstanbul Archaeological Museums, İstanbul, Turkey

Received: 23.06.2022 • Accepted/Published Online: 12.09.2022 • Final Version: 18.10.2022

Abstract: This study presents computed tomography (CT) and osteological observations of nuchal perforations in the Middle-Late Byzantine cattle skulls, unearthed from Yenikapı Metro and Marmaray excavations (ancient Theodosius harbour), İstanbul, Türkiye. A total of 17 skulls with perforations of various size, ranging from elliptical to triangular, located in the nuchal (posterior) region of *protuberantia intercornualis* were examined. Rounded edges and smooth inner walls of these perforations indicated that they were formed when the animals were alive (ante mortem). The CT helped to understand the details of the caudal and dorsal part of head as well as the relationships between these perforations and other cranial structures. The osteological evidence and possible causes of the nuchal perforations were discussed. The animal age and sex were also taken under consideration. The study provided the archaeological proof that the cattle from Yenikapı Metro and Marmaray were used as draught animals; as it appears, the nuchal perforations resulted from the yoke strikes. This is, by far, the first attempt of using the CT to analyse the nuchal perforations in cattle skulls unearthed from any archaeological site in Türkiye.

Key words: Nuchal perforation, cattle, paleopathology, Theodosius harbour, yenikapı

1. Introduction

While studies of ancient cattle bones mainly confirmed the use of these animals for meat, milk, or leather acquisition, information on their various secondary uses such as transport and labour has been relatively limited [1]. Although there is plenty of evidence for the use of cattle in labour and transport in, e.g., visual (paintings, sculptures, etc.) and written archaeological sources, understanding their labour effort at any archaeological sites has been limited due to the scarcity of zooarchaeological evidence. As a source of valuable products and labour force, cattle are common in archaeological faunal assemblages. Cattle bones have always been the focus of zooarchaeological studies, not only because of being important consumption waste materials, but also because of their potential pathologies that may have resulted from the animal use in labour [1]. Therefore, detailed analysis of such pathologies with advanced methods could provide more convincing evidence broadening our understanding of animal usage in ancient societies.

One of the pathologies that attract attention in the archaeological cattle is the perforations observed in the nape of these animals [1]. The round-shaped perforations in ancient cattle skulls have been observed for a long time [2,3], and such examples were identified at many excavation sites [1,2,4-8]. Possible etiological factors for these perforations in the nuchal region were discussed in different studies [2,4]. Although such factors as parasites, neoplastic tumours, or infections were considered apparent causes [2], congenital conditions or the effects of yoke strikes were suggested as more likely responsible [1,2,4,7].

Regular use of yokes on cattle horns or neck can cause depressions in the horn cores as well as deformations in the cervical or first thoracic vertebrae [9]. Perforations in the nuchal part of cattle skull can be identified as a possible consequence of an acute inflammation caused by increased vascularisation from the yoke-load [3]. However, the fact that these perforations were also observed in wild bovids

* Correspondence: onar@iuc.edu.tr

suggests that, rather than the pressure from the yoke, congenital factors can also be potentially responsible [8]. It is well known that *cribra cranii* or *cribra orbitalia* in human bone materials may result from persistent physiological stress. Therefore, this potential explanation of the nuchal perforations in cattle shall be taken into consideration [10].

Cattle skulls with rounded ante mortem perforations have been discovered from ancient times; for example, the Neolithic specimens from Spiennes, Hainaut, Belgium appeared to be the earliest examples [11]. Roman cattle skulls with ante mortem perforations came from such sites as Namur and northern Gaul, Belgium [1,2], Lincoln, Welton Road and Wellington Row, Great Britain [5,12,13], and Sagalossos, Türkiye [1]. Nuchal perforations from the medieval times were reported from a Merovingian well in Ghent, Belgium [2], York, England [3], or Haithabu and Lübeck, Germany [14,15]. Archaeological evidence of pathological changes attributed to the use of cattle as labour animals is very uncommon in Anatolia. Just a few cattle horns flattened on the rostral surface were reported from the Bronze Age site of Demircihöyük [16]. A similarly flattened cattle horn was found in the Hittite capital Boğazköy-Hattusa [17]. Extreme pathological changes in the first phalanges from Sagalossos were suggested as evidence of the use of draught cattle [1]. Apart from that, there are no more studies discussing possible use of cattle as draught animals or the use of yoke-loaded cattle at archaeological sites in Anatolia.

The site of Yenikapı (41°0'19.95"N 28°57'6.30"E) was one of the most important sea ports in the Byzantine capital Constantinople. The harbour, known as the ancient Theodosius harbour (*Portus Theodosiacus*), was built in the late 4th century, at the mouth of the Lycus stream (Bayrampaşa Deresi), which ran through Constantinople to the Sea of Marmara. The harbour was in active use until the 11th century, serving as an important hub for international trade and commerce. As part of the Marmaray tunnel project beneath the Bosphorus, salvage excavations were conducted at the site between 2004 and 2013. They covered an area of over 58.000 m² and unearthed extremely rich Byzantine assemblages including over 37 shipwrecks, amphorae, pottery, wooden and metal artefacts, as well as a large assemblage of animal remains comprising over 57 species [18-20].

In this study, we present computed tomography (CT) and osteological observations on an assemblage of 17 Byzantine cattle skulls from Yenikapı-Metro and Marmaray excavation showing the evidence of nuchal perforations.

Among the total of 65.535 (NISP = 65.535) skeletal remains unearthed between 2004 and 2013, 25.7% of the bones were identified as cattle. This seems to be one of

the most numerous bovine assemblages recovered from any of Byzantine period sites. The Lycus stream probably regularly carried butchery wastes, residues, and dead bovines from Constantinople, depositing them into the harbour area. Various activities at the harbour also resulted in the deposition of faunal remains on its bottom. Over seven centuries this led to the accumulation of extremely large number of complete animal bones, including cattle bones and skulls. Hence, the cattle remains from Yenikapı Metro and Marmaray excavations opened new possibilities of studying the human-cattle relationships, as well as the biological and cultural status of cattle in the Byzantine world. As the first attempt of CT on any Byzantine cattle, this study sheds new light on biocultural status of cattle as well as human-cattle relationships in the Byzantine world.

The skulls constituted 4.2% (NISP = 711) of total cattle remains from Yenikapı [21]; among them, 17 (2.4%) skulls exhibited nuchal perforations. Cut marks on many skulls as well as other post cranial skeletal elements indicated that most of the cattle remains were accumulated into the harbour as consumption waste from Constantinople [18, 19, 21-23]. With the help of CT, this study presents osteological observations of the nuchal perforations in the cattle skulls, as well as revealing new information on their possible causes and relationship with other cranial structures.

2. Materials and methods

A total of 17 excavated cattle skulls with the nuchal perforations were analysed in this study. Their age was determined based on the eruption status of permanent teeth and closure time of cranial sutures [24]. The eruption of permanent incisors (*dentis incisivi*) in cattle starts at the age of 1–1.5 years and is completed at 3.5–4 years [24]. The closure of the cranial sutures begins from the posterior part of the skull at 6 months, while in *ossa faciei* the closure can continue until 15–40 years of age. Age estimation of the specimens lacking permanent incisors was made according to the closure time of the cranial sutures [25]. Sex of the animals was determined according to biometric data and curvature and torsion classification proposed by Sykes and Symmons [26]. For this purpose, measurements of the basal circumference (BC), minimum basal diameter (BB), and the curvature and torsion of horns were used.

Although the samples were unearthed from chronometrically dated Byzantine layers, in order to reconfirm the dating of the skulls with nuchal perforations, four specimens selected according to the grid-square and spatial context of the excavated area were sent to the Oxford University Radiocarbon Unit (UK). The radiocarbon dating is presented in the results section (Table 1, Figure 1).

The condition of each skull was evaluated in the context of nuchal perforations. Anatomy of the perforations (i.e.

Table 1. Radiocarbon dates of Yenikapı cattle skulls.

Lab-code	Sample ID	Sample type	$\delta^{13}\text{C}$ (‰)	^{14}C age BP	%	calAD
OxA-30491	No.1	Skull No. 2, Cattle (<i>Bos taurus</i>)	-17.88	1177 ± 23	91.5%	772–896
					3.9%	928–941
OxA-30398	No.3	Skull No. 4, Cattle (<i>Bos taurus</i>)	-19.17	1138 ± 25	3.8%	777–791
					6.2%	806–842
					85.4%	861–981
OxA-30490	No.7	Skull No. 3, Cattle (<i>Bos taurus</i>)	-20.88	1109 ± 25	95.4	887–991
OxA-30399	No.14	Skull No. 5, Cattle (<i>Bos taurus</i>)	-17.98	1172 ± 27	85.2%	771–901
					10.2%	920–953

$\delta^{13}\text{C}$: Carbon 13 (a stable isotope of carbon); ^{14}C : Carbon 14 (a stable isotope of carbon); BP: Before Present; calAD: calibrated date.

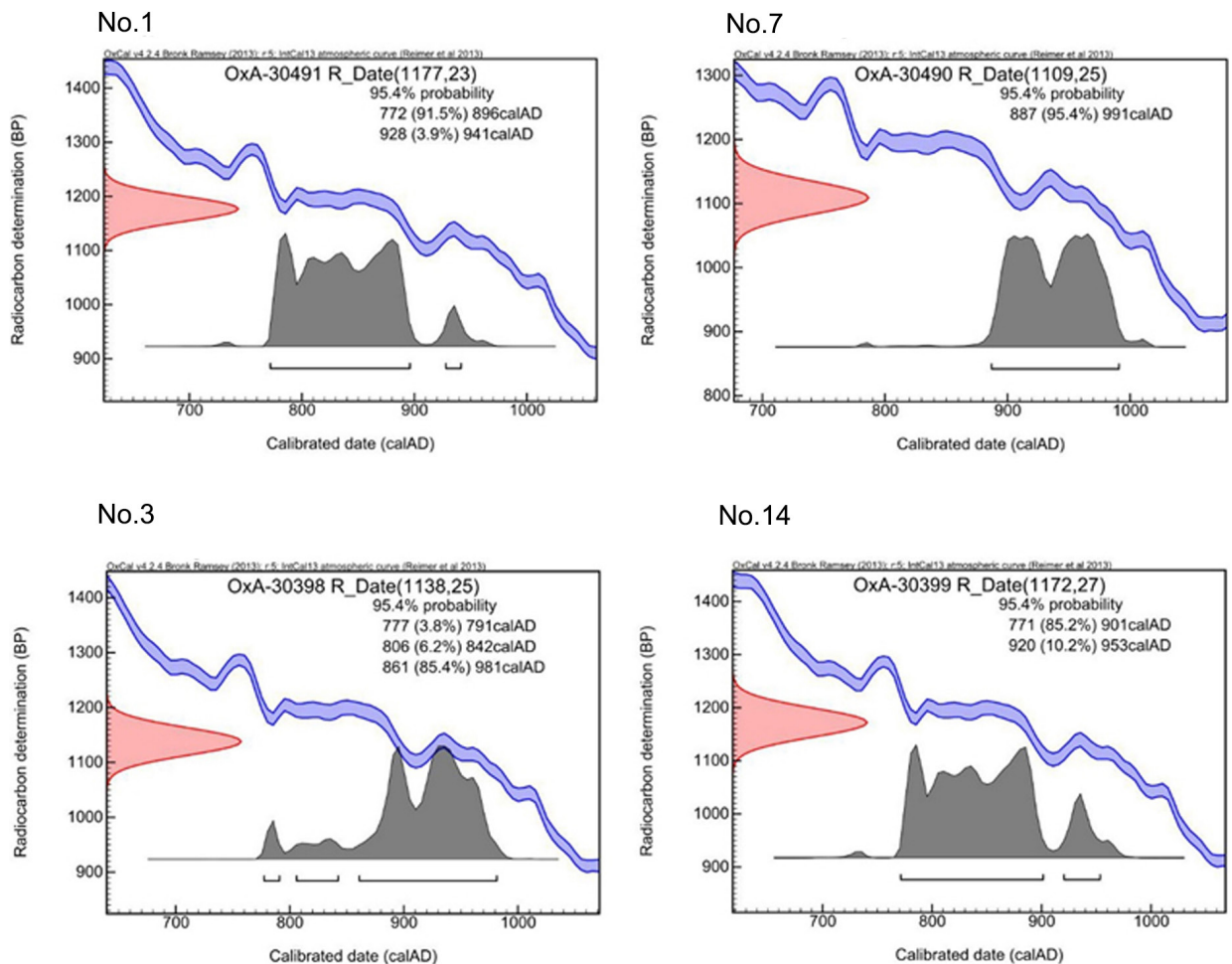


Figure 1. Calibrated date range (calAD) of the cattle skulls from Yenikapı Metro and Marmaray excavations. This plot shows how the radiocarbon measurements (^{14}C age BP) were calibrated. The left-hand axis shows radiocarbon concentration expressed in years “before present, 1950”, and the bottom axis shows calendar years (derived from IntCal13 calibration curve). The blue curve shows IntCal13 calibration curve derived from direct ^{14}C measurements (\pm one standard deviation), and the red curve on the left indicates the radiocarbon concentration in the sample. The grey histogram shows possible age of the sample (the higher the histogram, the more likely that age is).

single or multiple) and time of their occurrence (ante mortem or post mortem) was established. Morphometric measurements, mainly of two transverse planes (medio-lateral and dorso-basal diameter), were taken after detailed macrophotographing of the pathological defects of each skull.

Computed tomography (CT) scans were taken with Siemens Somatom Definition Flash CT, Multislice 256 scanner (Scm time 4–5 s, rotation time 0.5 s). One millimetre reformat images were evaluated by taking shots of 6-mm sections. This way, detailed relationships between the structural features of the nuchal perforations and their related cranial structures (especially *sinus frontalis*) were revealed. We were also able to determine whether the perforations were associated with superficial or cranial structures.

3. Results

Only one of 17 skulls was not fragmented (No.1) and the other included only the cranium with the nuchal region. Radiocarbon dating was performed for four skulls, and they were found to be 1100–1200 cal BP (Table 1, Figure 1).

No.1

This specimen consisted of a complete skull. Sex and age determination indicated that the skull belonged to a

7–10-year-old ox. The skull featured a single perforation in the nuchal region (Figure 2).

The perforation was located on the dorsal side, near *linea nuchae*, to the left of the midline. It was elliptical, with indented edges, and smooth walls towards inside. The perforation appeared when the animal was alive (ante mortem). Its medio-lateral diameter reached 3.51 mm, and dorso-basal one 2.76 mm. No computed tomography imaging of this skull was performed. The opening point of the perforation was osteologically examined under a stereoscopic microscope and it was found to be related with *sinus frontalis*.

No.2

This skull fragment only included a dorsal and posterior region and belonged to a 3–4-year-old cow (Figure 2). A prominent, single, and relatively elliptical hole was detected in its nuchal region. The perforation was located caudally and near *protuberantia intercornualis*, to the right of the median line and dorsally to *linea nuchae*. It had rounded edges and smooth inner walls, and was associated with the right *sinus frontalis* (Figure 3). Its medio-lateral diameter was 5.90 mm, and dorso-basal one 3.53 mm. Apart from this perforation, two other small perforations with indented edges were identified on *linea nuchae*, to the left of the median line. However, no



Figure 2. Nuchal view and nuchal perforations in Yenikapı cattle skulls (part 1).

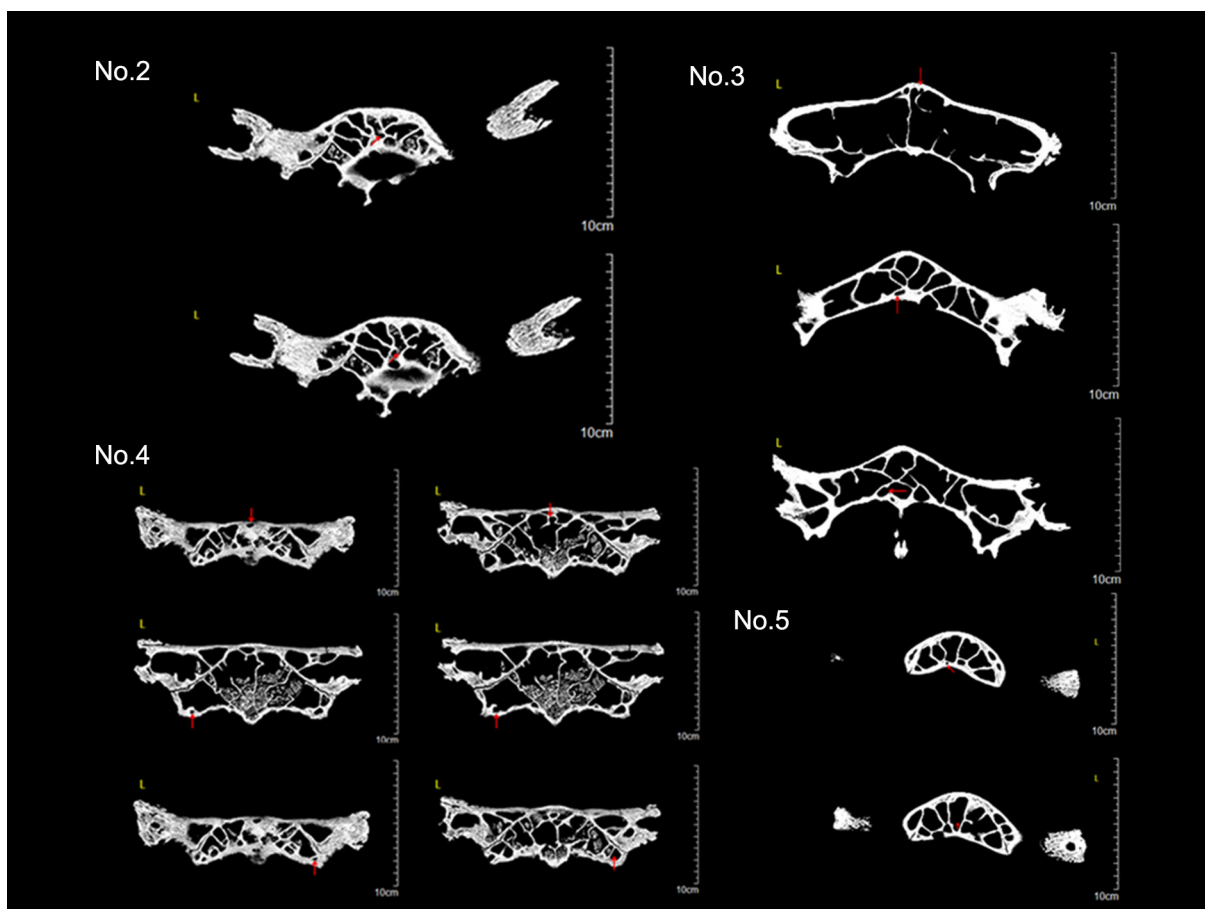


Figure 3. Computed tomography (CT) view of nuchal perforations in Yenikapı cattle skulls (L: left): No.2: upper image, the perforation; lower image, its connection to sinus frontalis (red arrows); No.3: upper image, the perforations; middle and lower images, their connection to sinus frontalis (red arrows); No.4: left images, the perforations; right images, their connection to sinus frontalis (red arrows); No.5: upper image, the perforation; lower image, its connection to sinus frontalis (red arrows).

connection between these small holes and *sinus frontalis* was established. No evidence of an inflammatory reaction was observed in the bone of the nuchal region where the perforations were located. The perforation with rounded edges was ante mortem and existed during the lifetime of the animal.

No.3

This skull fragment consisted of a dorsal and posterior part (Figure 2). It belonged to a cow that was 4–5 years old at death.

Two perforations, a round and an elliptical one, were observed in its nuchal region (Figure 2). The smaller round perforation was located caudally, near *protuberantia intercornualis*, to the right of the median line. Its edges were round and the inner wall was smooth. The medio-lateral diameter of the perforation was 5.92 mm and the dorso-basal diameter was 4.67 mm. The second perforation was elliptical in shape and was located above *linea nuchae*, to the left of the median line. It had a smooth inner wall and

relatively indented edges. Its medio-lateral diameter was 11.99 mm, and the dorso-basal one 6.54 mm. The edges indicated that both perforations appeared ante mortem.

CT imaging of the skull showed that the perforation was located caudally, near *protuberantia intercornualis* and to the right of the median line and was connected to the right *sinus frontalis* (Figure 3: above), while the elliptical perforation was located dorsally to *linea nuchae* and to the left of the median line was connected to the left *sinus frontalis* (Figure 3: middle and below).

No.4

The facial region of this skull was fractured (Figure 2). It belonged to a young cow that died at the age of 2 or 3 years.

The skull featured a well visible perforation on the median line, caudally and near *protuberantia intercornualis*, at the border of *os interparietale* and *os frontale* (Figure 2). The perforation was oval in shape with rounded edges and smooth walls towards the inside. The

medio-lateral diameter was 6.30 mm, and the dorso-basal one was 2.75 mm. Computed tomography of the opening point revealed that the perforation was connected to *sinus frontalis* (Figure 3).

Four other small perforations were also identified to the right and left of the median line, dorsally and near *linea nuchae* (Figure 2: arrows). The perforations were still at their primary stage of development. Two of them, located on the left side, had rounded edges and were connected to *sinus frontalis*. The opening points of the other two with rounded edges, located on the right side, were indeterminate.

In addition to these *ante mortem* perforations, a large *foramen mastoideum* was also detected to the left of *squama occipitalis* (Figure 2: No.4/B), and a post mortem fracture was noted close to the right horn, dorsally to *linea nuchae* (Figure 2: No.4/C). The perforation on the left was more regular in shape and with round edges (Figure 2: No.4/B), while the one on the right resembled a fracture (Figure 2: No.4/C). The perforation on the left was connected to the left *sinus frontalis* (Figure 3).

No.5

This skull fragment only consisted of a dorsal and posterior part (Figure 2). Sex and age determination indicated that it belonged to a cow that was 4–5 years old at death.

A total of three perforations were found in the nuchal region of this specimen. One large perforation was located to the right of the median line, along *linea nuchae*, a small perforation was found on the median line of *os interparietale*; and another small one to the right of *linea nuchae* (Figure 2). The medio-lateral diameter of the large perforation on the right, located along *linea nuchae*, was 9.65 mm, and its dorso-basal diameter was 5.01 mm. The other two perforations were too small to measure their diameters. These perforations, with their indented edges and smooth inner walls, were connected to the right *sinus frontalis* (Figure 3). Examination of the rounded edges suggested they appeared *ante mortem*, and existed during the lifetime of the animal.

No.6

This skull fragment consisted of a dorsal and posterior part (Figure 2). It belonged to a bull that was 5–7 years old at death.

A total of three perforations were observed in its nuchal region. One of them was located dorsally to *linea nuchae*, while the other two were located along the median line. The medio-lateral diameter of the perforation above *linea nuchae* was 6.41 mm, and its dorso-basal diameter was 4.77 mm. The diameters of the remaining two perforations were not measured due to their small size. All perforations had indented edges and smooth inner walls. The larger perforation was connected to the left *sinus frontalis*, while

the two smaller ones close to the median line opened into the right *sinus frontalis* (Figure 4). Examination of their indented edges indicated that the perforations appeared *ante mortem*.

No.7

This fragment consisted of a dorsal and posterior part of the skull (Figure 5). It belonged to an ox that died at 7 to 10 years of age.

This skull fragment exhibited two *ante mortem* perforations in the nuchal region. One of them was comparatively smaller, located caudally, near *protuberantia intercornualis*, to the right of the median line, and dorsally to *os interparietale* (Figure 5/No.7: B). The other was significantly bigger, located on *squama occipitalis*, just ventrally to *linea nuchae*, and to the left of the median line (Figure 5/ No.7: A). The edges and inner walls of these two indented perforations were smooth, and they were connected to the right *sinus frontalis* (Figure 4). Examination of the edges confirmed that both perforations were *ante mortem* and existed during the lifetime of the animal. Apart from these two *ante mortem* perforations, numerous post mortem changes were also detected in the nuchal region of the skull. They were located to the right of the median line (Figure 5/ No.7: C), and connected to the right *sinus frontalis* (Figure 4).

No.8

This fragment consisted of a dorsal and posterior part of the skull (Figure 5). It belonged to a cow that was 3–4 years old at death. A single, round hole was detected in the nuchal region of this skull. The perforation with indented edges and smooth inner walls was located caudally, near *protuberantia intercornualis*, on *os interparietale* of the median line. It showed a depression towards and was connected to the left *sinus frontalis* (Figure 4). Changes in the bones, apparently caused by an inflammatory reaction, were observed along the edges of the perforation. Detailed examination indicated the perforation to be *ante mortem*.

No.9

This fragment consisted of a dorsal and posterior part of the skull. It belonged to an ox aged 7–10 years at death. A depression was observed in *os frontale* of the specimen (Figure 5). A single elliptical perforation was found in its nuchal region, located caudally and near *protuberantia intercornualis*, on the median line, and on *os interparietale*. The edges of this perforation were indented, with smooth walls towards inside. It was connected to the left *sinus frontalis*, with a depression towards the sinus (Figure 4). No evidence of inflammatory reactions in the area of the perforation was observed. Its medio-lateral diameter was 4.00 mm, and the dorso-basal diameter was 1.39 mm.

No.10

This fragment consisted of a dorsal and posterior part of the skull (Figure 5). It belonged to a bull that was 3–4 years old at death.

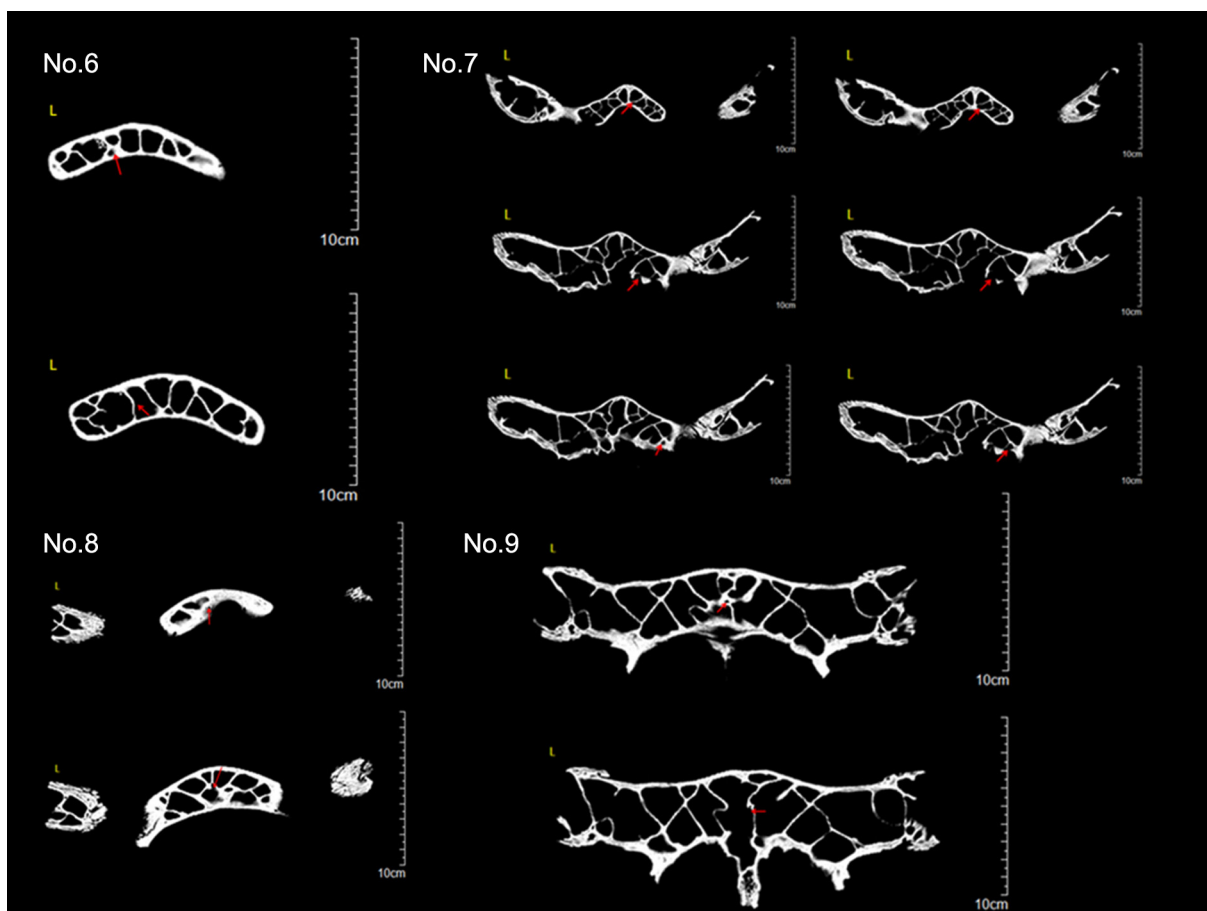


Figure 4. Computed tomography (CT) view of nuchal perforations in Yenikapı cattle skulls (continuation) (L: left): No.6: upper image, the perforations; lower image, their connection to sinus frontalis (red arrows); No.7: left images, the perforations; right images, their connection to sinus frontalis (red arrows); No.8: upper image, the perforation; lower image, its connection to sinus frontalis (red arrows); No.9: upper image, the perforation; lower image, its connection to sinus frontalis (red arrows).

A single, round-shaped perforation was noticed in its nuchal region, located caudally and near *protuberantia intercornualis*, to the right of the median line, and dorsally to *os interparietale*. It had indented edges, smooth walls towards the inside, and was connected to the right *sinus frontalis* (Figure 6). The medio-lateral diameter of this nuchal perforation was established at 3.81 mm, while the dorso-basal diameter was 3.57 mm.

No.11

This fragment consisted of a dorsal and posterior part of the skull (Figure 5). It belonged to a cow, about 5–7 years old at death.

A total of four perforations were observed in its nuchal region. One of them was located on the median line, caudally and near *protuberantia intercornualis* (Figure 5/ No.11: A). The other three were located linearly along *linea nuchae* (Figure 5/ No.11: B, C, D). All the perforations had indented edges and smooth inner walls and were connected to *sinus frontalis*. Their medio-lateral diameters were 6.96

mm (Figure 5/ No.11: A), 9.78 mm (Figure 5/ No.11: B), 6.60 mm (Figure 5/ No.11: C), and 1.81 mm (Figure 5/ No.11: D); while the dorso-basal diameters were 3.83 mm (Figure 5/No.11: A), 7.38 mm (Figure 5/No.11: B), 3.92 mm (Figure 5/No.11: C), and 1.15 mm (Figure 5/No.11: D). Examination of the rounded edges suggested that the perforations appeared ante mortem.

CT revealed that the perforation Yenikapı Met10083: B was connected to the right *sinus frontalis* (Figure 6: above and middle), while No.11: A, No.11: C, and No.11: D were connected to the left *sinus frontalis* (Figure 6: below).

No.12

This fragment consisted of a dorsal and posterior part of the skull (Figure 5). It belonged to a cow that was 5–7 years old at death.

A total of three elliptical perforations were observed in its nuchal region. Two of them were located to the right and left of the median line, along *linea nuchae*. The other one was comparatively small, located caudally and

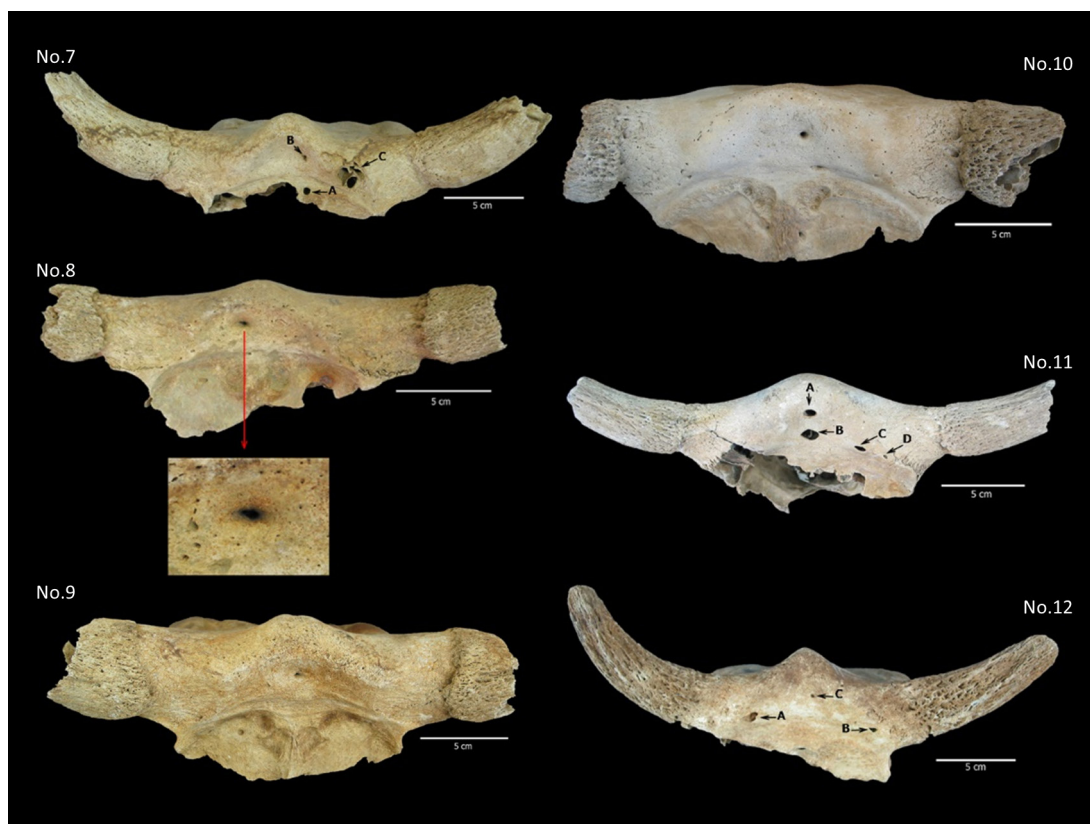


Figure 5. Nuchal view and nuchal perforations in Yenikapı cattle skulls (part 2).

near *protuberantia intercornualis*, on the median line, and on *os interparietale*. The medio-lateral diameter of the left perforation along *linea nuchae* (Figure 3/No.12: A) was 8.12 mm and its dorso-basal diameter was 4.84 mm. The medio-lateral diameter of the perforation on the right (Figure 5/ No.12: B) was 4.84 mm and the dorso-basal diameter was 2.72 mm. The medio-lateral diameter of the smaller perforation located just caudally to *protuberantia intercornualis* (Figure 5/No.12: C) was 1.63 mm, and its dorso-basal diameter was 1.68 mm. All three perforations had indented edges and smooth inner walls. The perforation to the left of *linea nuchae* was connected to the left *sinus frontalis* (No.12: A), and the other two (No.12: B and No.12: C) were connected to the right *sinus frontalis* (Figure 6). Examination of their indented edges confirmed that all three perforations were ante mortem.

No.13

This fragment consisted of the left half of a dorsal and posterior part of the skull. It belonged to a cow that was 4–5 years old at death (Figure 7).

In this skull, a nuchal perforation was visible on *squama occipitalis*, ventrally and near *linea nuchae*, to the left of the median line. The edges of this relatively rounded perforation were indented; it had smooth inner walls, and

was connected to the left *sinus frontalis*. Its medio-lateral diameter was 9.08 mm, and the dorso-basal diameter was 7.91 mm. Another smaller nuchal perforation was found on the median line, dorsally to *linea nuchae*. The perforation was still at its early stage of development, had rounded edges, and was connected to the left *sinus frontalis* (Figure 8). No evidence of an inflammatory reaction was observed in the bone where these nuchal perforations were located. Both perforations developed ante mortem.

No.14

This fragment consisted of a dorsal and posterior part of the skull. It belonged to a bull that was 5–7 years old at death (Figure 7). The skull had two elliptical perforations in its nuchal region. One of them was located dorsally to *linea nuchae*, on the median line, while the other was located on *squama occipitalis*, ventrally and near *linea nuchae*, to the right of the median line. Both perforations had indented edges, smooth inner walls, and were connected to *sinus frontalis* (Figure 8). Their medio-lateral diameters were 5.70 mm and 17.04 mm, and dorso-basal diameters 3.67 mm and 10.54 mm, respectively. The perforation on *squama occipitalis* presented the signs of an inflammatory reaction, particularly of osteomyelitis in the bone and outward folding of the edges. Examination

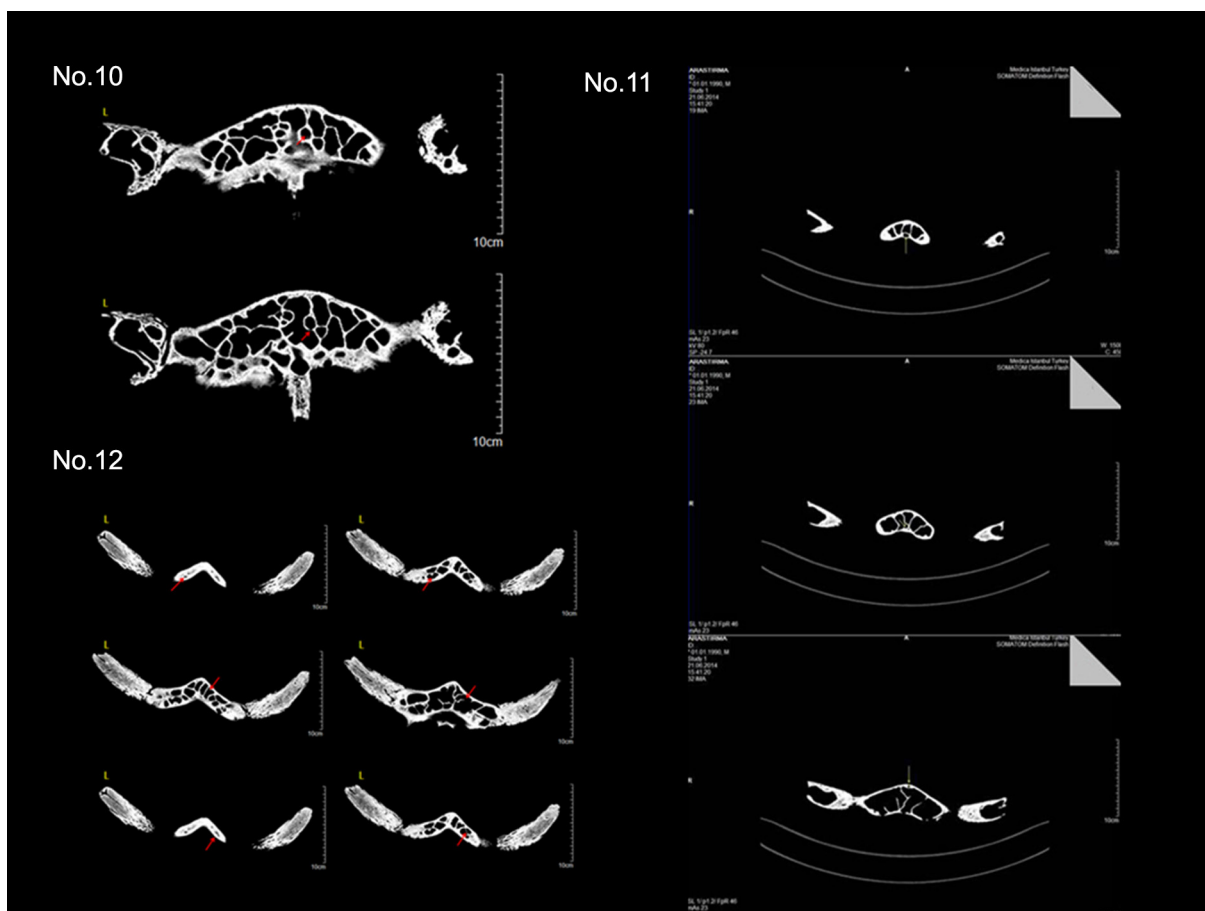


Figure 6. Computed tomography (CT) view of the nuchal perforations in Yenikapı cattle skulls (continuation) (L: left): No.10: upper image, the perforations; lower image, their connection to sinus frontalis (red arrows); No.11: upper and lower images, the perforations (arrows) ; middle image, their connection to sinus frontalis; No.12: left images, the perforations; right images, their connection to sinus frontalis (red arrows).

of the edges confirmed that both perforations developed ante mortem.

No.15

This skull fragment consisted of a dorsal and posterior part (Figure 7). It belonged to a cow that was 5–7 years old at death.

The skull had two round perforations in its nuchal region—one smaller and one larger. Both perforations were located caudally and near *protuberantia intercornualis*, on the median line of *os interparietale*. They had rounded edges and smooth inner walls. The large perforation was connected to the left *sinus frontalis*, while the smaller perforation on the right was close to the median line and connected to the right *sinus frontalis* (Figure 8). The large perforation on the left had a medio-lateral diameter of 5.28 mm and a dorso-basal diameter of 4.98 mm, while the relatively elliptical smaller perforation on the right had a medio-lateral diameter of 3.21 mm and a dorso-basal diameter of 2.00 mm. No evidence of an

inflammatory reaction was observed in the bone where the perforations were located. Close examination of their indented edges indicated that the perforations developed ante mortem.

No.16

This skull fragment consisted of a dorsal and posterior part. It belonged to a cow that was 5–7 years old at death (Figure 7). It had a single perforation in the nuchal region, located on the median line, caudally and near *protuberantia intercornualis*, in *os interparietale*, dorsally to *linea nuchae* (Figure 7). It had a triangular shape with rounded edges, smooth inner walls, and was connected to the right *sinus frontalis* (Figure 8). Its medio-lateral diameter was 14.55 mm, and dorso-basal diameter was 9.23 mm. Examination of the rounded edges suggested that the perforation appeared ante mortem.

No.17

This skull fragment consisted of a dorsal and posterior part (Figure 7). It probably belonged to a 5–7-year-old ox.



Figure 7. Nuchal view and nuchal perforations in Yenikapı cattle skulls (part 3).

In this skull, a single perforation was observed in the nuchal region. The perforation was located along *linea nuchae*, caudally and near *protuberantia intercornualis* on the median line (Figure 7). The oval-shaped perforation with indented edges had smooth inner walls and was connected to the left *sinus frontalis* (Figure 8). Its medio-lateral diameter was 19.62 mm and its dorso-basal diameter was 10.33 mm. Close examination of the indented edges suggested the perforation developed ante mortem.

Nuchal perforations are located in the nuchal region of the skull, as can be seen in the skulls above. The density of the anatomical location seems to be compatible with the placement of the yoke in this region.

4. Discussion

The Yenikapı cattle skulls with nuchal perforations provided significant information about the use of cattle in the Byzantine capital. Previously, the pathologies in the Byzantine draught cattle from Yenikapı Metro and Marmaray excavations were evaluated predominantly based on the appendicular skeleton; while the presence of nuchal perforations was only mentioned [27]. This study presents detailed evaluation of the nuchal perforations with the help of the advanced research methods. Some of these

skulls contained single, and some multiple perforations. A majority of them were ante mortem perforations located in the nuchal region, ventrally or dorsally to *os interparietale* and *linea nuchae*. In most cases, their shape ranged from elliptical to triangular, they had indented edges and smooth inner walls. The ante mortem perforations were connected to *sinus frontalis*, and were morphometrically different in size, depending on the individual.

CT images were taken in order to reveal the relationships between the nuchal perforations and cranial structures. The cranial structures (particularly *sinus frontalis*), to which the nuchal perforations were connected, were studied in detail. The nuchal perforations were connected to the left or right *sinus frontalis*. The use of CT allowed us to eliminate conditions such as neoplastic tumours, infections or parasitic invasion, as such pathologies were not observed in any of the investigated skulls.

There are very limited examples of pathologies attributed to cattle used as draught animals at archaeological sites in Anatolia. Among the very few of them, flattening of the rostral surface of several horns was reported from the Bronze Age site of Demircihöyük [16]. A similar flattened cattle horn was reported in Hittite capital city Boğazköy-Hattusa [17]. Most of the artefacts attributed to the archaeological

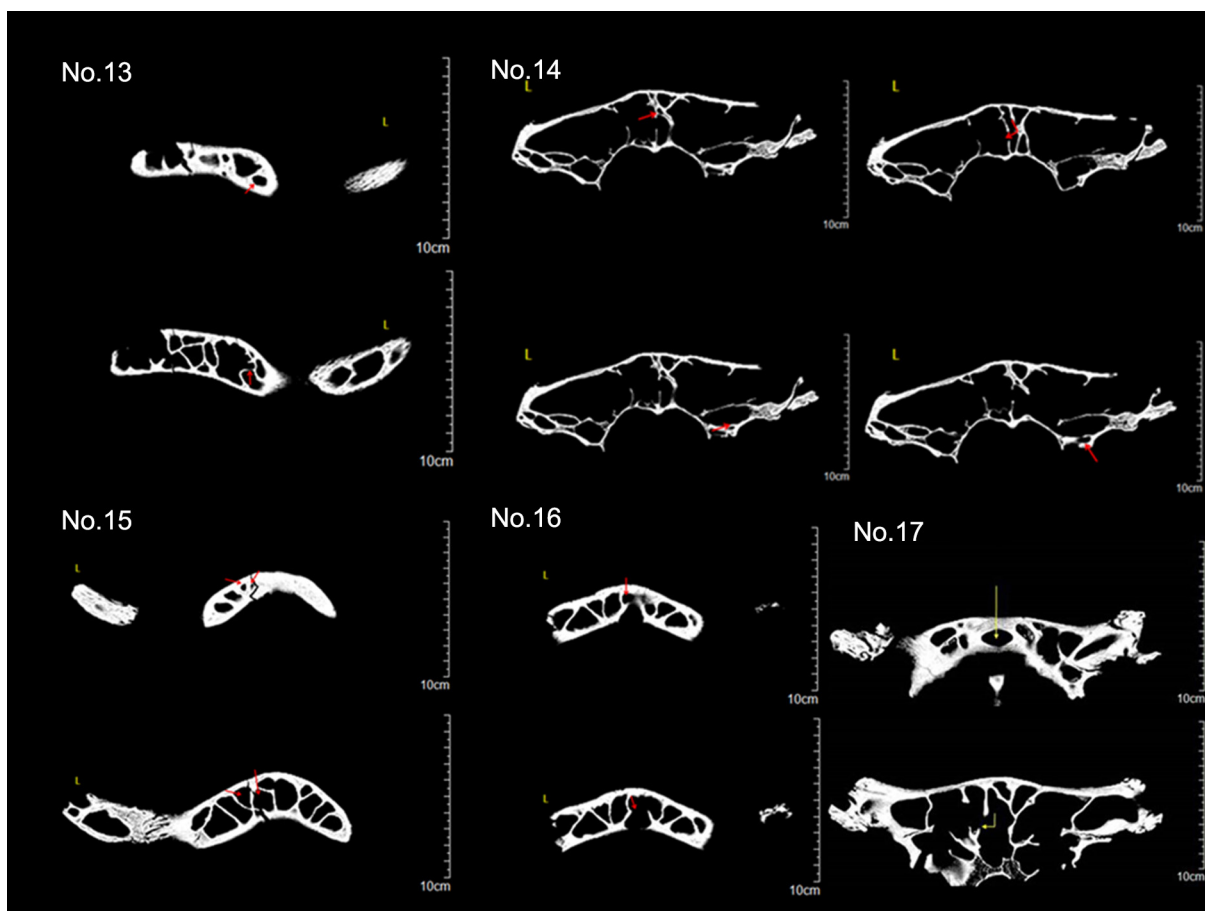


Figure 8. Computed tomography (CT) view of the nuchal perforations in Yenikapı cattle skulls (continuation) (L: left): No.13: upper image, the perforations; lower image, their connection to sinus frontalis (red arrows); No.14: left images, the perforations; right images, their connection to sinus frontalis (red arrows); No.15: upper image, the perforations; lower image, their connection to sinus frontalis (red arrows); No.16: upper image, the perforations; lower image, their connection to sinus frontalis (red arrows); No.17: upper image, the perforations; lower image, their connection to sinus frontalis (red arrows).

draught cattle in Anatolia comprised pathologies of the distal parts of limb skeleton. For example, autopodial bone fragments (especially of the first phalanx) were found in Sagalossos [1], but cases of cranial perforations were never mentioned in that study, perhaps due to the absence of nuchal perforations in the investigated skulls.

Contrary to the examples of pathological changes in the phalanx, this study emphasizes the presence of perforations in the nuchal region of the skulls to attest the use of yoke as well as the use of the cattle as draught animals in the Byzantine capital city. The fact that approximately 24% of the examined skulls belonged to oxen and 18% belonged to bulls, and there were some elderly individuals among them, also strengthened the hypothesis of these cattle as draught animals. Apart from the nuchal perforations in these Byzantine cattle skulls, the pathologies in the appendicular skeleton also support the hypothesis that some of the cattle from Yenikapı Metro and Marmaray

were used for labour [27]. The phalanx deformations indicated the use of the animals as draught ones [1].

As a significant share of the assemblage consisted of adult individuals, it could be assumed that congenital malformations, parasitic invasion, neoplastic tumours or infection could be possible etiological factors of the perforations [2]. However, we found that these pathological changes were triggered by yoke strikes and pressure. Rugged topography and rocky terrain of the region, in which the animals probably lived, were argued to be associated with phalanx pathologies [1]. Together with previously reported pathologies in the cattle phalanges from Yenikapı Metro and Marmaray [27], the presence of nuchal perforations can only be seen as a result of using these animals for labour in the urban areas of Constantinople.

It is argued that the relationship between the presence of the perforations and the age and sex of the animals can

be confidently established [7]. Considering the age range of the skulls, this study corroborated this assumption. The maximum age range of Yenikapı cattle with the skull perforation was generally below 7 years at death, and there were also individuals that died at 2–4 years (Table 2). The presence of perforations connected to *sinus frontalis* in these young individuals could also be due to the fact that *sinus frontalis* reached *squama occipitalis* in 2–3-year-old animals [6]. The animal age distribution for the cattle remains from Yenikapı Metro and Marmaray excavations demonstrated that the majority of skeletal remains belonged to anatomically adult (82.19%) and young adult individuals (6.13%). However, the growth of the 17 skulls with nuchal perforations did not follow this tendency (Figure 9). Relatively young animals used in labour were more susceptible to injuries. The constant and recurring pressure of a yoke on the nuchal region could easily produce the observed nuchal perforations, contrary to the elder individuals with more solid and fully developed cranial bony structures. Moreover, stress caused by laborious work might have a stronger effect on younger individuals than on elder and larger ones. The mortality of young draught cattle can be explained by too intensive work. On the other hand, it is possible that inhabitants of rich, mighty, and economically vivid Constantinople paid lower attention to the animal use optimization due to high bovine supply and high transportation needs.

Over 58% of the skulls with nuchal perforations belonged to cows (Table 2). We also found perforations, developed as a result of yoke pressure, in the skulls belonging to young individuals. CT did not reveal any pathological conditions caused by parasites, neoplastic tumours, or infection [2], which again suggested that the perforations developed as a result of yoke striking. Moreover, localisation of the perforations in the nuchal region differed from the perforations due to possible congenital factors in *os frontale* and *os parietale* [6]. The cattle sex identification for all Yenikapı Metro and Marmaray excavations artefacts was based on *os coxae* (10.6%), *processus cornualis* (62.7%), and cranium (26.7%). The sex profile proved that 45.0% of the bones belonged to bulls, 44.0% to cows, and only 11.0% to oxen. This contrasts the sex distribution of the 17 skulls with the nuchal perforations, which comprised 58.8% cows, 23.5% oxen, and 17.7% bulls. It is also possible that the animal sex was one of the main criteria for labour selection, given that cow were usually less aggressive, less dangerous, and suitable for narrow streets of Constantinople. On the other hand, they may be more susceptible to injuries and overloading, which can be the cause of the anatomical deformations.

Physiological stresses related to animal labour caused the emergence of pathological signs in their bones,

Table 2. Sex and age profile of the Yenikapı cattle with nuchal perforations in their skulls.

No	Skull ID	Sex	Growth	Age at death (years)
1	No.1	Ox	Adult	7–10
2	No.2	Cow	Young	3–4
3	No.3	Cow	Subadult	4–5
4	No.4	Cow	Juvenile	2–3
5	No.5	Cow	Subadult	4–5
6	No.6	Bull	Adult	5–7
7	No.7	Ox	Adult	7–10
8	No.8	Cow	Young	3–4
9	No.9	Ox	Adult	7–10
10	No.10	Bull	Young	3–4
11	No.11	Cow	Adult	5–7
12	No.12	Cow	Adult	5–7
13	No.13	Cow	Subadult	4–5
14	No.14	Bull	Adult	5–7
15	No.15	Cow	Adult	5–7
16	No.16	Cow	Adult	5–7
17	No.17	Ox	Adult	5–7

which are also noticeable after death [28]. Various degenerative bone and joint deformations observed in animals employed for pulling heavy loads for long periods were perceived as the environmental influence and a management factor in the use of animals [29]. The rugged topography and rocky terrain of the animal habitat were associated with phalanx pathologies [1]. However, the nuchal perforations in combination with previously reported extremity pathologies in the Byzantine cattle from Yenikapı [27] can only possibly be explained by their use for heavy work in the urban life of Constantinople. Brothwell et al. [2] studied perforations in the nuchal region in archaeological domestic cattle skulls from Lincoln and Bruges, and concluded that both single and multiple cranial perforations were congenital or resulted from yoking practices. Sana [30] also observed similar pathological changes in Neolithic cattle skulls from La Draga site and argued that the phenomenon cannot be a result of neoplasms, infections, osteomyelitis, or nutritional problems. Hence, if we exclude parasitic infections, the most apparent explanation of the nuchal perforations in the Byzantine cattle from Yenikapı appears to be the result of yoke strikes.

Post mortem pathologies can be found in individuals of all ages. Although the presence of yoke-striking in young animals of both sexes was mainly attributed to high

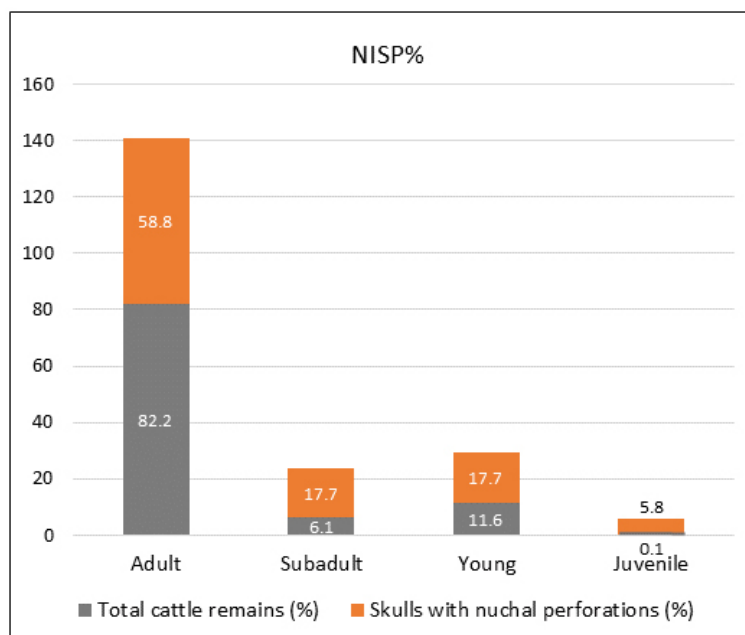


Figure 9. Age profile of the cattle remains from Yenikapı Metro and Marmaray excavations, a comparison between total remains and 17 skulls with nuchal perforations

proportion of extreme labour in total cattle population [2], there seems to be no relationships between the age and sex and the presence of cranial perforations [7]. The proportion of cattle skulls with nuchal perforations in our study is relatively low when compared to the total cattle remains from the site. The nuchal perforations in young individuals, generally found more often in adults and elderly individuals, is probably due to the fact that from an early age the young cattle in Constantinople were accustomed to yoke-loaded works along the adult animals.

Other potential causes, such as massive parasitosis, congenital malformations, acute inflammation, extensive injury, or tumours seem to be excluded [30-33]. The phenomenon of nuchal perforations in cattle skulls was widely debated in the literature. Possible parasitic cause of the pathology was stressed by Bartosiewicz [34]. An earlier questionable hypothesis on the role of cheese maggot (*Piophilus sp.*) in development of the nuchal perforation was replaced by a suggestion that similar bone changes may possibly result from a massive and chronic invasion with ox warble (*Hypoderma bovis*) [34]. The lack of labour factor in the development of nuchal perforations was hypothesized by Manaseryan et al. [8] in bovine skeletal remains from Armenia. Unfortunately, only direct evidence of parasites (eggs, remains of mites and insects) may prove the parasitic pathogenesis theory. The parasites rarely invade the nuchal region of cattle skull. Usually pathological changes due to parasitosis can be found in bones surrounding the nasal or oral cavity, as these two cavities are the gates of the

parasite invasion. Similarly, bacterial or viral infections usually begin at the same sites [35-38]. In all three cases, the pathological process must be accompanied by the live animal response. Acute inflammations usually do not leave any signs on bone tissue and they are limited to soft tissues. The time from the infection to animal death, slaughter, or healing is too short to allow for any bone growth [39]. Any extensive injury must cause a strong and acute response of the animal organism, can lead to rapid death, or change the animal health status and its condition resulting in the lack of ability to work. Chronic, severe, pathological processes, such as neoplastic tumours, can cause massive bone changes [38,39], but they are usually accompanied by osteolysis or new bone formation. Since the nuchal perforations in Yenikapı cattle skulls developed with regular margins and without any signs of vascular reactions or any new bone growth, we should exclude the idea of a parasitic infection as their etiological factor.

Brothwell et al. [2] pointed out that chronic recurrent pressure in the nuchal region of the cattle head may cause similar perforations. We, therefore, suggest that this is the most possible explanation for the phenomenon observed in the studied sample. The bone changes in the cattle skulls seem to be the outcomes of a slow process (chronic subclinical inflammation), consisting of the pressure forces acting on the bones of the nuchal region—a common picture for recurrent yoke use in draught animals. The draught cattle skull was a direct object of physical forces acting in living animals. The labour was the factor causing

physiological stress that brought about changes in bone morphology. Proved and common use of draught cattle in Roman Empire [1] supports the hypothesis of similar practices in the Byzantine capital city.

5. Conclusions

The study described single or multiple perforations of round, indented to elliptical shape and with regular edges and smooth inner walls, located in the nuchal region of the Byzantine cattle skulls. Computed tomography revealed that the nuchal perforations, regardless of the animal age at death, were connected to the right or left *sinus frontalis*, depending on their localisation. Excluding potential causes such as massive parasitosis, congenital malformation, acute inflammation, extensive injury or tumours, a recurrent and slow compression in the nuchal region provided by a yoke-strike appears to be the most probable cause of these perforations. CT allowed for detailed anatomical observations of the nuchal perforations and their associated features within the skull. This helped us conclude that the examined Byzantine cattle were used as yoke-loaded draught animals. Considering previously reported labour-related pathological changes in postcranial skeletal elements [27], as well as the absence

of any pathological changes such as malign or benign neoplasms, it seems that the nuchal perforations in these skulls stand as a direct archaeological evidence for the use of yoke-loaded cattle in Constantinople. Moreover, the study proved CT imaging as a noninvasive, nondestructive, and highly effective method of zooarchaeological research, allowing for detailed description of inner structures of animal skulls.

Acknowledgments

We are deeply grateful to Oya Kahvecioğlu and Gülsün Pazvant for their kind permission regarding this issue. This work was supported by the Scientific Research Projects Coordination Unit of İstanbul University-Cerrahpaşa (project number: 20727). The APC was supported by statutory research and development activity funds assigned to Wrocław University of Environmental and Life Sciences.

Conflict of interest

The authors declare that they have no known competing financial interests or personal relationships that could have appeared to influence the work reported in this paper.

References

- De Cupere B, Lentacker A, Van Neer W, Waelkens M, Verslype L. Osteological evidence for the draught exploitation of cattle: First applications of a new methodology. *International Journal of Osteoarchaeology* 2000; 10 (4): 254-267. [https://doi.org/10.1002/1099-1212\(200007/08\)10:4<254::AID-OA528>3.0.CO;2-%23](https://doi.org/10.1002/1099-1212(200007/08)10:4<254::AID-OA528>3.0.CO;2-%23)
- Brothwell D, Dobney K, Ervynck A. On the causes of perforations in archaeological domestic cattle skulls. *International Journal of Osteoarchaeology* 1996; 6 (5): 471-487. [https://doi.org/10.1002/\(SICI\)1099-1212\(199612\)6:5<471::AID-OA300>3.0.CO;2-8](https://doi.org/10.1002/(SICI)1099-1212(199612)6:5<471::AID-OA300>3.0.CO;2-8)
- Ryder ML. The animal remains from Petergate, York, 1957-58. *Yorkshire Archaeological Journal* 1970; 42: 418-428.
- Baxter IL. Occipital perforations in a Late Neolithic probable aurochs (*Bos primigenius bojanus*) cranium from Letchworth, Hertfordshire, UK. *International Journal of Osteoarchaeology* 2002; 12 (2): 142-143. <https://doi.org/10.1002/oa.591>
- Carrott J, Dobney K, Hall A, Issitt M, Jaques D et al. Assessment of biological remains from excavations at Welton Road, Brough, N. Humberside (site code: 1994.294). *Reports from the Environmental Archaeology Unit* 1994; 94.
- Fabiš M, Thomas R. Not just cattle: Cranial perforations revisited. *International Journal of Osteoarchaeology* 2011; 21 (3): 347-350. <https://doi.org/10.1002/oa.1133>
- Llado E, Gaitero L, Pumarola M, Saña M. Perforations in archaeological Neolithic cattle skulls: A new methodological approximation for their study and explanation. *Veterinarija Ir Zootehnika* 2008; 43 (65): 58-61.
- Manaseryan NH, Dobney K, Ervynck A. On the causes of perforations in archaeological domestic cattle skulls: New evidence. *International Journal of Osteoarchaeology* 1999; 9 (1): 74-75. [https://doi.org/10.1002/\(SICI\)1099-1212\(199901/02\)9:1<74::AID-OA463>3.0.CO;2-1](https://doi.org/10.1002/(SICI)1099-1212(199901/02)9:1<74::AID-OA463>3.0.CO;2-1)
- Benecke N. *Der Mensch und seine Haustiere: Die Geschichte einer Jahrtausendalten Beziehung*. 1st ed. Stuttgart, Germany: Theiss in Wissenschaftliche Buchgesellschaft; 1994.
- Gworys B, Rosińczuk-Tonderys J, Chrószcz A, Janeczek M, Dwojak A et al. Assessment of late Neolithic pastoralist's life conditions from the Wrocław-Jagodno site (SW Poland) on the basis of physiological stress markers. *Journal of Archaeological Science* 2013; 40 (6): 2621-2630. <https://doi.org/10.1016/j.jas.2013.02.002>
- Gautier A, Biondi S. A forgotten faunal collection from the prehistoric flint mines at Spiennes (province of Hainaut, Belgium). *Helinium* 1993; 33 (1): 80-98.
- Carrott J, Dobney K, Hall A, Issitt M, Jaques D et al. Assessment of biological remains from excavations in Wellington Row, York (site code 1988-9.24). *Reports from the Environmental Archaeology Unit* 1995; 95.

13. Dobney K, Jaques D, Irving B. *Of Butchers & Breeds: Report on Vertebrate Remains from Various Sites in the City of Lincoln*. 1st ed. Lincoln, UK: City of Lincoln Archaeology Unit; 1996.
14. Johansson E, Schietzel K. Untersuchungen an Skelettresten von Rindern aus Haithabu: Ausgrabung 1966-1969. Bericht über die Ausgrabungen in Haithabu Neumünster 1982; 17: 1-86.
15. Pyrozok A, Reichstein H. Tierknochenfunde aus hochmittelalterlichen Siedlungsablagernungen in Lubeck (Grabung Dr.-Julius-Leberstrasse 58). Lübecker Schriften Zur Archäologie Und Kulturgeschichte 1991; 21: 183-202.
16. Rauh H. Knochenfunde von Säugetieren aus dem Demircihüyük (Nordwestanatolien). PhD Thesis, University of München, München, Germany, 1981.
17. von den Driesch A, Boessneck J. Reste von Haus- und Jagdtieren aus der Unterstadt von Boğazköy-Hattuša: Grabungen 1958—1977. In: Bittel K (editor). *Boğazköy-Hattusa. Ergebnisse der Ausgrabungen*. 1st ed. Berlin, Germany: Gebr. Mann: Germany; 1981. pp.1-71.
18. Onar V, Pazvant G, Alpak H, Ince NG, Armutak A et al. Animal skeletal remains of the Theodosius Harbor: General overview. *Turkish Journal of Veterinary and Animal Sciences* 2013; 37 (1): 81-85. <https://doi.org/10.3906/vet-1111-7>
19. Onar V, Pazvant G, Armutak A, Alpak H, Karamut I et al. Preliminary report on the animal remains uncovered at Yenikapı Metro and Marmaray Excavations. 1st Symposium on Marmaray-Metro Salvage Excavations, Istanbul, Türkiye; 2008: 223-231.
20. Kocabaş U. The Yenikapı Byzantine-era shipwrecks, Istanbul, Türkiye: a preliminary report and inventory of the 27 wrecks studied by Istanbul University. *International Journal of Nautical Archaeology* 2015; 44 (1): 5-38. <https://doi.org/10.1111/1095-9270.12084>
21. Onar V. Animals in food consumption during the Byzantine period in light of the Yenikapı metro and Marmaray excavations, Istanbul. In *Multidisciplinary Approaches to Food and Foodways in the Medieval Eastern Mediterranean*, 1st ed.; Waksman S.Y. Ed.; MOM Éditions: Lyon, France, 2020. pp. 331-342.
22. Onar V, Alpak H, Pazvant G, Armutak A, Ince NG et al. A bridge from Byzantium to modern day Istanbul: An overview of animal skeleton remains found during metro and marmaray excavations. *Acta Veterinaria Eurasia* 2013; 39 (1): 1-8.
23. Onar V, Pazvant G, Armutak A, Alpak H. Investigation of the animal skeletal remains unearthed from the Yenikapı Metro and Marmaray excavations, (Unpublished Project Report TÜBİTAK Project No. 107O518). TÜBİTAK, 2010.
24. Grigson C. Sex and age determination of some bones and teeth of domestic cattle: a review of the literature. In: Wilson B, Grigson C, Payne S (editors). *Ageing and Sexing Animal Bones from Archaeological Sites*. 1st ed. Oxford, UK: BAR Publishing; 1982. pp.7-23.
25. Zietzschmann O. Das Skelettsystem. Der passive Bewegungsapparat. In: Ellenberger W, Baum H (editors). *Handbuch der vergleichenden Anatomie der Haustiere*. 1st ed. Berlin Heidelberg, Germany: Springer; 1943. pp. 6-193.
26. Sykes N, Symmons R. Sexing cattle horn-cores: Problems and progress. *International Journal of Osteoarchaeology* 2007; 17 (5): 514-523. <https://doi.org/10.1002/oa.891>
27. Onar V, Kahvecioğlu KO, Kostov D, Armutak A, Pazvant G et al. Osteological evidences of Byzantine draught cattle from Theodosius Harbour at Yenikapı, Istanbul. *Mediterranean Archaeology & Archaeometry*. 2015; 15 (2): 71-80.
28. Bartosiewicz L, Van Neer W, Lentacker A. *Draught Cattle: Their Osteological Identification and History*; Musée Royal de l'Afrique Centrale: Tervuren, Tervuren, Belgium, 1997.
29. Baker J, Brothwell D. *Animal Diseases in Archaeology*. 1st ed. London, UK: Academic Press; 1980.
30. Cole G, Waldron T. Cribra orbitalia: Dissecting an ill-defined phenomenon. *International Journal of Osteoarchaeology* 2019; 29 (4): 613-621. <https://doi.org/10.1002/oa.2757>
31. Toldt C. Über Welcker's cribra orbitalia. *Mitteilungen der Anthropologischen Gesellschaft Wien* 1886; 16: 20-24.
32. Angel JK. Porotic hyperostosis, anaemias, malaras, and marshes in the prehistoric eastern Mediterranean. *Science* 1966; 153 (3737): 760-763. DOI: 10.1126/science.153.3737.760
33. Gowland RL, Western AG. Morbidity in the marshes: Using spatial epidemiology to investigate skeletal evidence for malaria in Anglo-Saxon England (AD 410-1050). *American Journal of Biological Anthropology* 2012; 147 (2): 301-311. DOI: 10.1002/ajpa.21648
34. Bartosiewicz L. *Shuffling Nags, Lame Ducks – The Archaeology of Animal Disease*; 1st ed. Oxford and Oakville, UK: Oxbow Books; 2013.
35. Yogeshpriya S, Saravanan M, Jayalakshmi K, Veeraselvam M, Krishnakumar S et al.. Nasal schistosomiasis in cattle – A clinical case report. *International Journal of Environmental Science and Technology* 2017; 6 (2): 1071-1074.
36. Ahab WA, Kumar S, Lone HA, Beghum R. Clinical management of bovine actinomycosis (lumpy jaw) in cattle: A case report. *International Journal of Engineering Science and Computing* 2020; 10 (3): 24868-24870.
37. Hasan, S.; Khan, N.I.; Tarannum, F. Oral tuberculosis. *Guident* 2012, 5, 59-63.
38. Constable P, Hinchcliff KW, Done S, Gruenberg W. *Veterinary Medicine - A Textbook of the Diseases of Cattle, Horses, Sheep, Pigs and Goats*; 11th ed. Nottingham, UK: Saunders Ltd; 2016.
39. Grant M. *Jubb, Kennedy and Palmer's Pathology of Domestic Animals*; 6th ed. Nottingham, UK: Saunders Ltd.; 2015.